

Superior Mesenteric Artery Syndrome: A Forgotten Entity

Smadar Bauer^{1*}, Rebekah Karplus MD¹, Viktor Belsky MD² and Howard Amital MD MHA¹

¹Department of Medicine B and ²Imaging Institute, Sheba Medical Center, Tel Hashomer, affiliated with Sackler Faculty of Medicine, Tel Aviv University, Ramat Aviv, Israel

KEY WORDS: superior mesenteric artery (SMA) syndrome, nausea, weight loss, bariatric surgery, vomiting

IMAJ 2013; 15: 189–191

The superior mesenteric artery syndrome is an uncommon condition where the third part of the duodenum is compressed between the superior mesenteric artery and the abdominal aorta due to a subnormal angle between these vessels, causing partial duodenal obstruction. The presumed etiology is a loss of intraabdominal adipose tissue, leading to narrowing of the aorto-superior mesenteric artery angle. The SMA syndrome is characterized by nausea, vomiting and epigastric pain, together with substantial weight loss that further aggravates the condition. SMA syndrome is a controversial diagnosis both because the symptoms are not always correlated with anatomic findings and because weight gain – the logical treatment – does not always resolve the symptoms. In this report we describe a patient with the characteristic symptoms of SMA syndrome at presentation and the expected anatomic findings on imaging studies. This patient showed partial improvement after returning to her baseline weight.

PATIENT DESCRIPTION

A 23 year old woman was admitted due to abdominal pain, nausea and vomiting from which she had been suffering for 6 months, accompanied by a 7 kg weight loss (from an initial weight of 48 kg and body

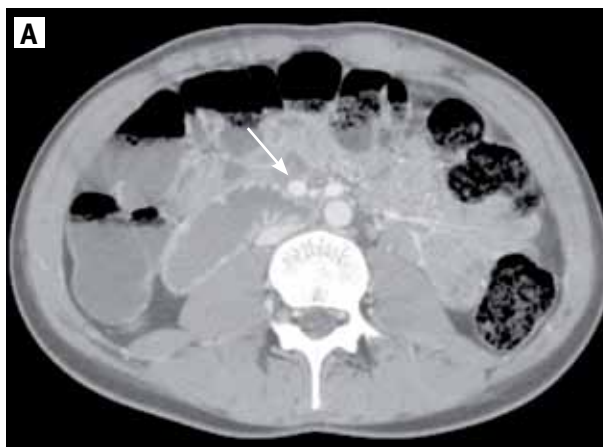mass index of 20). The patient had no previous medical history other than migraine headaches. Prior to the current illness she was engaged in regular physical activity and enjoyed overall good health. During a trip to France the patient experienced a sudden onset of nausea, accompanied by severe abdominal pain. These symptoms were not accompanied by fever, dyspnea or diarrhea. Since then she had frequent recurrences of abdominal pain. She reported difficulty eating, accompanied by a feeling of early satiety and postprandial nausea. She also frequently experienced nausea and vomiting before meals. After 2 months the nature of her abdominal pain changed to a pressing tenderness located mostly over the upper and middle abdomen and radiating to the back.

Two weeks before admission to our institute the patient began to experience a feeling of numbness in her right leg and hand. Examination at a pain clinic did not yield any cause for this sensation. In addition, psychiatric evaluation determined that the patient was in a state of depression but without suicidal ideation; there was no previous eating disorder.

Treatment with mirtazapine was recommended but not commenced. The patient was transferred to our department for further evaluation.

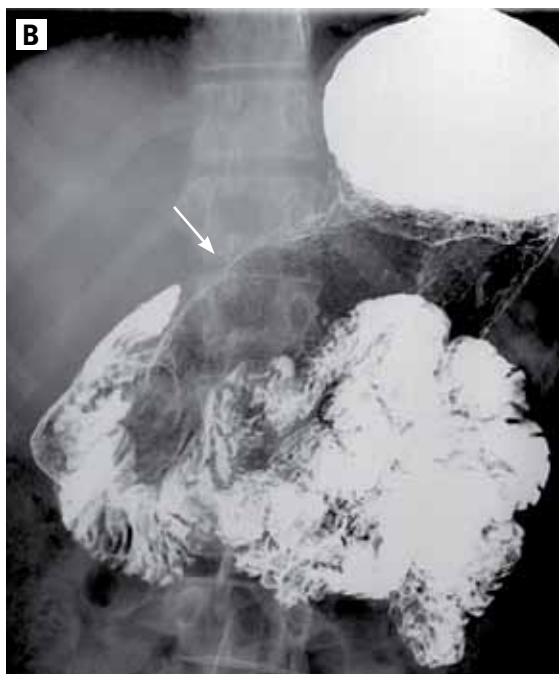
Upon admission she was hemodynamically stable. Physical examination revealed slight tenderness over her left upper and middle abdomen without abdominal distension or palpable masses. There was no sign of organomegaly or peritoneal irritation. The rest of the physical examination was normal.

Laboratory results did not show abnormal findings. A test for the presence of *Helicobacter pylori* in the stomach and a stool culture were negative. There were no gross pathological findings on gastroscopy and no significant mucosal changes on small intestinal biopsy. Abdominal computed tomography scan demonstrated an angle of 16° between the abdominal aorta and the origin of the superior mesenteric artery. The distance measured between these vessels was 4.5 mm. CT scan also demonstrated a slight expansion of the stomach and proximal duodenum [Figure A], as well as narrowing of the duodenum lumen between



[A] CT scan showing a distended proximal duodenum containing liquid contents. External pressure on the duodenum by blood vessels is demonstrated (white arrow)

*In partial fulfillment of the requirements for the MD degree



[B] Fluoroscopy showing a slightly distended duodenum, with clear signs of pressure on the third part of the duodenum (white arrow)

the aorta and the superior mesenteric artery. Abdominal ultrasound showed an angle of 10.5° between these vessels. Fluoroscopy [Figure B] revealed an elongated area under minor pressure in the third part of the duodenum. Normal flow velocity was measured in the whole abdominal vasculature. These findings were suggestive of superior mesenteric artery syndrome.

The patient was discharged with the recommendation of conservative treatment comprising a rich diet, avoidance of excessive physical activity, pain management, and mood stabilizers. At a follow-up visit 3 months after her admission to our department, she had more than regained her baseline weight (follow-up weight 50 kg) and her symptoms had partially ameliorated, with elimination of nausea and vomiting but persistence of epigastric pain.

COMMENT

The SMA syndrome is a rare medical condition characterized by abdominal pain, vomiting and weight loss resulting from the compression of the third part of

the duodenum by the SMA. The initial cause may be any of various medical and psychiatric conditions resulting in rapid weight loss and dwindling of the fat pad separating the SMA from the duodenum, thus causing narrowing of the aorto-mesenteric angle and leading to SMA pressure on the third part of the duodenum as it crosses between the aorta and the SMA, resulting in partial or complete obstruction [1]. The syndrome is then self-perpetuated by the vomiting and weight loss it causes, regardless of the initiating factor. Treatment is either conservative or surgical. Conservative treatment consists of initial fluid resuscitation and electrolyte correction, followed by a rich diet, post-obstruction enteric feeding, or total parenteral nutrition in an effort to increase the patient's weight. Surgical options may include duodenal mobilization, duodenojejunostomy, gastrojejunostomy, or vascular surgery [2].

The young age of affected patients and the non-specific symptoms on presentation, as in our case, frequently lead to a delayed diagnosis. In several other previously reported cases of the SMA syndrome, the syndrome typically manifested

with persistent vomiting, epigastric pain and gastroesophageal reflux. Our patient exhibited the first two symptoms.

As mentioned above, the main anatomic feature of SMA syndrome is narrowing of the aorto-mesenteric angle. The normal range for the aorto-mesenteric angle ranges from 38° to 65° . The angle in our case was 10.5° as measured using abdominal ultrasound, and the aorto-mesenteric distance was reduced from a normal 10–28 mm to 5.7 mm. Apart from the mentioned compression of the third part of the duodenum, narrowing of the aorto-mesenteric angle may also result in compression of the left renal vein that also runs between the aorta and the SMA; this was not demonstrated in our patient [3]. This narrowing of the aorto-mesenteric angle in SMA syndrome is attributed to loss of intraabdominal adipose tissue. In healthy individuals, a fat pad displaces the SMA anteriorly away from the aorta, thus widening the space between the SMA and the aorta and preventing compression of the duodenum.

Weight loss, which is accompanied by reduction in the amount of intraabdominal fat, narrows the aorto-mesenteric angle, leading to the aforementioned functional obstruction. Not surprisingly, the literature on SMA syndrome suggests rapid weight loss as a precipitating factor for the onset of the disease [4]. Patients hence fall into two broad categories based on the initial trigger for their disease: those who developed SMA syndrome following surgery and those in whom the initiating factor for disease onset was severe weight loss. This first group includes patients who underwent bariatric surgery, esophagectomy, abdominal trauma, and surgical correction of spinal deformities [4]. The second group comprises wasting and catabolic conditions such as AIDS, malabsorption, cancer, cerebral palsy, severe burns, as well as drug abuse and eating disorders such as anorexia nervosa [1,4,5]. Females and young adults (18–35 years) are prone to develop SMA syndrome, although it can occur in both males and females of any age. This age and

gender distribution may reflect the dominance of eating disorders as a predisposing factor for developing SMA syndrome. In our patient there was no recent history of surgery or clear evidence for weight loss preceding the onset of symptoms. A possible explanation is that our patient reported an initial episode of symptoms including abdominal pain, nausea and vomiting that could be due to gastroenteritis rather than duodenal compression. For this patient, who had a slender build by nature, a few days of acute illness may

have been sufficient to cause rapid weight loss and trigger the development of the self-perpetuating SMA syndrome.

Corresponding author:

Dr. H. Amital
 Head of Dept. of Medicine B, Sheba Medical Center, Tel Hashomer 52621, Israel
Phone: (972-3) 530-2661, **Fax:** (972-9) 530-4796
email: hamital@netvision.net.il, howard.amital@sheba.health.gov.il

References

1. Merrett ND, Wilson RB, Cosman P, Biankin AV. Superior mesenteric artery syndrome: diagnosis and treatment strategies. *J Gastrointest Surg* 2009; 13: 287-92.

2. Sapkas G, O'Brien JP. Vascular compression of the duodenum (cast syndrome) associated with the treatment of spinal deformities. A report of six cases. *Arch Orthop Trauma Surg* 1981; 98: 7-11.

3. Neri S, Signorelli SS, Mondati E, et al. Ultrasound imaging in diagnosis of superior mesenteric artery syndrome. *J Intern Med* 2005; 257: 346-51.

4. Smith BM, Zyromski NJ, Purtill MA. Superior mesenteric artery syndrome: an underrecognized entity in the trauma population. *J Trauma* 2008; 64: 827-30.

5. Adson DE, Mitchell JE, Trenkner SW. The superior mesenteric artery syndrome and acute gastric dilatation in eating disorders: a report of two cases and a review of the literature. *Int J Eat Disord* 1997; 21: 103-14.

Capsule

Epigenetic silencing of retinoblastoma gene regulates pathologic differentiation of myeloid cells in cancer

Two major populations of myeloid-derived suppressor cells (MDSCs), monocytic MDSCs (M-MDSCs) and polymorphonuclear MDSCs (PMN-MDSCs) regulate immune responses in cancer and other pathologic conditions. Under physiologic conditions, Ly6ChiLy6G- inflammatory monocytes, which are the normal counterpart of M-MDSCs, differentiate into macrophages and dendritic cells. PMN-MDSCs are the predominant group of MDSCs that accumulates in cancer. Youn et al. show that a large proportion of M-MDSCs in tumor-bearing

mice acquired phenotypic, morphological and functional features of PMN-MDSCs. Acquisition of this phenotype, but not the functional attributes of PMN-MDSCs, was mediated by transcriptional silencing of the retinoblastoma gene through epigenetic modifications mediated by histone deacetylase 2 (HDAC-2). These data demonstrate a new regulatory mechanism of myeloid cells in cancer.

Nature Immunol 2013; 14: 211
 Eitan Israeli

Capsule

New insights into doxorubicin cellular effects

Doxorubicin (Dox) is a chemotherapeutic drug with efficacy in many cancers, yet after 40 years of clinical use there are lingering mysteries about its mechanism of action. The prevailing hypothesis is that Dox forms a complex with topoisomerase II, a DNA-unwinding enzyme, and this leads to DNA strand breaks that induce cell cycle arrest. Although much evidence supports this model, not all data are consistent with it. New insights into Dox's cellular effects could help optimize its antitumor activity, reduce its adverse side effects, and/or help oncologists identify which patients are most likely to respond to the drug. Denard et al. propose

that the membrane-associated transcription factor CREB3L1 plays a key role in Dox's antitumor activity. In cultured cells, Dox increased synthesis of the lipid ceramide, which in turn caused proteolytic activation of CREB3L1 and its entry into the nucleus, where it increased transcription of cell cycle-inhibitory genes. When CREB3L1 levels were experimentally suppressed, cancer cells became resistant to Dox. These results suggest that CREB3L1 may be a biomarker of Dox-responsive cancer cells or even a druggable target itself.

eLife 2012; 1: e00090
 Eitan Israeli

“Bills travel through the mail at twice the speed of checks”

Anonymous

“Flatter me, and I may not believe you. Criticize me, and I may not like you. Ignore me, and I may not forgive you. Encourage me, and I will not forget you”

William Arthur Ward (1921-1994), American college administrator and one of the most quoted writers of inspirational maxims