

# Smartphone Expedites Parasitology Diagnosis

Arnon Blum MD, Saleh Nazzal MD and Avi Peretz PhD

Department of Medicine and Microbiology Laboratory, Poriya Medical Center, Tiberias, affiliated with Bar Ilan University Faculty of Medicine in the Galilee, Safed, Israel

**KEY WORDS:** smartphones, diagnosis, *Ascaris lumbricoides*

IMAJ 2014; 16: 463

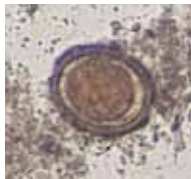
A 49 year old woman was admitted with left-sided flank pain and high grade fever of 3 days duration. She reported that 24 hours prior to admission, while she was urinating, she passed a “worm” measuring 10 cm long. She took a picture of the worm [Figure 1] and was admitted to our internal medicine department. On examination we found hundreds of fertilized eggs [Figure 2]. Our parasitology laboratory diagnosed the worm as *Ascaris lumbricoides*. She was

treated with albendazole 400 mg/day for 3 days and was discharged.

The interesting point in this case is that the patient took a picture of the *Ascaris* with her own smartphone and brought it



**Figure 1.**  
The “worm”



**Figure 2.**  
A fertilized egg

with her to the hospital, and the laboratory team documented the fertilized eggs with their personal smartphone. This way an expedited diagnosis was made – thanks to the smartphone [1]. We are aware of the new emerging technology and its usefulness in making an early diagnosis [2].

## Correspondence:

**Dr. A. Blum**

Dept. of Medicine, Poriya Medical Center, Tiberias 15208, Israel

**email:** Ablum@poria.health.gov.il

## References

1. Anderson C, Henner T, Burkey J. Tablet computers in support of rural and frontier clinical practice. *Int J Med Inform* 2013; 82 (11): 1046-58.
2. Dexheimer JW, Borycki EM. Use of mobile devices in the emergency department. *Stud Health Technol Inform* 2013; 192: 1086.