

Isolated Pulmonary Arteriovenous Fistulas with Massive Right-To-Left Shunt as a Rare Cause of Cryptogenic Stroke in a Young Woman

Juraj Dubrava MD PhD¹, Ivan Vulev MD PhD³ and Denis Richter MD²

Departments of ¹Cardiology and ²Neurology, Ss. Cyril and Methodius Hospital, University Hospital Bratislava, Slovakia

³Department of Diagnostic and Interventional Radiology, National Institute of Cardiovascular Diseases, Bratislava, Slovakia

KEY WORDS: pulmonary arteriovenous fistula (PAVF), stroke, transcatheter closure, computed tomography, digital subtraction angiography

IMAJ 2014; 16: 320–321

Pulmonary arteriovenous fistula causing stroke due to paradoxical brain embolism is very rare. Up to 80% of patients with PAVF have Rendu-Osler-Weber disease (hereditary hemorrhagic teleangiectasia). We report the case of a 35 year old woman with a history of migraine presenting with a severe ischemic stroke. She was diagnosed as having two large PAVFs with a massive right-to-left shunt via pulmonary veins to the left atrium. PAVFs were not associated with ROW disease. PAVF in cryptogenic stroke should not be overlooked. All cases of unexplained ischemic stroke should raise the suspicion of a PAVF.

PATIENT DESCRIPTION

A 35 year old woman who suffered a stroke presented with severe right-sided hemiparesis and global aphasia. Apart from frequent migraine headaches her past history was unremarkable. There were no clinical features of Rendu-Osler-Weber disease. The patient was a smoker. She was not on any medication except for oral contraceptive pills. Duplex ultrasonography of extracranial neck arteries, electrocardiography, and a

chest radiograph were all normal. An initial computed tomography scan was negative for a cerebral infarct or bleed. CT angiography revealed proximal occlusion of the left middle cerebral artery. Intravenous thrombolysis with t-PA was administered within 3 hours of the onset of symptoms. Repeated CT demonstrated a large ischemic infarct (83 x 51 x 78 mm) within the left middle cerebral artery area. Transesophageal contrast echocardiography showed massive right-to-left shunt via pulmonary veins to the left atrium. Patent foramen ovale was excluded. The rest of the TEE study was normal. Duplex ultrasonography of the lower extremities and of inferior vena cava did not show venous thrombosis. Thrombophilia workup (including tests for factor V Leiden mutation, prothrombin gene mutation, methylenetetrahydrofolate reductase gene mutation, antithrombin III, protein C, protein S and antiphospholipid antibodies) was negative.

CT angiography showed two PAVFs in the left lower pulmonary lobe above the diaphragm. The larger fistula was 30 x 20 mm in size, with the feeder and drainer blood vessel in the left inferior lobe S8. The nidus was supplied from the anterior segmental branch of the left lower lobar pulmonary artery [Figure A]. The smaller fistula, 17 x 12 mm in size, was detected in the dorsobasal subpleural region of the left inferior lobe S10. This nidus was supplied from the posterior segmental branch of the same artery. The PAVFs connected the segmental branches of the left lower

pulmonary artery and vein. Also found in the right lower pulmonary lobe were two small PAVFs, 5 and 8 mm in diameter. All pulmonary veins drained normally into the left atrium. Digital subtraction angiography confirmed the presence of two massive right-to-left shunts in the left lower pulmonary lobe [Figure B] and three tiny right-sided communications. Stroke workup was negative for any other cause. We concluded that isolated PAVFs were responsible for the ischemic stroke.

Both left-sided PAVFs were successfully treated by the endovascular approach, with percutaneous embolization using 19 mechanically detachable coils [Figure C]. Post-coil delivery angiogram revealed complete super-selective occlusion of both fistulas. Eighteen months after the stroke, moderate right-sided hemiparesis and severe expressive aphasia persisted.

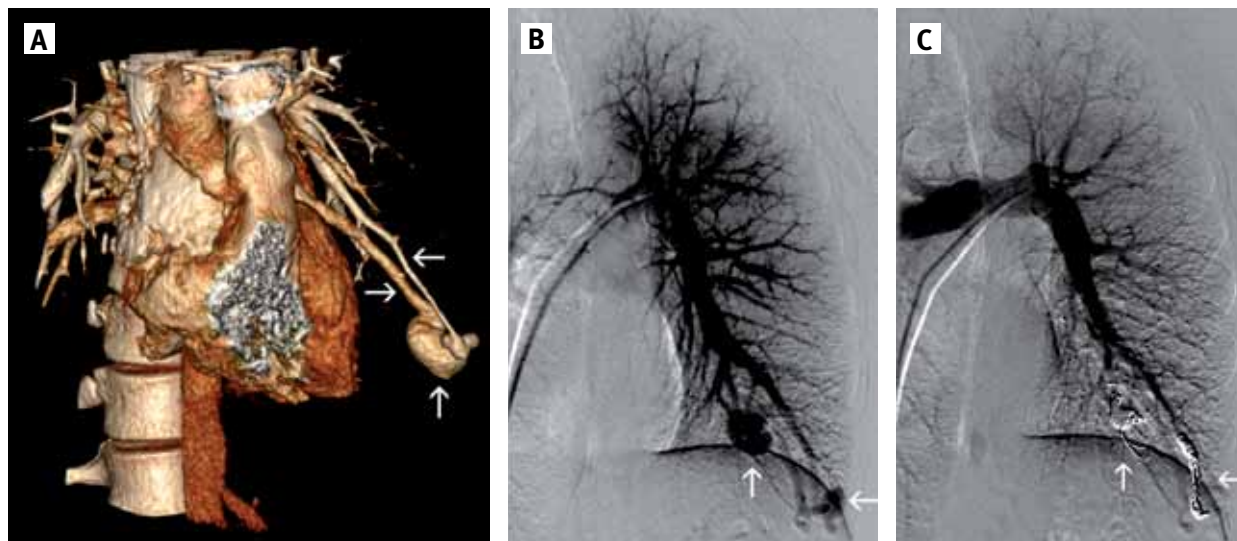
COMMENT

PAVFs are congenital or acquired, occurring at a frequency of 0.02% [1]. More than 80% are congenital, and 45%–80% are associated with Rendu-Osler-Weber disease [2]. Their prevalence in ROW disease is 15–22% [3,4]. On the other hand, isolated PAVFs (i.e., without ROW disease) are uncommon.

There are only a few case reports of cryptogenic stroke from isolated PAVFs in the literature [2]. Kimura et al. [5] diagnosed PAVFs in 4 of 747 (0.5%) ischemic stroke patients without ROW disease [5]. All the patients were middle-aged women. PAVFs were always single and usually

PAVF = pulmonary arteriovenous fistula
ROW = Rendu-Osler-Weber

TEE = transesophageal echocardiography



[A] Chest 3D-CT angiography. A pulmonary arteriovenous fistula 30 x 20 mm in size (↑) with the feeder (←) and drainer (→) blood vessel in the left inferior lobe S8

[B] Digital subtraction angiography revealing two pulmonary arteriovenous fistulas above the diaphragm (↑, ←)

[C] Post-coil delivery angiogram showing complete superselective occlusion of both fistulas (↑, ←)

located in the right lower lobe. Their size was 2–7 mm [5]. The brain infarcts were more frequently located in the areas supplied from the vertebrobasilar arteries.

PAVFs are usually asymptomatic. Generally, when the right-to-left shunt is 20–30% or greater, dyspnea, cyanosis, and polycythemia may occur [1]. They can lead to hemoptysis and hemothorax. Central nervous system complications included migraine (25–43%), transient ischemic attack (37%), stroke (18%), abscess (9%), and seizure (8%) [2,4]. Paradoxical embolization occurs particularly if a feeder artery diameter is over 3 mm [1]. Cerebral infarction can occur as the result of any of the following mechanisms: deep vein thrombosis in the inferior limb or pelvis, thrombus formation in a fistula, or thromboembolism caused by polycythemia [1]. Since no other causes were found, embolism via PAVFs was believed responsible for ischemic stroke in our patient. Neither the first nor the third mechanism was found, suggesting that the second mechanism was the likely culprit. Similar to our case, the source of embolism is rarely found [1].

PAVFs are usually not suspected from the physical examination or seen on the chest radiograph. Transcranial Doppler

with contrast medium detects non-specifically right-to-left shunt, as in patent foramen ovale or PAVFs. The gold standard for detecting right-to-left shunts is contrast-enhanced TEE. If TEE demonstrates a right-to-left shunt via pulmonary veins, PAVFs are suspected. Digital subtraction angiography, the most sensitive test, or spiral CT angiography has been used to confirm the diagnosis.

In contrast to published case reports, our case differs in several aspects. Multiple PAVFs were not associated with ROW disease. They were located in both lower lobes, and the brain infarct was in the middle cerebral artery territory. The patient had no history of previous stroke, transient ischemic attack, pulmonary embolism, or deep vein thrombosis.

Most PAVFs can be safely and effectively occluded using various coils for small to moderate sized fistulas or devices such as Amplatzer vascular plugs for larger fistulas [2,5]. Rarely is surgical resection or lobectomy required. Recurrence of stroke post-occlusion has not been reported [2].

Isolated PAVFs in cryptogenic stroke should not be overlooked [5]. The isolated PAVFs must be excluded, even if a patent foramen ovale is present. PAVFs can

simulate residual defect after transcatheter closure of patent foramen ovale. All cases of unexplained ischemic stroke should raise the suspicion of a PAVE.

Corresponding author:

Dr. J. Dubrava

Dept. of Cardiology, Ss. Cyril and Methodius Hospital, Antolska 11, 851 07 Bratislava, Slovakia
Phone: (421-2) 6867-2319
Fax: (421-2) 6867-2029
email: dubrava.kv@gmail.com

References

1. Nakamura H, Miwa K, Haruki T, Adachi Y, Fujioka S, Taniguchi Y. Pulmonary arteriovenous fistula with cerebral infarction successfully treated by video-assisted thoracic surgery. *Ann Thorac Cardiovasc Surg* 2008; 14: 35-7.
2. Husain Z, Vuppali M, Hussain K, et al. An isolated fistula between the right pulmonary artery and the right pulmonary vein: an unusual cause of stroke in a young female. *Cardiol J* 2011; 18: 73-6.
3. Cohen R, Cabanes L, Burckel C, Duboc D, Touzé E. Pulmonary arteriovenous fistulae thrombosis responsible for recurrent stroke. *J Neurol Neurosurg Psychiatry* 2006; 77: 707-8.
4. Maher CO, Piepgras DG, Brown RD Jr, Friedman JA, Pollock BE. Cerebrovascular manifestations in 321 cases of hereditary hemorrhagic telangiectasia. *Stroke* 2001; 32: 877-82.
5. Kimura K, Minematsu K, Nakajima M. Isolated pulmonary arteriovenous fistula without Rendu-Osler-Weber disease as a cause of cryptogenic stroke. *J Neurol Neurosurg Psychiatry* 2004; 75: 311-13.