

Hantavirus Pulmonary Syndrome in an Israeli man Returning from South America

Ori Galante MD¹, Ella Abramovich MD², Anat Nevo-Shor MD² and Yaniv Almog MD¹

¹Medical Intensive Care Unit and ²Department of Medicine, Soroka University Medical Center and Faculty of Health Sciences, Ben-Gurion University of the Negev, Beer Sheva, Israel

KEY WORDS: hantavirus pulmonary syndrome (HPS), acute interstitial pneumonitis (AIP)
IMAJ 2014; 16: 259–261

Hantavirus is a member of the Bunyaviridae family [1]. This genus of viruses, reservoirs by rodents, is responsible for two clinical syndromes: hemorrhagic fever with renal syndrome and hantavirus pulmonary syndrome. Hemorrhagic fever with renal syndrome, first described in 1950 and named Hantaan (after a river in South Korea), is mostly seen in Europe and Asia [2]. The second syndrome, HPS, also called hantavirus cardiopulmonary syndrome, was first recognized as a clinically relevant pathogen in humans in southwestern United States in 1993 [1]. Since then until the year 2011 there have been 587 reported cases of HPS, with a case-fatality rate of 36% [3]. To the best of our knowledge, this is the first report of HPS in Israel.

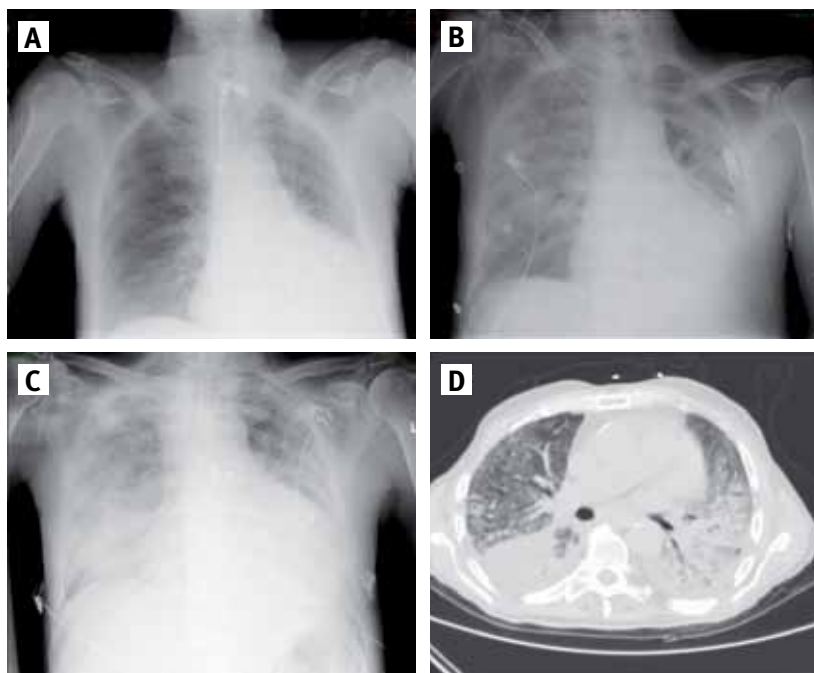
PATIENT DESCRIPTION

A 76 year old man was admitted to the medical intensive care unit with hypoxemic respiratory failure. The patient was generally healthy and took no medications other than rivaroxaban for secondary prevention of thromboembolic disease due to paroxysmal atrial fibrillation. A month before his admission to the unit he returned from a 2 month trip in Argentine. A week after his return he was admitted to our facility with fever, myalgia and abdominal pain.

Complete blood count, renal function and liver enzymes were within normal range. Blood cultures, serology for rickettsial disease, Brucella and Q fever were negative; chest X-ray was normal. Doxycycline was initiated with no clinical improvement. His fever persisted, and weakness and shortness of breath gradually worsened to the point that he required non-invasive ventilation. After 10 days doxycycline was substituted by intravenous levofloxacin. At this point (the 10th hospital day), his blood pressure was 128/75 mmHg, heart rate 85 beats/min, temperature 38.2°C, and oxygen saturation 80% while breathing ambient air. His

physical examination was unrevealing; blood tests revealed hemoglobin 9.4 g/dl with no leukocytosis, mild lymphopenia (0.67×10^3 , normal range $0.9-5.2 \times 10^3$) and mild thrombocytopenia (116×10^3 , normal range $130-400 \times 10^3$). He had mildly elevated creatinine (1.35 mg/dl), normal liver enzyme level, and elevated lactate dehydrogenase (1100 U/L, normal 230–480 U/L). Chest X-ray showed a small interstitial infiltrate in the right lower lobe [Figure]. Blood cultures, serology for *Mycoplasma pneumoniae*, Chlamydia species, Epstein-Barr virus, cytomegalovirus, hepatitis B and C viruses, human immu-

Chest X-ray and computed tomography during the patient’s hospital stay. **[A]** Day of admission, showing mild non-specific interstitial infiltrates. **[B]** 2 weeks later. **[C]** X-ray and **[D]** chest CT 4 weeks after admission, showing bilateral pleural effusion and diffuse bilateral interstitial alveolar infiltrates



HPS = hantavirus pulmonary syndrome

odeficiency virus, and Legionella urine antigen were all negative. Chest and abdomen computed tomography revealed right pulmonary infiltrate with mildly enlarged mediastinal lymph nodes. Positron emission tomography scan showed increased uptake in the right lung and mediastinal lymph nodes. Bone marrow biopsy was normal. Thoracoscopic mediastinal lymph node biopsy revealed focal follicular hyperplasia with no evidence of tumor. Due to aggravating hypoxemic respiratory failure, the patient was intubated and transferred to the medical intensive care unit (hospital day 15). While in the unit he was hemodynamically stable with severe hypoxemia and PaO₂ to FIO₂ ratio of 70. Chest X-ray and CT showed large bilateral pulmonary infiltrates [Figure], and echocardiography revealed normal biventricular function. A trial of high dose corticosteroids (1 g solumedrol/day for 3 days) followed by a maintenance dose of 120 mg/day was initiated. Despite steroid therapy no improvement was observed.

To better define the nature of the pulmonary process and to facilitate the decision to add cyclophosphamide to the regimen, an open lung biopsy was performed. The biopsy revealed organized proliferative interstitial infiltrates, alveoli covered with type 2 pneumocysts with several nuclear atypia, and some degree of diffuse alveolar damage. No hyaline membrane or granulomas were seen, and silver stain for *Pneumocystis jiroveci* was negative. In view of his recent trip to South America, serology for hantavirus was obtained. Initially only IgM was detected, but later IgG seroconversion was documented for hantavirus Sin Nombre – a known cause of HPS.

After 2 weeks of mechanical ventilation the patient was successfully extubated but remained hypoxemic, requiring intermittent non-invasive positive pressure ventilation and 100% oxygen delivered by face mask. Chest X-ray and CT showed no remission and a fibrosing pattern appeared. After almost 2 months since his initial presentation, during which the patient failed to improve, a trial of low dose cyclophosphamide was initiated.

Despite this aggressive therapeutic effort his disease continued to progress and he gradually deteriorated. He insisted that he not be reintubated and eventually expired 3 months after admission.

COMMENT

The case under discussion illustrates two important points. To the best of our knowledge, this is the first description of HPS in Israel; it should be included in the differential diagnosis of interstitial pneumonia when occurring in patients with a history of potential exposure to the virus. The second point is the possible association between HPS and acute interstitial pneumonitis.

HPS is a rodent-borne disease caused by at least 10 different strains of the hantavirus genus [2]. The transmission of hantavirus from rodents to humans is by aerosolized viral particles inhaled from rodent excrement or bodily fluids. Human-to-human transmission has not been documented. Infection with hantavirus usually appears in rural areas, the natural habitat of the virus's host. The Sin Nombre virus, which is the cause of most cases of HPS in the USA, is hosted by the deer mouse found throughout western and central U.S. Other hantaviruses like the New York hantavirus and Black Creek hantavirus are found in the northeastern and southeastern United States respectively, but cases of hantavirus have been found also in Canada, Argentina, Bolivia, Brazil, Chile, Panama, Paraguay and Uruguay [3]. Infection is characterized by an incubation period of 2 to 3 weeks, usually followed by a non-specific short prodrome of low grade fever, myalgia, chills, gastrointestinal symptoms and non-productive cough [3]. In the first series described by Duchin et al. in 1993 [1], the most common symptoms at admission were fever, myalgia, headache, cough and vomiting. This prodromal phase is usually followed by rapid-onset non-cardiogenic pulmonary edema developing over the subsequent 2–8 days, requiring intubation and mechanical ventilation in up to 84% of cases. The most prominent laboratory

findings are thrombocytopenia, elevated lactate dehydrogenase, and leukocytosis. The mortality rate can reach 50%. Serology is the main method of diagnosis and several assays are now available; in the U.S. enzyme-linked immunoassay is mainly used. A western blot assay that uses antigen and isotype-specific conjugates for IgM-IgG differentiation has also been developed and is being used in Israel with equal performance [3]. On autopsy the lungs are edematous with large pleural effusion, mild-to-moderate interstitial pneumonitis with variable degree of congestion, edema, mononuclear cell infiltrates and fibrin. Respiratory epithelium is intact. Among patients who die after a longer than average course, the histopathologic changes are more characteristic of exudative and proliferative stages of diffuse alveolar damage [3]. Similar non-specific findings were observed in the lung biopsy of our patient. Although ribavirin was initially promising as an effective antiviral therapy in hemorrhagic fever with renal syndrome, its benefit in the treatment of patients with HPS has not been established. The management of patients with hantavirus infection is therefore primarily supportive [4].

Acute interstitial pneumonitis, an idiopathic form of acute lung injury first described by Hamman and Rich in 1935 [5], is a rapidly progressive disease that leads frequently to respiratory failure and mechanical ventilation and has a very poor prognosis. The histopathologic appearance in AIP is of diffuse alveolar damage characterized by three phases: acute exudative, organizing proliferative, and fibrotic. This pattern is similar to that described in HPS. It should be emphasized that AIP cannot be distinguished from adult respiratory distress syndrome on the basis of histology alone. This distinction can be ascertained only when there is no identifiable etiology in cases of AIP after thorough clinical evaluation [5]. As briefly described, there are many similarities between these two syndromes. We suggest that AIP is an entity encompassing a wide variety of etiologies that are often

AIP = acute interstitial pneumonitis

unidentified, some of which may be viral in origin – such as HPS.

In summary, although most likely acquired in South America, this is probably the first case of hantavirus diagnosed in Israel. HPS and AIP have many similarities and HPS should be included in the differential diagnosis of patients presenting clinical features suggestive of AIP.

Corresponding author:

Dr. O. Galante
 Medical Intensive Care Unit, Soroka University
 Medical Center, P.O. Box 151, Beer Sheva 84101, Israel
Phone: (972-8) 640-0640
Fax: (972-8) 640-0166
email: galante1@zahav.net.il, Ori.galante@gmail.com

References

1. Duchin JS, Koster FT, Peters CJ, et al. Hantavirus pulmonary syndrome: a clinical description of 17 patients with a newly recognized disease. The Hantavirus Study Group. *N Engl J Med* 1994; 330 (14): 949-55.
2. Vinh DC, Embil JM. Hantavirus pulmonary syndrome: a concise clinical review. *South Med J* 2009; 102 (6): 620-5.
3. www.cdc.gov/hantavirus/hps
4. Mertz GJ, Miedzinski L, Goade D, et al. Placebo-controlled, double-blind trial of intravenous ribavirin for the treatment of hantavirus cardiopulmonary syndrome in North America. *Clin Infect Dis* 2004; 39 (9): 1307-13.
5. Bouros D, Nicholson AC, Polychronopoulos V, Du Bois RM. Acute interstitial pneumonia. *Eur Respir J* 2000; 15: 412-18.

Capsule

Multitarget stool DNA testing for colorectal cancer screening

An accurate, non-invasive test could improve the effectiveness of colorectal cancer screening. Imperiale and colleagues compared a non-invasive, multitarget stool DNA test with a fecal immunochemical test (FIT) in persons at average risk for colorectal cancer. The DNA test includes quantitative molecular assays for *KRAS* mutations, aberrant *NDRG4* and *BMP3* methylation, and β -actin, plus a hemoglobin immunoassay. Of the 9989 participants who could be evaluated, 65 (0.7%) had colorectal cancer and 757 (7.6%) had advanced precancerous lesions (advanced adenomas or sessile serrated polyps measuring ≥ 1 cm in the greatest dimension) on colonoscopy. The sensitivity for detecting colorectal cancer was 92.3% with DNA testing and 73.8% with FIT ($P = 0.002$). The sensitivity for detecting

advanced precancerous lesions was 42.4% with DNA testing and 23.8% with FIT ($P < 0.001$). The rate of detection of polyps with high grade dysplasia was 69.2% with DNA testing and 46.2% with FIT ($P = 0.004$); the rates of detection of serrated sessile polyps measuring 1 cm or more were 42.4% and 5.1%, respectively ($P < 0.001$). Specificities with DNA testing and FIT were 86.6% and 94.9%, respectively, among participants with non-advanced or negative findings ($P < 0.001$) and 89.8% and 96.4%, respectively, among those with negative results on colonoscopy ($P < 0.001$). The numbers of persons who would need to be screened to detect one cancer were 154 with colonoscopy, 166 with DNA testing, and 208 with FIT.

N Engl J Med 2014; 370: 1287
 Eitan Israeli

Capsule

Tweaking a switch in mechanisms of gene regulation

Transcription factors regulate gene expression by binding to specific chromosomal operator sites. Many transcription factors are repressors, with transcription turned off when the repressor is bound. A simple operator occupancy model assumes that the level of repression is determined only by the equilibrium binding of the repressor to its operator. Hammar et al. used a single-molecule chase assay to directly test this in living cells. They measured the time that the lac repressor protein LacI remained bound to the natural lacO₁ operator and to a stronger, artificial lacO_{sym} operator. It is assumed that transcription is turned off during this time, so this is termed τ_{off} . They also measured the average time that the operators remained unbound so that transcription can be on (τ_{on}). The repression ratio in the simple occupancy model would be given by $RR = (\tau_{on} + \tau_{off}) / \tau_{on}$.

The calculated repression ratios were compared with repression ratios measured based on an enzymatic reporter assay, thus monitoring protein expression rather than repressor binding. There was agreement for the lacO₁ operator, but for the lacO_{sym}, more repression was seen than would be expected based on a simple occupancy model. This could be accounted for either by promoter-specific cooperative interactions between LacI and RNA polymerase or simply by transcription initiation driving the system out of equilibrium; fast transcription initiation could lead to the synthesis of transcripts before the repressor has equilibrated with DNA. Such effects need to be considered in examining mechanisms of gene regulation.

Nat Genet 2014; 10.1038/ng.2905
 Eitan Israeli

“Millions long for immortality but do not know what to do with themselves on a rainy Sunday afternoon”

Susan Ertz (1894-1985), British novelist