

Concomitant Occurrence of Pyoderma Gangrenosum and Erythema Nodosum in Inflammatory Bowel Disease

Ilan Goldberg MD¹, Oksana Finkel MD¹, Andrea Gat MD², Eli Sprecher MD PhD¹ and Helena Martinez de Morentin MD¹

Departments of ¹Dermatology and ²Pathology, Tel Aviv Sourasky Medical Center, affiliated with Sackler Faculty of Medicine, Tel Aviv University, Tel Aviv, Israel

ABSTRACT: Erythema nodosum and pyoderma gangrenosum are common skin manifestations in inflammatory bowel diseases. Curiously, these two cutaneous features have seldom been reported to occur simultaneously. We present three patients affected with inflammatory bowel disease with concomitant erythema nodosum and pyoderma gangrenosum.

IMAJ 2014; 16: 168–170

KEY WORDS: inflammatory bowel disease, erythema nodosum, pyoderma gangrenosum

Inflammatory bowel diseases, which include ulcerative colitis and Crohn's disease, are associated in 20–40% of cases with extra-intestinal manifestations involving almost every organ system in the body, but most frequently the skin. Erythema nodosum and pyoderma gangrenosum are the most frequent skin manifestations associated with IBD. Although cutaneous manifestations are common in IBD, seldom have EN and PG been reported to occur simultaneously in the same patient. We present three cases featuring the concomitant occurrence

of EN and PG, suggesting that this association may be more common than reported in the literature.

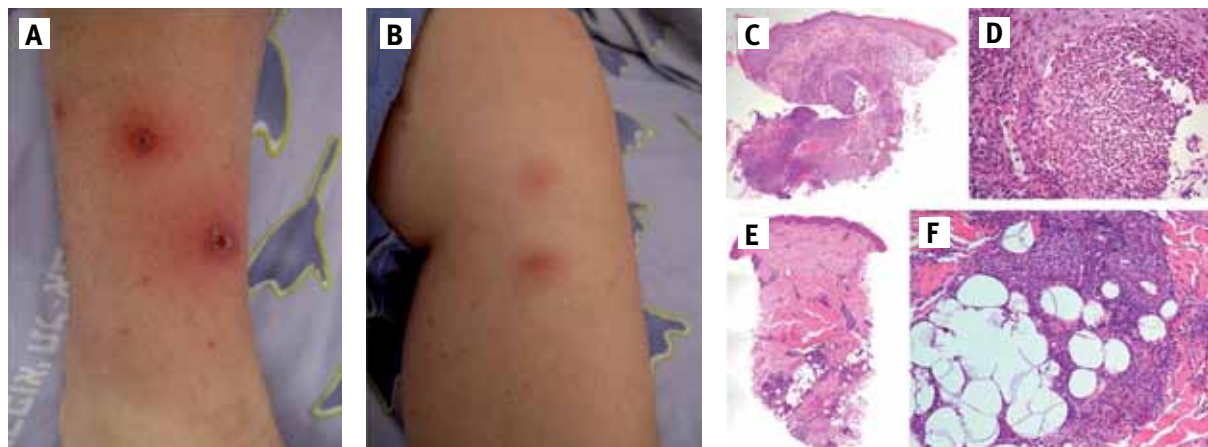
PATIENT 1

A 19 year old woman, who had been diagnosed with Crohn's disease at age 16, had been treated with 5-salicylic acid 1 g tid and was in remission for the last few years, presented with a generalized pustular rash, oral apthae, fever up to 40°C, and recurrent gastrointestinal complaints for 6 weeks prior to admission. The patient was treated with metronidazole 500 mg tid and prednisone 40 mg with amelioration of the rash and normalization of her temperature, but as the prednisone was tapered down to 20 mg per day the pustular rash reappeared. The patient was hospitalized for further management.

On examination, she displayed a disseminated rash involving her scalp, face, chest, abdomen, back, arms and legs; the rash appeared as 2–15 mm pustules surrounded by an erythema-

IBD = inflammatory bowel disease
EN = erythema nodosum
PG = pyoderma gangrenosum

Figure 1. Clinical and pathological features of patient 1. **[A]** Two small ulcers surrounded by a white-purplish rim and an erythematous halo on the right anterior shin. **[B]** Two erythematous nodules, 3 cm in diameter each, on the left medial calf. **[C & D]** Histopathological examination of a skin biopsy obtained from one of the ulcers showing a dense interstitial neutrophilic infiltrate (Hematoxylin & eosin, original magnification of C x 20, and D x 200). **[E & F]** Histopathological examination of a skin biopsy obtained from one of the nodules showing septal panniculitis in E and a dense neutrophilic and histiocytic infiltrate in F (Hematoxylin & eosin, original magnification of E x 20 and F x 200)



tous halo [Figure 1A]. In addition, over the left medial calf, two erythematous nodules were found, each 3 cm in diameter, infiltrated and tender on palpation [Figure 1B]. The rest of the physical examination, including the oral mucosa, was normal.

Biopsy of one of the eroded pustules showed a dense interstitial neutrophilic infiltrate, compatible with PG [Figure 1C], while biopsy obtained from the erythematous nodule revealed septal panniculitis with dense neutrophilic infiltrate also involving the deep dermis and non-discrete histiocytic granuloma with giant cells, compatible with EN [Figure 1D].

The patient was treated with intravenous hydrocortisone 100 mg tid, azathioprine 100 mg qd, and the 5-aminosalicylic acid dose was raised to 1 g qid. Following clinical improvement, the intravenous steroid treatment was stopped and prednisone 60 mg qd was started with gradual tapering down. Under this regimen, the pustules ulcerated and then disappeared gradually, and her gastrointestinal symptoms resolved.

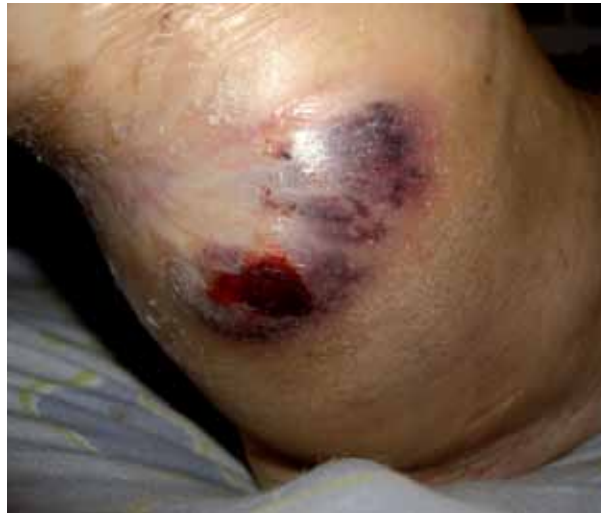PATIENT 2

A 20 year old woman diagnosed with ulcerative colitis for the previous 2 years was in remission with 5-aminosalicylic acid 1 g tid. Two months prior to her hospitalization, due to intestinal disease recurrence she was started on azathioprine which was stopped after only a week due to myalgia and shortness of breath. Following discontinuation of azathioprine, a lesion clinically compatible with PG appeared on her right popliteal fossa and concomitantly lesions clinically suggestive of EN appeared on her lower legs bilaterally. Skin biopsies confirmed both clinically suspected diagnoses, with dense interstitial neutrophilic infiltrate compatible with PG and septal panniculitis compatible with EN. The patient was treated with hydrocortisone intravenously 100 mg tid and cyclosporine 250 mg daily with good clinical response. Following improvement, cyclosporine was stopped gradually and simultaneously azathioprine was reintroduced (after genetic testing ruled out carrier status for 3A-Ala154Thr+Tyr240Cys, 3B-Ala154Thr and 3C-Tyr240Cys mutations in *TPMT*), with no side effects or recurrence of her skin or intestinal disease.

PATIENT 3

A 49 year old woman had been treated for ulcerative colitis for the past 25 years with infliximab, azathioprine, methotrexate, and during severe exacerbations with oral prednisone. For the past few years she was taking 5-aminosalicylic acid 4 g qd. The patient also had ankylosing spondylitis, and peripheral arthritis for 23 years. In addition, she reported a previous history of PG and EN that appeared on her limbs on separate occasions. The patient was hospitalized because of the progressive development of an exceedingly painful new ulcer, 3 cm in diameter over her right posterior calf, with purplish borders,

Figure 2. A superficial ulcer at the periphery of a purplish edematous plaque on the right posterior calf of patient 3



clinically compatible with PG [Figure 2], accompanied by erythematous indurated and tender plaques on her upper and lower extremities suggestive of EN. She also complained of recrudescence of bloody stools and abdominal pain. She was treated with intravenous hydrocortisone 100 mg tid which led to amelioration of all intestinal and dermatological complaints. The intravenous steroid treatment was changed to prednisone 60 mg, which was tapered down with gradual resolution of the PG as well as fading of the EN lesions. The patient denied skin biopsies as both skin manifestations were well known to her and had been biopsied in the past.

DISCUSSION

IBD refers to a relatively heterogeneous group of inflammatory diseases affecting various parts of the gastrointestinal tract, whose pathogenesis remains incompletely understood. IBD is often associated with extra-intestinal manifestations such as uveitis and episcleritis, peripheral arthritis, sclerosing cholangitis, lung disease, venous and arterial thromboembolism, autoimmune hemolytic anemia, and cutaneous disorders, which include Sweet's syndrome, necrotizing cutaneous vasculitis, psoriasis, metastatic Crohn's disease, EN and PG.

EN and PG are the most frequent extra-intestinal manifestations in patients with IBD. According to the literature, the frequency of EN and PG in IBD is 4% and 0.75% respectively [1]. Cutaneous extra-intestinal manifestations in IBD patients do not correlate with the severity of the disease [1]. However, typically, EN develops around the time of gastrointestinal flares [2], in contrast with PG which commonly runs a course independent of gastrointestinal disease activity [3]. PG and EN have been found to be indicative of IBD-associated arthritis [2].

EN occurs more commonly in Crohn's disease (90%) with extensive intestinal involvement than in ulcerative colitis [1,3,4], and more commonly in women (80%) than in men [4], as in our series. Approximately 50% of the cases recur [5]. Treatment of the underlying IBD brings EN to remission, which heals with no scarring but may occasionally leave a mild residual hyperpigmentation. In contrast to EN, PG occurs more frequently in ulcerative colitis than in Crohn's disease [3], although this has not been validated in all studies [1].

EN and PG are clinical conditions that share several characteristics: both either appear secondary to a systemic process or can be idiopathic, and both respond to immunosuppressive medications. Studies have shown an elevated number of activated polymorphonuclear cells in EN lesions, which produce high levels of reactive oxygen intermediates. These activated polymorphonuclear cells might activate themselves and other immunocytes in an autocrine and/or paracrine manner through secretion of interleukins 6 and 8 and tumor necrosis factor-alpha [6]. An elevated level of IL-6 and IL-8 has also been found in PG [7,8], suggesting intersecting pathophysiological pathways for these two dermatoses, which in turn may explain the fact that they have been associated with a similar spectrum of systemic diseases including IBD, hematological malignancies, autoimmunity and pregnancy.

IL = interleukin

In conclusion, we believe that the concomitant occurrence of these two conditions may be more common in IBD than usually thought.

Corresponding author:

Dr. I. Goldberg

Dept. of Dermatology, Tel Aviv Sourasky Medical Center, Tel Aviv 64239, Israel

Phone: (972-3) 697-4287

Fax: (972-3) 697-4810

email: ilangoldberg1@gmail.com

References

1. Farhi D, Cosnes J, Zizi N, et al. Significance of erythema nodosum and pyoderma gangrenosum in inflammatory bowel diseases: a cohort study of 2402 patients. *Medicine (Baltimore)* 2008; 87 (5): 281-93.
2. Yüksel I, Baar O, Ataseven H, et al. Mucocutaneous manifestations in inflammatory bowel disease. *Inflamm Bowel Dis* 2009; 15: 546-50.
3. Kethu SR. Extraintestinal manifestations of inflammatory bowel diseases. *J Clin Gastroenterol* 2006; 40 (6): 467-92.
4. Freeman HJ. Erythema nodosum and pyoderma gangrenosum in 50 patients with Crohn's disease. *Can J Gastroenterol* 2005; 19 (10): 603-6.
5. Martin de Carpi J, Chavez Caraza K, Vicente Villa MA, et al. Skin manifestations of pediatric inflammatory bowel disease. *An Pediatr (Barc)* 2009; 70 (6): 570-7.
6. Kunz M, Beutel S, Bröcker E. Leucocyte activation in erythema nodosum. *Clin Exp Dermatol* 1999; 24 (5): 396-401.
7. Kawakami T, Yamazaki M, Soma Y. Reduction of interleukin-6, interleukin-8, and anti-phosphatidylserine-prothrombin complex antibody by granulocyte and monocyte adsorption apheresis in a patient with pyoderma gangrenosum and ulcerative colitis. *Am J Gastroenterol* 2009; 104 (9): 2363-4.
8. Oka M, Berking C, Nesbit M, et al. Interleukin-8 overexpression is present in pyoderma gangrenosum ulcers and leads to ulcer formation in human skin xenografts. *Lab Invest* 2000; 80 (4): 595-604.

Capsule

Elevated serum pesticide levels and risk for Alzheimer disease

Richardson and co-authors evaluated the association between serum levels of DDE and Alzheimer disease (AD) and whether the apolipoprotein E (*APOE*) genotype modifies the association. The authors performed a case-control study consisting of existing samples from patients with AD and control. Serum levels of DDE were measured in 79 control and 86 AD cases. The results showed that levels of DDE were 3.8-fold higher in the serum of those with AD (mean [SEM], 2.64 [0.35] ng/mg cholesterol) when compared with control participants (mean [SEM], 0.69 [0.1] ng/mg cholesterol, $P < 0.001$). The highest tertile of DDE levels was associated with an odds ratio of 4.18 for increased risk for and lower Mini-Mental State Examination scores (-1.605). The Mini-Mental State Examination scores in the highest tertile of DDE were -1.753 points lower in the subpopulation carrying

an *APOE* $\epsilon 4$ allele compared with those carrying an *APOE* $\epsilon 3$ allele (P interaction = 0.04). Serum levels of DDE were highly correlated with brain levels of DDE ($P = 0.95$). Exposure of human neuroblastoma cells to DDT or DDE increased levels of amyloid precursor protein. The authors conclude that elevated serum DDE levels are associated with an increased risk for AD and carriers of an *APOE4* $\epsilon 4$ allele may be more susceptible to the effects of DDE. Both DDT and DDE increase amyloid precursor protein levels, providing mechanistic plausibility for the association of DDE exposure with AD. Identifying people who have elevated levels of DDE and carry an *APOE* $\epsilon 4$ allele may lead to early identification of some cases of AD.

JAMA Neurol 2014; Doi:10.1001/jamaneurol.2013.60300

Eitan Israeli

“Non-violence leads to the highest ethics, which is the goal of all evolution. Until we stop harming all other living beings, we are still savages”

Thomas Edison (1847-1931), American inventor of numerous devices that greatly influenced life around the world, such as the phonograph, motion picture camera and electric light bulb. He was one of the first inventors to apply the principles of mass production and large-scale teamwork to the process of invention and is often credited with the creation of the first industrial research laboratory. He has thousands of patents in his name