

# Metal-on-Metal Hip Replacement: A New Concept for an Old Problem?

Ortal Segal MD<sup>1</sup> and Ramit Maoz-Segal MD<sup>2</sup>

<sup>1</sup>Division of Orthopedics, Tel Aviv Sourasky Medical Center, Tel Aviv, Israel

<sup>2</sup>Zabludowicz Center for Autoimmune Diseases, Sheba Medical Center, Tel Hashomer, Israel

Both affiliated with Sackler Faculty of Medicine, Tel Aviv University, Ramat Aviv, Israel

**KEY WORDS:** metal-on-metal hip replacement, autoimmune (autoinflammatory) syndrome induced by adjuvants (ASIA), silicone, adjuvant, vaccination, autoimmunity

*IMAJ* 2013; 15: 722–724

## For Editorial see page 714

The autoimmune/inflammatory syndrome induced by adjuvant, known as ASIA, describes the clinical manifestations – mostly inflammatory and autoimmune – following chronic stimulation by adjuvants. We present the case of an 85 year old woman who underwent a total hip replacement and later developed a local and systemic reaction to the material used. This case is consistent with the diagnostic criteria for ASIA.

## PATIENT DESCRIPTION

An 85 year old woman, lucid and independent with mild background illnesses (chronic obstructive lung disease and diabetes), underwent a total hip replacement due to osteoarthritis secondary to avascular necrosis of the femoral head of her left hip, using Biomet implants with a metal-on-polyethylene articulation. The surgery was performed without any complications and the patient completed the usual rehabilitation protocol. Three years later, she underwent a total hip replacement (right hip); this time Depuy implants were used with a mega metal

head-on-metal articulation. The surgery was performed without any complications and the patient completed the usual rehabilitation protocol.

Six months after this surgery the patient complained of ongoing and increasing pain around the right hip region. At the outpatient clinic, examination revealed a normal surgical scar, a good range of motion and no signs of neurovascular deficit. The pelvic X-ray tests did not demonstrate loosening or any other abnormality. The blood tests were within normal limits except for elevated erythrocyte sedimentation rate. An ultrasonography study demonstrated some fluid around the implants and aspiration yielded 40 ml of cloudy fluid. The fluid analysis revealed a glucose level of 10 mg/dl and white blood cell count of 300 cells/ $\mu$ l. Culture was negative. A bone scintigraphy with marked leukocytes was normal.

Due to a subfebrile event and continuous pain, 10 months after surgery the patient was hospitalized and ultrasonographic imaging with aspiration was performed for the second time. The articular fluid (50 ml) was cloudy. The glucose level was 53 mg/dl and WBC count 2000 cells/ $\mu$ l. Bacterial and fungal cultures were negative. An early arthrotomy and exploration of the hip joint revealed a large amount of clear fluid and a large pseudocapsule tissue around the joint. Multiple cultures were taken and a proper debridement was performed including biopsy sampling. The cultures showed multiple bacterial colonies that were interpreted as contamination. Nevertheless, the patient was treated with intravenous vancomycin for 14 days that resulted in amelioration

of her symptoms and normalization of the inflammatory markers. The biopsy revealed fibro-fatty tissue with fibrin, indicating a chronic inflammation.

The patient was discharged from hospital and referred for follow-up at the outpatient orthopedic clinic. She later underwent allergy screening by patch testing. The test indicated cobalt and chrome hypersensitivity type IV.

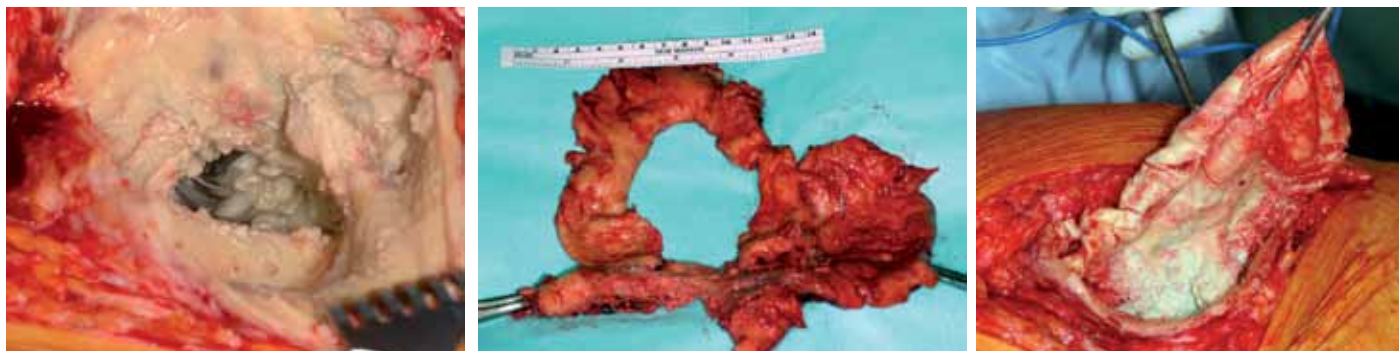
At follow-up examinations, she continued to complain about pain in her right hip. Her ESR was elevated to 107/hour. The repeated imaging studies, including X-ray and bone scan, were unremarkable.

Thirty months after the primary surgery a repeated hip aspiration under ultrasonographic guidance yielded 350 ml cloudy fluid. The lab results showed glucose 5 mg/dl and the presence of leukocytes. Cultures are negative including those for *Mycobacterium*.

Following that, a revision surgery was performed to replace the metal component with a ceramic-on-ceramic articulation. During surgery a large amount of yellow fluid was drained and a huge pseudo-capsule was removed and sent to the pathology lab [Figure]. The metal components (head and cup) were removed and ceramic inserts were implanted. Due to the total destruction of soft tissue a constrained hip was needed. During the 18 month follow-up after the revision surgery and removal of the metal-bearing components, the patient was asymptomatic and satisfied with the functional results.

ESR = erythrocyte sedimentation rate

Huge pseudo-capsule that was removed during the re-operation



**COMMENT**

**THE INTERACTION BETWEEN ORTHOPEDICS AND IMMUNOLOGY**

It is well recognized that unusual lymphocytic aggregates that occur in the peri-prosthetic tissues of some patients with second-generation CoCr metal-on-metal hip replacements are not generally found in tissues surrounding other articulations. These findings have been associated with pain, joint effusion, aseptic loosening and osteolysis. The histologic and immunohistochemical appearance of the articular surrounding tissue is usually dominated by perivascular and diffuse T and B lymphocyte infiltrates, including secondary lymphoid follicles that are morphologically suggestive of a hypersensitivity reaction [1]. From an immunological point of view, those responses usually referred to as metal sensitivity are generally classified as type IV delayed-type hypersensitivity. Metal antigen-sensitized T cell DTH lymphocytes release various cytokines that result in accumulation and activation of macrophages, meaning that most DTH participating cells are macrophages and only 5% of cells present are lymphocytes [2].

A new term has been coined to explain the above phenomena in patients who underwent hip replacement surgery with metal-on-metal bearings: ALVAL (aseptic lymphocyte-dominated vasculitis-associated lesion). The phenomenon is consid-

ered reminiscent of a DTH response and is associated with a unique local histologic response in which there is a prominent perivascular and diffuse infiltration of lymphocytes. Recently a few publications have described the macroscopic appearance of this reaction as “pseudo-tumor” [3]. Finally, as a result of these publications, in 2010 Johnson & Johnson published a recall of their metal-on-metal hip replacement due to a high rate of functional failure among operated patients.

**FROM AN IMMUNOLOGIC POINT OF VIEW: A NEW CONCEPT**

The autoimmune/inflammatory syndrome induced by adjuvant, known as ASIA, was recently described and the criteria for the diagnosis enumerated [4]. This syndrome emerges following chronic stimulation of the immune system by agents that have adjuvant characteristics. The purpose of the authors was to summarize in one entity the different autoimmune manifestations following exposure to adjuvants such as vaccinations, silicone implants, dental and cosmetic skin fillers, as well as any foreign material that induces autoimmune manifestations in subjects genetically vulnerable to autoimmune diseases. Indeed, the relative rarity of the events does suggest a role for individual susceptibility (such as genetic risk) [5]. Since presentation of the syndrome, many case reports meeting the suggested criteria were published [Table]. ASIA is acknowledged by many as a guide for physicians to characterize and manage less-defined immune mediated conditions.

**Suggested criteria for the diagnosis of ASIA**

**Major criteria:**

- Exposure to an external stimuli (infection, vaccine, silicone, adjuvant) prior to clinical manifestations
- Appearance of “typical” clinical manifestations:
  - Myalgia, myositis, or muscle weakness
  - Arthralgia and/or arthritis
  - Chronic fatigue, non-refreshing sleep, or sleep disturbances
  - Neurological manifestations (especially associated with demyelination)
  - Cognitive impairment, memory loss
  - Pyrexia
  - Dry mouth
- Removal of inciting agent induces improvement
- Typical biopsy of involved organs

**Minor criteria:**

- The appearance of autoantibodies or antibodies directed at the suspected adjuvant
- Other clinical manifestations (i.e., irritable bowel syndrome)
- Specific HLA (e.g., HLA DRB1, HLA DQB1)
- Evolution of an autoimmune disease (e.g., multiple sclerosis, Sjögren’s syndrome)

For the diagnosis of ASIA, there must be the presence of at least 2 major or 1 major and 2 minor criteria.

Source [4]: *J Autoimmun* 2011; 36: 4-8.

The case presented here also meets the ASIA diagnostic criteria. The patient had clinical manifestations after the hip replacement with a high probability of a smoldering inflammatory response to the chronic metal exposure. The clinical presentation 10 months after the surgery – namely, subfebrile temperature, pain despite the functioning replaced hip joint, and elevated inflammatory markers with negative cultures of the articular fluid – indicate an inflammatory reaction. Nevertheless, the histological findings from the large pseudo-capsule of fibrofatty tissue with fibrin support the chronic inflammation and were not consistent with a pure allergic reaction to metals.

DTH = delayed-type hypersensitivity

Moreover, the re-operation and removal of the initiating agent led to a rapid clinical improvement.

In summary, the case presented here meet the suggested diagnostic criteria for the ASIA syndrome. As suggested before, recognition of ASIA as a systemic autoimmune entity can heighten physicians' index of suspicion and encourage earlier diagnosis of this important clinical entity. From the present report and similar case reports, one can conclude that knowledge about the syndrome termed ASIA should

be spread among physicians from different disciplines, especially surgeons (plastic, dental, orthopedic and others).

#### Corresponding author:

**Dr. O. Segal**

Division of Orthopedics, Tel Aviv Sourasky Medical Center, Tel Aviv 64239, Israel

email: ortal\_san@yahoo.com, ramitsegal@gmail.com

#### References

1. Willert HG, Buchhorn GH, Fayyazi A, et al. Metal-on-metal bearings and hypersensitivity in patients with artificial hip joints: a clinical and histomorphological study. *J Bone Joint Surg Am* 2005; 87: 28-36.
2. Hensten-Petersen A. Allergy and hypersensitivity. In: Morrey BF, ed. *Biological, Material, and Mechanical Considerations of Joint Replacements*. New York: Raven Press, 1993: 353-60.
3. Hauptfleisch J, Pandit H, Grammatopoulos G, Gill HS, Murray DW, Ostlere S. A MRI classification of periprosthetic soft tissue masses pseudotumours associated with metal-on-metal resurfacing hip arthroplasty. *Skeletal Radiol* 2012; 41 (2): 149-55.
4. Shoenfeld Y, Agmon-Levin N. ASIA – autoimmune/inflammatory syndrome induced by adjuvant. *J Autoimmun* 2011; 36: 4-8.
5. Israeli E, Agmon-Levin N, Blank M, Shoenfeld Y. Adjuvants and autoimmunity. *Lupus* 2009; 18: 1217-25.

### Capsule

#### Odor receptors and neurons for DEET and new insect repellents

There are major impediments to finding improved DEET alternatives because the receptors causing olfactory repellency are unknown, and new chemicals require exorbitant costs to determine safety for human use. Kain et al. identified DEET-sensitive neurons in a pit-like structure in the *Drosophila melanogaster* antenna called the sacculus. They express a highly conserved receptor, Ir40a, and flies in which these neurons are silenced or Ir40a is knocked down lose avoidance to DEET. The authors used a computational structure activity screen of > 400,000 compounds that identified > 100 natural

compounds as candidate repellents. They tested several and found that most activate Ir40a+ neurons and are repellents for *Drosophila*. These compounds are also strong repellents for mosquitoes. The candidates contain chemicals that do not dissolve plastic, are affordable and smell mildly like grapes, with three considered safe in human foods. These findings pave the way to discover new generations of repellents that will help fight deadly insect-borne diseases worldwide.

*Nature* 2013; 502: 507

Eitan Israeli

### Capsule

#### Experimental viral evolution reveals major histocompatibility complex polymorphisms as the primary host factors controlling pathogen adaptation and virulence

Using an experimental evolution approach, Kubinak et al. recently demonstrated that the mouse-specific pathogen Friend virus (FV) complex adapted to specific major histocompatibility complex (MHC) genotypes, which resulted in fitness tradeoffs when viruses were exposed to hosts possessing novel MHC polymorphisms. Here, the group reports the analysis of patterns of pathogen adaptation and virulence evolution from viruses adapting to one of three hosts that differ across the entire genome (A/WySn, DBA/2) and BALB/c). They found that serial passage of FV complex through these mouse genotypes resulted in significant increases in pathogen fitness (156-fold) and virulence (11-fold). Adaptive responses by post-passage viruses also resulted in host genotype-specific patterns of adaptation. To evaluate the

relative importance of MHC versus non-MHC polymorphisms as factors influencing pathogen adaptation and virulence, the researchers compared the magnitude of fitness tradeoffs incurred by post-passage viruses when infecting hosts possessing either novel MHC polymorphisms alone or hosts possessing novel MHC and non-MHC polymorphisms. MHC polymorphisms alone accounted for 71% and 83% of the total observed reductions in viral fitness and virulence in unfamiliar host genotypes, respectively. Strikingly, these data suggest that genetic polymorphisms within the MHC, a gene region representing only ~0.1% of the genome, are major host factors influencing pathogen adaptation and virulence evolution.

*Genes Immun* 2013; 14: 365

Eitan Israeli

#### “Knowledge comes, but wisdom lingers”

Lord Alfred Tennyson (1809-1892), Poet Laureate of Great Britain and Ireland during much of Queen Victoria's reign and remains one of the most popular British poets