

Trans-Catheter Aortic Valve Implantation for Non-Classical Indications

Amit Segev MD, Dan Spiegelstein MD, Paul Fefer MD, Amichai Shinfeld MD, Ilan Hay MD, Ehud Raanani MD and Victor Guetta MD

Leviev Heart Center, Sheba Medical Center, Tel Hashomer, affiliated with Sackler Faculty of Medicine, Tel Aviv University, Ramat Aviv, Israel

ABSTRACT: **Background:** Trans-catheter aortic valve implantation (TAVI) has emerged as a novel therapeutic approach for patients with severe tricuspid aortic stenosis (AS) not suitable for aortic valve replacement.

Objectives: To describe our initial single-center experience with TAVI in patients with “off-label” indications.

Methods: Between August 2008 and December 2011 we performed TAVI in 186 patients using trans-femoral, trans-axillary, trans-apical and trans-aortic approaches. In 11 patients (5.9%) TAVI was undertaken due to: a) pure severe aortic regurgitation (AR) (n=2), b) prosthetic aortic valve (AV) failure (n=5), c) bicuspid AV stenosis (n=2), and d) prosthetic valve severe mitral regurgitation (MR) (n=2).

Results: Implantation was successful in all: six patients received a CoreValve and five patients an Edwards-Sapien valve. In-hospital mortality was 0%. Valve hemodynamics and function were excellent in all patients except for one who received an Edwards-Sapien that was inside a Mitroflow prosthetic AV and led to consistently high trans-aortic gradients. No significant residual regurgitation in AR and MR cases was observed.

Conclusions: TAVI is a good alternative to surgical AV replacement in high risk or inoperable patients with severe AS. TAVI for non-classical indications such as pure AR, bicuspid AV, and failed prosthetic aortic and mitral valves is feasible and safe and may be considered in selected patients.

IMAJ 2013; 15: 467–471

KEY WORDS: aortic stenosis (AS), aortic insufficiency, bioprosthetic valves, trans-catheter aortic valve implantation (TAVI)

For Editorial see page 511

Trans-catheter aortic valve implantation has emerged as an alternative to surgical aortic valve replacement or continued medical therapy in high risk or inoperable patients with severe aortic stenosis [1-4]. Both Edwards-Sapien and CoreValve trans-catheter valves are designed for patients with tricuspid calcified aortic stenosis. Calcifications are essential for the adherence of the implanted valve to the native aortic annulus [4].

Although TAVI is indicated only for patients with severe symptomatic calcific AS, it has been used in a number of additional valvular pathologies in the “no-option” patient. Such “off-label” indications are emerging in the current literature. Off label means outside of the common indication. Several groups have reported the use of TAVI for the treatment of bicuspid aortic valve [5] and for failed bioprosthesis – both in aortic and mitral positions [6-9]. In the present paper we report our single-center experience with the off-label use of TAVI in 11 cases – severe bicuspid AS, pure severe aortic regurgitation, and failed aortic and mitral bioprostheses.

PATIENTS AND METHODS

Between August 2008 and December 2011 TAVI was performed in 186 patients in our center. These included 124 trans-femoral CoreValve, 6 trans-axillary CoreValve, 24 trans-apical Edwards, 28 trans-femoral Edwards, and 4 trans-aortic Edwards. Eleven patients (5.9%) underwent TAVI or trans-catheter mitral valve implantation for off-label indications including bicuspid AV stenosis, pure severe AR, failed biologic AV prostheses, and failed biologic mitral valve prostheses. We report procedural details and the in-hospital and 30 day outcomes. All patients were critically reviewed by a dedicated heart team and each signed an informed consent stressing the “off-label” use of TAVI.

RESULTS

Table 1 summarizes the clinical and procedural characteristics in all patients.

BICUSPID AORTIC VALVE STENOSIS

Two patients underwent TAVI for severe bicuspid AV stenosis. Case 1 was a 54 year old man post-coronary artery bypass graft with severe combined valvular disease. The patient was admitted for severe left and right heart failure and was diagnosed with severe bicuspid aortic stenosis, severe tricuspid regurgitation, and moderate pulmonary hypertension. He was turned

TAVI = trans-catheter aortic valve implantation
AS = aortic stenosis
AV = aortic valve

Table 1. Patients' characteristics and outcome

Patient no.	TAVI indication	Age (yr)	Gender	EuroScore (%)	Valve type	Access	TEE	Anesth.	Success	PPM	30 day status	Comments	Echo at follow-up
1	Bicuspid AS	54	M	43.5	Edwards 26	Apical	Yes	General	Yes	No	Alive	Concomitant severe TR, RV dysfunction	Aortic gradient 17/10 Moderate-severe TR
2	Bicuspid AS	87	F	22.9	Edwards 26	Femoral	No	Local	Yes	Yes	Alive	Severe AS	Aortic gradient 20/13 No AR
3	Pure AR	63	M	49.9	CoreValve 29	Axillary	Yes	General	Yes	No	Alive	Chronic aortic dissection, LVEF 30%	Mild AR
4	Pure AR	86	M	27.7	CoreValve 29	Femoral	No	Local	Yes	No	Alive	Severe AR Moderate MR	LVEDV 64→57 mm Pulmonary pressure 85→60 Mild AR
5	Prosthetic AV	70	F	20.6	Edwards 23	Apical	Yes	General	Yes	No	Alive	Mitroflow 21 Severe AS	Persistent aortic gradient 88/58
6	Prosthetic AV	80	F	33.6	CoreValve 26	Femoral	No	Local	Yes	No	Alive	Edwards-Carpentier 21 Severe AS	Aortic gradient 23/14
7	Prosthetic AV	82	F	36.6	CoreValve 26	Femoral	No	Local	Yes	No	Alive	Freestyle Stentless 21 No aortic sinuses Severe AS Severe MR	Mild MR Mild-moderate AR Pulmonary pressure 57→33
8	Prosthetic AV	80	F	22	CoreValve 29	Femoral	No	General	Yes	No	Alive	Edwards-Carpentier 25 Severe AR	Mild AR Pulmonary pressure 69→48
9	Prosthetic AV	81	F	41.1	CoreValve 26	Femoral	No	Local	Yes	No	Alive	Mitroflow 23 Severe AR Moderate AS	Trivial AR Pulmonary pressure 60→30
10	Prosthetic MV	85	M	51.1	Edwards 26	Apical	Yes	General	Yes	No	Alive	Edwards-Baxter 27 Severe MR and TR	No MR Mitral gradient 28/13
11	Prosthetic MV	77	F	29.3	Edwards 26	Apical	Yes	General	Yes	No	Alive	Edwards-Carpentier 27 Severe MR	Mild MR Mitral gradient 13/4 Pulmonary pressure 68→40

TAVI = trans-catheter aortic valve implantation, AS = aortic stenosis, PPM = permanent pacemaker, AR = aortic regurgitation; MR=mitral regurgitation, TR = tricuspid regurgitation, EF = ejection fraction, CABG = coronary artery bypass graft, AV = aortic valve, MV = mitral valve

down for conventional double valve surgery. TAVI using the Edwards-Sapien valve was performed trans-apically due to severe peripheral vascular disease. The valve was implanted successfully, with satisfactory hemodynamics at follow-up. At follow-up the patient's clinical condition had improved. Of note, tricuspid regurgitation grade was also decreased at follow-up.

Case 2 was an 87 year old woman with severe aortic stenosis due to a bicuspid valve. A trans-femoral approach was used to successfully implant an Edwards-Sapien 26 mm valve. Her hospitalization and follow-up were unremarkable, with good valve hemodynamics and significant clinical improvement.

PURE AORTIC INSUFFICIENCY

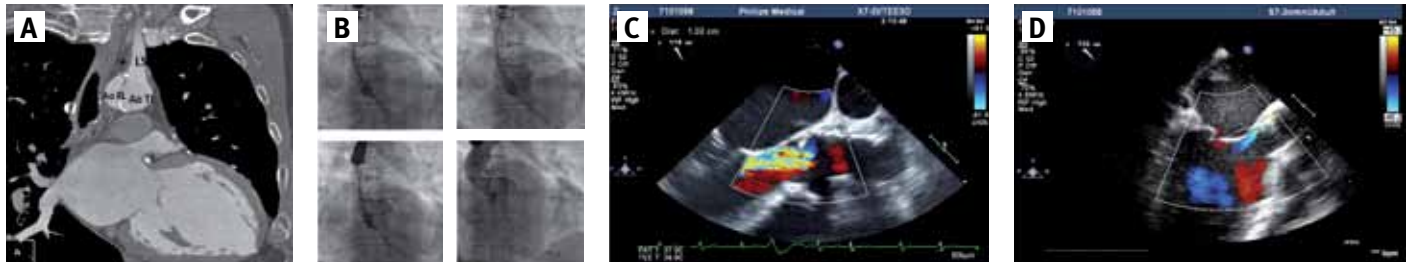
Case 3 was a 63 year old man with a previous history of two open heart surgeries – coronary artery bypass graft and urgent repair of type A aortic dissection that included an aortic interposition graft with aortic valve sparing and persistent aortic dissection involving the aortic arch and the descending aorta. The patient remained active and was followed for asymptomatic moderate aortic regurgitation until 6 months prior to his present admission when he was admitted for severe left heart failure. Echocardiography showed left ventricular enlargement (66/33 mm), left ventricular

ejection fraction of 30%, and severe AR. Aortic annulus was measured by trans-esophageal echocardiogram to be 28 mm with no valvular calcifications. Computed tomography angiography showed a caliber of > 7 mm of the left axillary artery with documented continuation with the true lumen of the ascending aorta and aortic arch [Figure 1A]. Therefore, a trans-axillary implantation of a 29 mm CoreValve was selected. The stages of valve implantation are shown in Figure 1B. Due to the lack of valvular calcification and instability of the delivery system, implantation was performed under rapid pacing. The valve was implanted successfully less than 4 mm below the aortic annulus with evidence of mild AR as assessed by TEE and aortography. Figure 1C shows TEE images indicating pre-procedure severe AR and only mild paravalvular AR immediately post-procedure. The patient recovered well, resumed his regular physical activities and returned to New York Heart Association functional class I.

Case 4 was an 87 year old man with pure severe AR and no valvular calcifications. He had an aortic annulus measured by both TEE and CT angiography to be 27 mm. A trans-femoral implantation of a 29 mm CoreValve was performed success-

AR = aortic regurgitation
TEE = transesophageal echocardiogram

Figure 1. Trans-axillary CoreValve implantation for severe aortic regurgitation. **[A]** CT angiography showing chronic dissection of the arch and continuity of left subclavian artery with aorta true lumen. **[B]** Stages of valve implantation. **[C]** TEE before and after the procedure showing a reduction of regurgitation



fully. Follow-up examination showed a significant improvement in the patient's condition, with a reduction in both left ventricular size and pulmonary systolic pressure.

FAILED AORTIC BIOPROTHESES

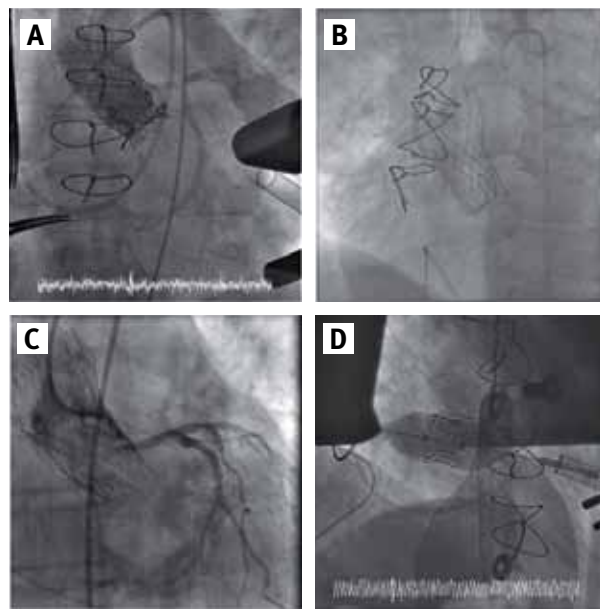
Five patients underwent TAVI for a failed biological prosthetic valve. Case 5 underwent previous surgical AVR with a Mitroflow 21 mm only 3 years prior to her current admission due to heart failure. Echocardiography showed severe AS. The internal diameter of her prosthetic valve was 17 mm and a trans-apical TAVI using the 23 mm Edwards-Sapien valve was therefore offered. The procedure was uneventful. Unfortunately, the patient experienced several episodes of pulmonary congestion during her hospitalization; echocardiography showed persistent high gradients that were confirmed by catheterization. She was offered a repeated surgical AVR but she declined and was discharged from hospital. Figure 2A shows the valve-in-valve position with under-expansion of the Edwards-Sapien valve.

Case 6 had a 12 year old 21 mm Edwards-Carpentier AV. She presented with severe AS and a trans-femoral implantation of a 26 mm CoreValve was successfully performed. Her valve showed satisfactory hemodynamics and her clinical condition had improved significantly. CoreValve-in-valve is shown in Figure 2B.

Case 7, an 82 year old woman who underwent surgical AVR with a 21 mm stentless biological valve 13 years previously, is unique. She presented with heart failure and severe AR. This patient had no aortic sinuses and no significant aortic calcification. Since this valve has no frame, implantation of the Edwards-Sapien was not considered and implantation of a 26 mm CoreValve was undertaken. Due to the lack of coronary sinuses, we aimed that the implantation be as low as possible to avoid coronary occlusion by the leaflets of the implanted new valve. However, the valve was implanted not as planned and was too high. Figure 2C shows that although implanted high, the CoreValve has preserved coronary patency.

Case 8 involved a failed 25 mm Edwards-Carpentier AV with severe AR and moderate-severe AS. The patient had

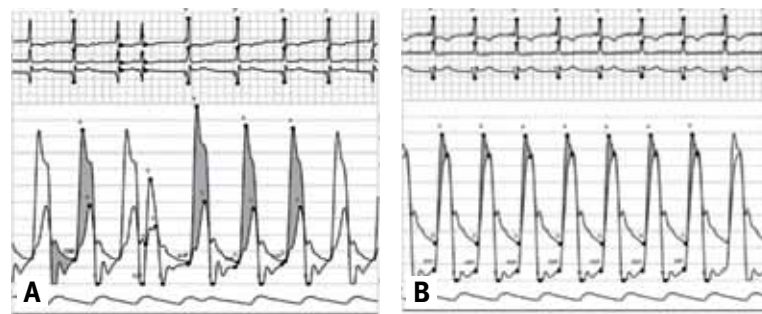
Figure 2. Four cases of valve-in-valve implantation in failed aortic bioprostheses. **[A]** A 23 mm Edwards-Sapien in Mitroflow 21 (note the inadequate expansion of implanted valve). **[B]** A 26 mm CoreValve in a failed Edwards-Carpentier 21 valve. **[C]** A 26 mm CoreValve in a stentless free graft (note lack of aortic sinuses and patent coronary flow). **[D]** Trans-apical implantation of a 26 mm Edwards-Sapien valve in a failed mitral bioprostheses



recurrent pulmonary edema. She underwent a successful trans-femoral implantation of a 29 mm CoreValve. In this case a post-dilation with a 28 mm balloon was performed due to inadequate initial expansion of the CoreValve. Case 9 was similar: a failed Mitroflow 23 bioprosthesis with severe AR causing intractable heart failure. Trans-femoral CoreValve implantation was performed urgently. Figure 3A shows the hemodynamics before implantation with low aortic diastolic pressure and equalization of aortic diastolic pressure and left ventricular end-diastolic pressure. Figure 3B is immediately post-implantation; there is no paravalvular leak and the hemodynamics are satisfactory. The patient recovered within a few days with evidence of a significant decrease in pulmonary pressure.

AVR = aortic valve replacement

Figure 3. Hemodynamics of patient number 9 with failed aortic bioprosthesis with severe AR. **[A]** Pre-procedure. **[B]** Immediately post-procedure



FAILED MITRAL BIOPROSTHESES

Cases 10 and 11 were both elderly patients suffering from symptomatic severe MR due to a failed prosthetic MV. Both cases were successfully implanted by means of the trans-apical approach using a 26 mm Edwards-Sapien valve. The internal diameter of the failed valves was 26 mm in both. No prior valvuloplasty was performed and the valve was deployed using rapid ventricular pacing. Figure 2D shows an Edwards-Sapien valve implanted in the mitral position.

DISCUSSION

In this report we show the feasibility and efficacy of TAVI for off-label indications. In 11 consecutive patients, the Edwards-Sapien or CoreValve were successfully implanted for a variety of indications such as severe AS due to a bicuspid valve, pure AR, and failed prosthetic AV or MV. These data may expand the use of TAVI in inoperable or extremely high risk surgical cases. Larger studies are required to further define the use of TAVI in non-calcified aortic stenosis patients.

TAVI has been shown to be a promising new therapeutic modality for inoperable or high risk patients with severe AS. In inoperable patients, implantation of the Edwards-Sapien valve resulted in a 45% absolute risk reduction in 1 year mortality [1]. In high risk patients both trans-femoral and trans-apical approaches do not seem to be inferior to conventional surgical aortic valve replacement [10] although stroke and paravalvular leaks remain significant complications. Large registries using both Edwards-Sapien and CoreValve have shown favorable procedural success and long-term outcome [2,11-14]. Several other aortic pathologies may require surgical intervention in patients considered inoperable or high risk, and although not formally indicated for TAVI this therapeutic strategy may be successfully implemented in carefully selected patients.

Bicuspid AV is considered unsuitable for TAVI due to its oval-shaped aortic annulus and because the ascending aorta is also involved in the disease [15]. However, when severely stenosed and heavily calcified, the native annulus

and leaflets may hold the frame of both trans-catheter valves enabling a successful implantation. A previous report of 11 patients with bicuspid AV stenosis showed that TAVI is feasible. Symptomatic improvement was achieved in 10 of the 11 patients; however, at 30 days 2 patients who underwent trans-apical implantation died and 1 patient had to be treated surgically due to valve under-sizing [5]. Both available trans-catheter valves may be implanted in a bicuspid aortic valve. Although there are no technical difficulties with the implantation, it is strongly recommended that CT angiography be performed to assess annulus dimensions and shape as well as the presence of calcifications.

Two major concerns arise when considering TAVI for patients with pure AR. The aortic valve anatomy is usually large and there is a lack of valve calcifications. Therefore, a 29 mm CoreValve is almost always the valve of choice. Since CoreValve is attached and secured to both annulus and ascending aorta, valve calcification is not mandatory for a successful implantation. Another technical point is the necessity to implant the valve as high as possible due to the large anatomy. This is not obvious since lack of calcifications do not allow the attachment of the valve during the first part of the implantation process. To enable a stable implantation, rapid pacing should be considered.

Failed biologic prosthetic valves may also be treated with TAVI [6-9]. For both the mitral and aortic positions it is crucial that the operator carefully analyze the size of the failed prosthetic valve and ascertain its internal diameter. The decision regarding which valve to implant is based on the available valve sizes of Edwards and CoreValve and of the access site. In our series, for a patient with failed 21 mm Mitroflow valve with an internal diameter of 17 mm, a 23 mm Edwards-Sapien was chosen, which is also below the company recommended lower limit of 18 mm. In this case, although the procedure was uneventful, the patient did not benefit from the procedure and had persistently high aortic gradients. In contrast, the patient with a failed 21 mm Edwards-Carpentier and internal diameter of 19 mm improved significantly after the procedure during which a 26 mm CoreValve was implanted. From a technical standpoint, TAVI is easier to implant in aortic prosthetic valves as compared to native valves for two reasons: first, no prior aortic valvuloplasty is required, and second, in stented valves, the aortic annulus is clearly marked by the prosthetic valve. In stentless bioprosthesis valves, as in our case, the lack of coronary sinuses and the possibility of coronary occlusion is cause for concern. This can be avoided if a low implantation is performed, such that the “skirt” of the valve is low enough to avoid blocking of the coronary ostia.

Prosthetic biologic MVs are usually larger than AVs, which makes them more suitable for a trans-catheter therapy. Webb [6] taught us that a trans-venous approach with a trans-septal puncture can be catastrophic. Therefore, in both patients we

used the trans-apical approach with a 26 mm Edwards-Sapien. Implantations were relatively easy and successful and the subsequent hospital stay was uneventful. Although the implantation is not in the left ventricular outflow tract, also here, rapid pacing is crucial for stabilization of the valve during implantation. Moreover, the location of the mitral bioprosthesis ring should be clear on fluoroscopy. The implanted Edwards valve should be positioned a few millimeters inside the left ventricular aspect as shown in Figure 3.

In summary, TAVI is a promising new therapy for inoperable or high risk patients with severe AS. Published registries and randomized trials included only patients with severe AS. We contend that TAVI can be safely and successfully performed in selected inoperable and high risk patients suffering from bicuspid valve AS, pure AR, and failed aortic and mitral prosthetic valves. Off-label use of TAVI is an increasing clinical reality. Indications for TAVI need to be re-discussed and may be widened to include treatment of these additional valvular pathologies in highly selected “no-option” patients.

Corresponding author:

Dr. A. Segev

Interventional Cardiology Unit, Sheba Medical Center, Tel Hashomer 52621, Israel

Fax: (972-3) 530-5789

email: amit.segev@sheba.health.gov.il

References

1. Leon MB, Smith CR, Mack M, et al., PARTNER Trial Investigators. Transcatheter aortic-valve implantation for aortic stenosis in patients who cannot undergo surgery. *N Engl J Med* 2010; 363: 1597-607.
2. Gurvitch R, Wood DA, Tay EL, et al. Transcatheter aortic valve implantation: durability of clinical and hemodynamic outcomes beyond 3 years in a large patient cohort. *Circulation* 2010; 122 (13): 1319-27.

3. Cheung A, Webb JG, Wong DR, et al. Transapical transcatheter mitral valve-in-valve implantation in a human. *Ann Thorac Surg* 2009; 87: e18-20.
4. Webb J, Cribier A. Percutaneous transarterial aortic valve implantation: what do we know? *Eur Heart J* 2011; 32: 140-7.
5. Wijesinghe N, Ye J, Rodés-Cabau J, et al. Transcatheter aortic valve implantation in patients with bicuspid aortic valve stenosis. *JACC Cardiovasc Interv* 2010; 3: 1122-5.
6. Webb JG, Wood DA, Ye J, et al. Transcatheter valve-in-valve implantation for failed bioprosthetic heart valves. *Circulation* 2010; 121: 1848-57.
7. Gotzmann M, Mügge A, Bojara W. Transcatheter aortic valve implantation for treatment of patients with degenerated aortic bioprostheses – valve-in-valve technique. *Catheter Cardiovasc Interv* 2010; 76: 1000-6.
8. Khawaja MZ, Haworth P, Ghuran A, et al. Transcatheter aortic valve implantation for stenosed and regurgitant aortic valve bioprostheses CoreValve for failed bioprosthetic aortic valve replacements. *J Am Coll Cardiol* 2010; 55 (2): 97-101.
9. Cheung AW, Gurvitch R, Ye J, et al. Transcatheter transapical mitral valve-in-valve implantations for a failed bioprosthesis: a case series. *J Thorac Cardiovasc Surg* 2011; 141: 711-15.
10. Smith CR, Leon MB, Mack MJ, et al., PARTNER Trial Investigators. Transcatheter versus surgical aortic-valve replacement in high-risk patients. *N Engl J Med* 2011; 364: 2187-98.
11. Rajani R, Buxton W, Haworth P, et al. Prognostic benefit of transcatheter aortic valve implantation compared with medical therapy in patients with inoperable aortic stenosis. *Catheter Cardiovasc Interv* 2010; 75: 1121-6.
12. Ye J, Cheung A, Lichtenstein SV, et al. Transapical transcatheter aortic valve implantation: follow-up to 3 years. *J Thorac Cardiovasc Surg* 2010; 139: 1107-13.
13. Rodés-Cabau J, Webb JG, Cheung A, et al. Transcatheter aortic valve implantation for the treatment of severe symptomatic aortic stenosis in patients at very high or prohibitive surgical risk: acute and late outcomes of the multicenter Canadian experience. *J Am Coll Cardiol* 2010; 55: 1080-90.
14. Zahn R, Gerckens U, Grube E, et al., on behalf of the German Transcatheter Aortic Valve Interventions – Registry Investigators. Transcatheter aortic valve implantation: first results from a multi-centre real-world registry. *Eur Heart J* 2011; 32: 198-204.
15. Siu SC, Silversides CK. Bicuspid aortic valve disease. *J Am Coll Cardiol* 2010; 55: 2789-800.

Capsule

Autism and mental retardation among offspring born after in vitro fertilization

Between 1978 and 2010, approximately 5 million infants were born after in vitro fertilization (IVF) treatments. Yet there is limited information on neurodevelopment after IVF, especially after the first year of life. Sandin et al. examine the association between use of any IVF and different IVF procedures and the risk of autistic disorder and mental retardation in the offspring. Of the more than 2.5 million infants born, 30,959 (1.2%) were conceived by IVF and were followed for a mean of 10 years (SD 6). Overall, 103 of 6959 children (1.5%) with autistic disorder and 180 of 15,830 (1.1%) with mental retardation were conceived by IVF. The relative risk for autistic disorder after any procedure compared with spontaneous conception was 1.14 (95% CI 0.94–1.39, 19.0 vs. 15.6 per 100,000 person-years). The RR for mental retardation was 1.18 (95% CI 1.01–1.36, 46.3 vs. 39.8 per 100,000 person-years). For both outcomes there was no statistically significant association when restricting analysis to singletons. Compared to IVF without ICSI with fresh embryo

transfer, there were statistically significantly increased risks of autistic disorder following ICSI using surgically extracted sperm and fresh embryos (RR 4.60 [95% CI 2.14–9.88], 135.7 vs. 29.3 per 100,000 person-years); for mental retardation following ICSI using surgically extracted sperm and fresh embryos (RR 2.35 [95% CI 1.01–5.45], 144.1 vs. 60.8 per 100,000 person-years); and following ICSI using ejaculated sperm and fresh embryos (RR 1.47 [95% CI 1.03–2.09], 90.6 vs. 60.8 per 100,000 person-years). When restricting the analysis to singletons, the risks of autistic disorder associated with ICSI using surgically extracted sperm were not statistically significant, but the risks associated with ICSI using frozen embryos were significant for mental retardation (with frozen embryos, RR 2.36 [95% CI 1.04–5.36], 118.4 vs. 50.6 per 100,000 person-years); with fresh embryos, RR 1.60 [95% CI 1.00–2.57], 80.0 vs. 50.6 per 100,000 person-years).

JAMA 2013; 310: 75

Eitan Israeli