

Massive Cerebral Calcifications (Fahr's Disease) in a Patient with Systemic Lupus Erythematosus and No Major Neuropsychological Abnormality

Dusanka Martinovic-Kaliterna MD PhD, Mislav Radic MD PhD, Josipa Radic MD PhD, Vedran Kovacic MD PhD and Damir Fabijanic MD PhD

Department of Internal Medicine, Split University Hospital, Split, Croatia

KEY WORDS: Fahr's disease, systemic lupus erythematosus (SLE), neuropsychiatric abnormalities, insomnia

IMAJ 2013; 15: 654–655

Brain calcifications are uncommon findings in systemic lupus erythematosus; if present they are usually accompanied by clinical signs of cerebral lupus [1]. Fahr's disease refers to a rare syndrome characterized by abnormal symmetric and bilateral intracranial calcifications in certain areas of the brain. Most common sites are the basal ganglia and dentate nuclei. The condition is often asymptomatic and discovered on brain imaging [2]. Symptoms of the disorder may include deterioration of motor function, psychosis, dementia, seizures, headache, dysarthria, spasticity and spastic paralysis, eye impairments, and athetosis. Although the most common findings in Fahr's disease are motor deficits, 40% of patients have primarily cognitive and other psychiatric symptoms. Fahr's disease can also include symptoms characteristic of Parkinson's disease such as tremor, muscle rigidity, mask-like facial appearance, shuffling gait and "pill-rolling" motion of the fingers. These generally occur later in the development of the disease. More common symptoms include dystonia and chorea. Age of onset is typically in the fifth or sixth decade of life, although it can occur at any time from childhood through adolescence to adulthood.

The clinical diagnosis of Fahr's disease is a combination of clinical features, brain imaging findings, and exclusion of other causes of intracranial calcification. Clinical symptoms are important because calcification of the basal ganglia may be viewed as an incidental finding. Headache, vertigo, movement disorders, paresis, stroke-like events, cognitive impairment, psychiatric disorders, pyramidal signals, and seizures are the most common manifestations of basal ganglia calcification.

In this article we discuss the possible role of Fahr's disease in a lupus patient with massive cerebral calcifications without any signs of cerebral lupus or its specific neurological manifestations. The discrepancy between clinical presentation and computed tomography imaging findings is also presented.

PATIENT DESCRIPTION

Our patient was a 65 year old woman with SLE, cerebral calcifications and insomnia. She was diagnosed with SLE in 1990 at age 48, based on photosensitivity, malar rash, polyarthralgia, lymphopenia ($860/\text{mm}^3$), positive antinuclear antibody titer (1:1.280) and anti-double stranded DNA (16.0 IU/ml). Her clinical condition improved rapidly upon treatment with a combination of hydroxychloroquine and low dose oral steroids, which effectively controlled the disease. There was no history of SLE-induced central nervous system disorder.

In January 2007 she presented to the clinic with sleeping difficulties. A

serological workup revealed normal antiphospholipid antibodies (anticardiolipin immunoglobulin G, immunoglobulin M and lupus anticoagulant) and anti-ribosomal P antibody titers. The patient had no history of depression, alcohol or drug abuse. There was no family history of dementia, psychiatric illness, neurological illness, or Fahr's disease.

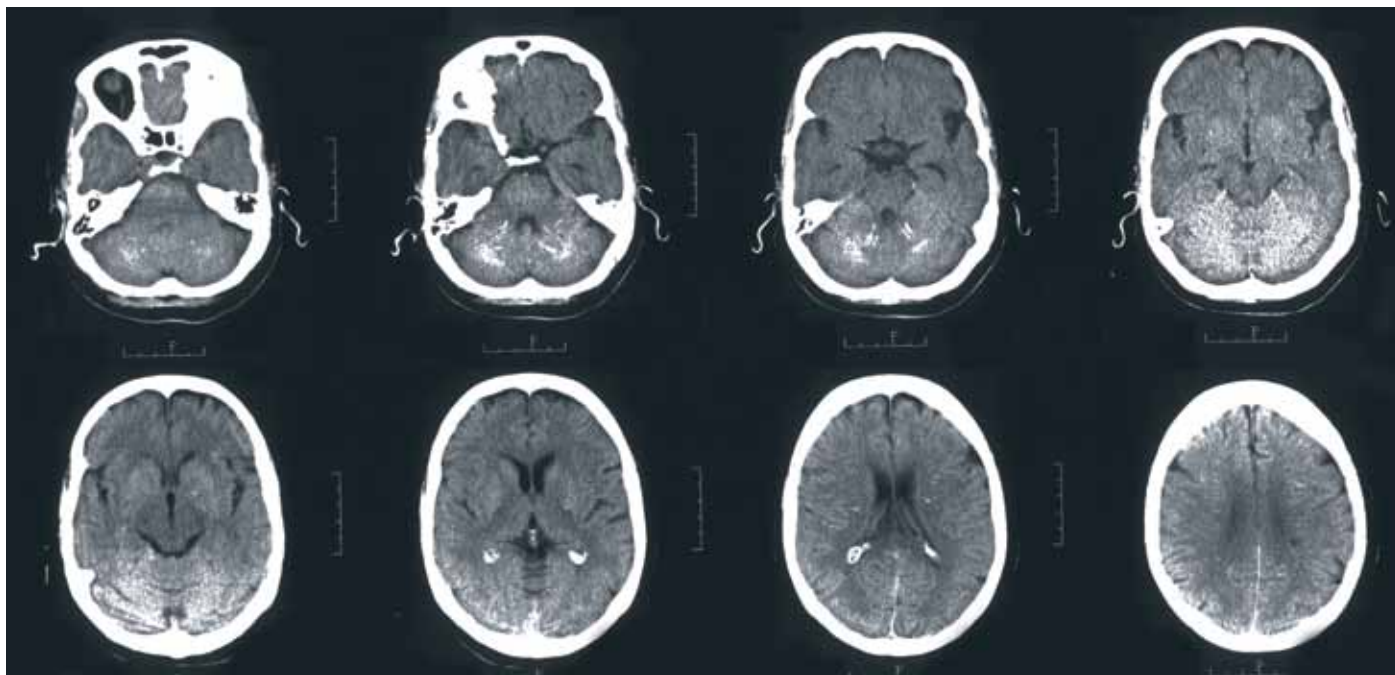
During the psychiatric examination she complained of insomnia and mild depression. An electroencephalogram did not show any abnormality and cerebrospinal fluid analysis was normal. CT scan revealed bilateral symmetric intracranial calcifications in the cerebrum, basal ganglia, periventricular white matter and cerebellum; there were no signs of cerebral atrophy or ischemia. These massive calcifications have been found compatible with Fahr's disease [Figure].

The patient did not exhibit any major neurological abnormality. Laboratory findings, including serum calcium, phosphate level and parathyroid hormone, were normal. No underlying cause for the bilateral calcifications was found. The absence of antiphospholipid completion antibodies and other signs of lupus activity did not support the diagnosis of cerebral lupus. After all diagnostic procedures were completed and cerebral lupus excluded, zolpidem was prescribed.

She was seen again in June 2007 and did not complain of insomnia or other neurological or neuropsychiatric manifestations.

SLE = systemic lupus erythematosus

CT scan showing bilateral symmetric calcifications in the dentate nuclei of the cerebellum, basal ganglia and periventricular white matter of the cerebrum



COMMENT

Fahr’s disease is a rare condition with unknown prevalence and typical presentation in middle age [2]. Both sporadic and hereditary types of Fahr’s disease have been documented in the literature [2]. The clinical expression of Fahr’s disease varies greatly and includes psychiatric disorders, epileptic seizures, extrapyramidal syndrome, and different neurological abnormalities. The paraventricular calcifications described in our patient are rare and were previously reported only in two patients with SLE and cerebral lupus [3].

Filloux et al. [4] also discussed the possible role of Fahr’s disease in an elderly lupus patient with progressive cognitive impairment, dementia and tetraplegia but

no signs of cerebral lupus. In the literature we found only one report of isolated neurological abnormality (anosmia) in a lupus patient with brain calcifications and no clinical manifestations of cerebral lupus [5].

The patient described here did not have a clinical history or criteria of cerebral lupus and had only minor depressive symptoms and insomnia despite massive cerebral calcifications. Since these calcifications have been found compatible with Fahr’s disease, we believe there is a possible role of Fahr’s disease in a lupus patient with minor neuropsychiatric manifestation such as insomnia. In summary, to the best of our knowledge this is the first case of massive cerebral calcifications in a patient with SLE without major neuropsychiatric abnormalities.

Corresponding author:

Dr. M. Radić
 Šišgoričeva 20/II, 21 000 Split, Croatia
Phone/Fax: (385-21) 557-497
email: mislavradic@gmail.com

References

1. Raymond AA, Zariah AA, Samad SA, Chin CN, Kong NC. Brain calcification in patient with cerebral lupus. *Lupus* 1996; 5: 123-8.
2. Benke T, Karner E, Seppi K, Delazer M, Marksteiner J, Donnemiller E. Subacute dementia and imaging correlates in a case of Fahr’s disease. *J Neurol Neurosurg Psychiatry* 2004; 75: 1163-5.
3. Daud AB, Nuruddin RN. Solitary paraventricular calcification in cerebral lupus erythematosus: a report of two cases. *Neuroradiology* 1988; 30: 84-5.
4. Filloux V, Marotte H, Miossec P. Cerebral calcifications in an elderly lupus patient. *Ann Rheum Dis* 2003; 62: 283-4.
5. Stuart BM, Gregson NA. Cerebral calcification in a patient with systemic lupus erythematosus and a monoclonal Ig reactive with glial fibrillary acidic protein. *Br J Rheumatol* 1988; 37: 1355-7.

“You can out-distance that which is running after you, but not what is running inside you”

Rwandan proverb

“I am, indeed, a king, because I know how to rule myself”

Pietro Aretino (1492-1556), Italian author, playwright, poet and satirist who wielded immense influence on contemporary art and politics