



Avascular Necrosis of the Sacroiliac Joint In a Patient with Gaucher Disease

Dvora Aharoni MD¹, Sergey Mekhmandarov MD⁴, Menachem Itzchaki MD², Nurith Hiller MD³ and Deborah Elstein PhD¹

¹Gaucher Clinic and Departments of ²Orthopedics and ³Radiology, Shaare Zedek Medical Center, Jerusalem, and ⁴Department of Nuclear Medicine, Hillel Yaffe Medical Center, Hadera, Israel

Key words: Gaucher disease, sacroiliac joint, avascular necrosis, magnetic resonance imaging

IMAJ 2001;3:767-768

Gaucher disease, the most prevalent lysosomal storage disorder, is caused by a deficiency of β -glucocerebrosidase and is characterized by multisystemic accumulation of substrate in the cells of monocyte-macrophage lineage, known as "Gaucher" cells. Although the visceral and hematological signs and symptoms of Gaucher disease may be severe and even life threatening, the involvement of the bones in many cases causes the most disability and the greatest reduction in quality of life. Bone lesions range from the asymptomatic failure to remodel (Erlenmeyer flask deformity) to medullary and corticocancellous infarcts, diffuse osteopenia, localized lytic lesions, fractures, and osteomyelitis, all with varying degrees of pain [1].

Avascular necrosis is a common phenomenon, but even among patients with Gaucher disease, AVN of the sacroiliac joint is very rare. We describe a case of AVN of the sacroiliac joint documented by bone scintigraphy and magnetic resonance imaging.

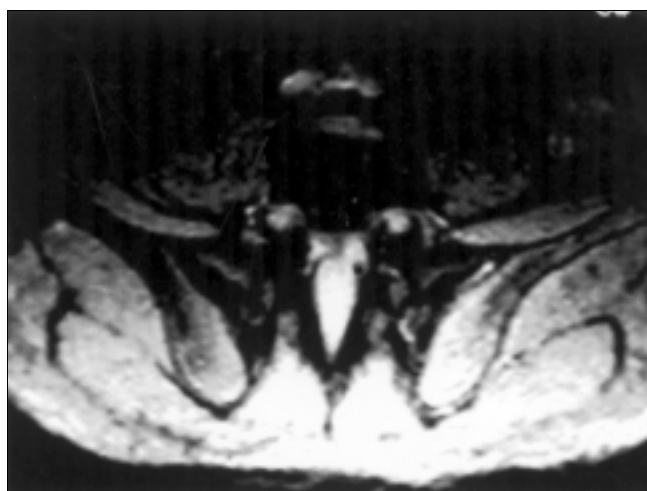
Patient Description

A 22 year old male soldier of Ashkenazi Jewish ancestry presented to our referral clinic for evaluation of acute pain in the left hip and buttock following his hospitalization elsewhere with the presumptive diagnosis of sacroileitis. He was

diagnosed at birth as having Gaucher disease because of a family history. The patient, as well as three siblings with the same genotype, N370S/N370S (1226G/1226G), had been asymptomatic since birth. Prior to his presentation he had been serving in a combat unit where he was required to carry heavy equipment on his back. There was no other relevant medical history. Two weeks before coming to our clinic, he experienced severe pain in the left buttock and hip, radiating to the groin and left knee, and he could not walk. He was hospitalized elsewhere. There was no fever, swelling or redness locally, and vital signs were all within normal limits. No organomegaly was found, but there was limited range of motion in the left hip. Laboratory find-

ings included: hemoglobin 13.5 g/dl, white blood cells 8,200/ μ l, platelets 120,000/ μ l, and high erythrocyte sedimentation rate. Plain X-rays and computerized tomography of the lumbar spine and pelvis were normal. Bone scintigraphy showed a photopenic area in the left sacroiliac joint. Owing to the presumptive diagnosis of sacroileitis, treatment with a single intravenous injection of cortisone and bed-rest alleviated some of the pain and symptoms.

One week later, MRI of the pelvis revealed an intense signal in the T1- and T2-weighted sequence in the iliac part of the left sacroiliac joint [Figure]; there was no abnormality in the left femoral head, hip joint, or lumbar spine. Taken together, the findings of various imaging



MRI of the sacroiliac joint taken at presentation, showing hyperintense signaling in the left half of the sacroiliac joint.

AVN = avascular necrosis

modalities were compatible with AVN of the iliac part of the left sacroiliac joint in class B according to the Mitchell classification [2]. After 3 months with rest, no limitation of movement and almost no pain were noted, and the patient was advised to return to the army.

Eighteen months later, a bone scan continued to show a marked difference between the parts of the sacroiliac joint, interpreted as a bone infarction in stages of repair. The MRI showed decreased signal intensity on T1- and increased signal intensity on the T2-weighted images at the iliac portion of the left sacroiliac joint with islands of bright signal on the T1- and low signal on the T2-weighted images within the affected area, consistent with AVN class C by the Mitchell classification, and foci of necrotic bone.

Comment

AVN of the large joints may be due to a multiplicity of causes: among them trauma, steroid treatment, infection, collagen disease, vasculitis, sickle cell anemia, as well as Gaucher disease and other diseases. The most common site in all these entities is the hip joint. The sacroiliac joint is a very rare nidus, and almost unknown. Among more than 400 patients in our Gaucher clinic, approximately one-eighth have AVN of at least one hip joint, and 7 patients have AVN of a shoulder or knee joint. This soldier is the first patient with AVN of the sacroiliac joint.

We hypothesize that the unusual location of AVN in our patient was the

result of multiple, subliminal, traumatic events, possibly caused by lifting heavy weights and/or jumping as a paratrooper. In the literature there is only one comparable case of AVN of the sacroiliac joint that is well documented with scintigraphy and MRI, and that also occurred in a patient with Gaucher disease [3]. This latter patient, however, had other manifestations of Gaucher disease as well as a family history of AVN of the hip joint, whereas our patient is completely asymptomatic as are all of his siblings. Given the history of repeated trauma, it was deemed that enzyme replacement therapy [4] was not warranted as prophylaxis for possible skeletal involvement in the future.

As seen in these cases, AVN on bone scintigraphy appears as a cold photopenic area in the early stage, indicative of interrupted blood supply. At later stages, capillary infiltration and new bone synthesis produce an increased uptake. MRI is more sensitive than scintigraphy: the combination of signal intensities of T1- and T2-weighted images reflects the degree of involvement. On MRI, normal marrow has high signal intensity on T1- and intermediate signal intensity on T2-spin echo sequences because of abundant fat. In Gaucher disease, the marrow typically has lower signal intensity on both sequences because of diffuse replacement of fatty marrow by Gaucher cells. MRI is the best diagnostic method for depicting AVN at an early stage, especially in Gaucher patients [5], and for differentiating AVN from other non-AVN diseases of bone. In cases of AVN, in

contrast to the low intensity expected because of Gaucher cell infiltration, there is high intensity of signal in the T2-weighted images [2]. Thus, it was clear that this soldier had, with slight albeit continual trauma, incurred AVN at the rare sacroiliac site.

References

1. Elstein D, Itzchaki M, Mankin HJ. Skeletal involvement in Gaucher disease. *Clin Haematol* 1997;10:793-816.
2. Mitchell DG, Rao VM, Dalinka MK, Spritzer CE, Alavi A, Steinberg ME, Fallon M, Kressel HY. Femoral head avascular necrosis: correlation of MR imaging, radiographic staging, radionuclide imaging and clinical findings. *Radiology* 1987;162:709-15.
3. Bisagni-Faure A, Dupont AM, Chzerain P, Job-Deslandre C, Chevrot A, Menkes CJ. Magnetic resonance imaging assessment of sacroiliac joint involvement in Gaucher disease. *J Rheumatol* 1992;19:1984-7.
4. Barton NW, Brady RO, Dambrosia JM, Di Bisceglie A, Doppelt SH, Hill SC, Mankin HJ, Murray GJ, Parker RI, Argoff CE, et al. Replacement therapy for inherited enzyme deficiency: macrophage-targeted glucocerebrosidase for Gaucher's disease. *N Engl J Med* 1991;324:1464-70.
5. Rosenthal DI, Scott JA, Barranger J, Mankin HJ, Saini S, Brady TJ, Osier LK, Doppelt S. Evaluation of Gaucher disease using magnetic resonance imaging. *Am J Bone Joint Surg* 1986;68:802-8.

Correspondence: Dr. D. Elstein, Gaucher Clinic, Shaare Zedek Medical Center, P.O. Box 3235, Jerusalem 91031, Israel. Phone: (972-2) 655-5143, Fax: (972-2) 651-7979, email: gaucher@md.huji.ac.il