

Malignant Lymphoma in Primary Sjogren's Syndrome

Michalis Voulgarelis MD and Haralampos M. Moutsopoulos MD FACP FRCP (Edin)

Department of Pathophysiology, Medical School, National University of Athens, Athens, Greece

Key words: Sjogren's syndrome, lymphoma, lymphoproliferation, predictive factors, pre-lymphomatous stage

Abstract

Sjogren's syndrome is a chronic inflammatory process involving primarily the exocrine glands. Its association with lymphoma is well documented. A low grade marginal-zone lymphoma related to mucosa-associated lymphoid tissue is the commonest lymphoid neoplasia in Sjogren's syndrome. We review the literature and comment on the molecular, clinical, histopathologic and therapeutic aspects of these tumors in Sjogren's syndrome.

IMAJ 2001;3:761-766

Sjogren's syndrome is an autoimmune epithelitis characterized by lymphocytic infiltration of exocrine glands together with polyclonal B cell activation, as illustrated by the presence of multiple circulating autoantibodies against organ- and non-organ-specific autoantigens [1]. The clinical spectrum of primary SS extends from autoimmune exocrinopathy to a systemic disease affecting the musculoskeletal, pulmonary, renal, gastrointestinal and vascular systems.

SS patients have a greater tendency to develop a lymphoid malignancy. The spectrum of lymphoproliferation extends from an increased frequency of circulating monoclonal immunoglobulins and free light-chains, the presence of mixed monoclonal cryoglobulinemia, increased levels of circulating CD5-positive B cells, to an increased frequency of malignant non-Hodgkin's lymphoma [2,3]. By the term pseudolymphoma, Talal et al. [4] implied an intermediate state between autoimmunity and malignant lymphoma. Pseudolymphoma probably corresponds to what we today call low grade B cell lymphoma. Malignant lymphoma was first reported in 1963 in patients with SS [5]. The risk of NHL is estimated to be 44 times greater in SS patients than in a normal population [6]. Several subsequent reports supported the association of lymphoma with SS and recognized NHL as the major complication in the progression of the disease [7-9].

Pathogenesis: molecular aspects

From polyclonal B cell activation to monoclonal expansion of B lymphocytes

It has been demonstrated over the past few years that the essential process of the transition from the autoimmune state

to NHL is monoclonality. The benign myoepithelial sialadenitis lesions characteristic of SS are composed of CD4 T cell lymphocytes [10] that secrete interleukin 2 and interferon-gamma [11,12] and of B cell lymphocytes that are often oligoclonal with a risk of progression to B cell lymphoma. Immunophenotyping and immunogenotyping techniques have been used in tissue samples from SS patients, showing oligoclonal or monoclonal B cell expansion in some of the cases [13,14] [Figure 1]. This process arises mainly from the affected exocrine glands but may also arise from visceral organs and lymph nodes.

However, monoclonal expansion is not necessarily malignant lymphoma. The question of whether monoclonal B cell populations in early MESA represent lymphoma or more benign types of expansion is controversial. The presence of distinct clones in different biopsies of salivary glands from the same patient indicates that some MESA-associated clones have not yet evolved to malignant lymphoma [15]. This could be interpreted as a possible suppression of the monoclonal B cell expansion by endogenous immune mechanisms. However, SS patients exhibiting monoclonal immunoglobulin gene rearrangement have a high risk of lymphoma development, and the risk of malignant transformation is higher among these patients in whom identical B cell clones can be detected in different tissues at different times [16]. Although there is still a possibility that these clones represent early smoldering lymphoma, clones in

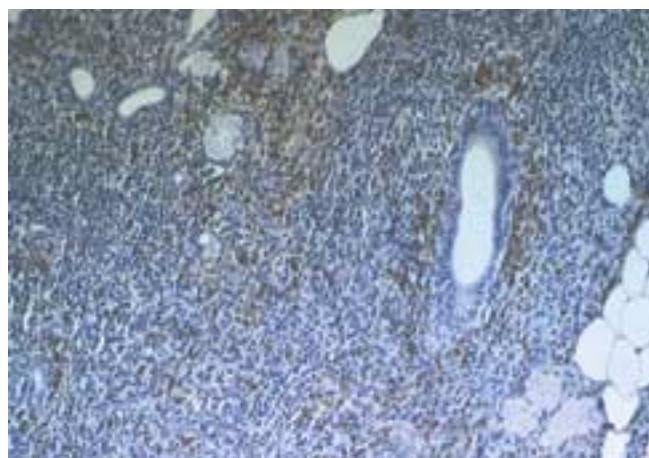


Figure 1. A minor salivary gland biopsy stained with goat anti-human k light-chains, using the avidin-biotin peroxidase method, showed heavy infiltration by B lymphocytes containing exclusively k light-chains.

SS = Sjogren's syndrome

NHL = non-Hodgkin's lymphoma

MESA = myoepithelial sialadenitis

benign MESA or early low grade lymphoma behave clinically in an indolent course and remain localized without evidence of other spread.

Mechanisms of lymphoproliferation

The transition of reactive MESA from monoclonality to monoclonal lymphoma is generally considered to represent a multi-step process but it is poorly understood. There has been speculation that chronic stimulation by exoantigen or autoantigen plays an important role in the development of these tumors, by driving the proliferation of specific B cells and by increasing the frequency of their transformation [17].

Among SS patients the idiotype repertoire of rheumatoid factor is highly restricted (i.e., the 17.109 idiotype) because of the frequent utilization of the germline-encoded V_k III gene segment [18]. Furthermore, B cells expressing cell surface RF (i.e., encoded by Hum kv325) are frequently detected in the salivary glands [19,20]. This suggests that the clonal expansion in the salivary glands may derive from B cells bearing immunoglobulins of a specific cross-reactive idiotype.

Antigen selection of specific B cells for transformation was suggested by previous research of salivary gland mucosa-associated lymphoid tissue lymphomas, in which three of the five cases use the 51p1 VH and HumKv 325 VL genes that encode the G6 and 17.109 idiotypes respectively [21]. Additionally, analysis of the IgVH gene of 11 distinct MESA-associated clones in sequential biopsies of different patients showed that 8 were derived from a V1-69 VH gene segment, while the other 3 were derived from a V3-7 VH gene segment. The marked VH gene restriction along with similar amino acid sequence motifs in the complement-determining region (CDR3) suggest that MESA-associated clones even from different patients may bind the same or similar antigens and are selected from clonal expansion. In addition, the high rate of ongoing VH gene hypermutation in some of the cases and the counterselection of replacement mutations in the framework regions further suggest that immunoglobulin is an important factor in the development and expansion of MESA-associated clones [15].

The binding specificity of the surface immunoglobulin from these B cells is unknown. It has been speculated that the antigenic peptides may derive from endogenous autoantigens or from exogenous agents including Epstein-Barr virus-encoded antigens. Previous studies have shown that these lymphomas are not associated with viruses such as hepatitis C virus, Epstein-Barr virus, human herpes virus 8, or human T lymphotropic virus-1 [22]. There is a strong possibility that MESA-associated clones produce immunoglobulins having RF activity. This could be explained by the frequent occurrence of mixed monoclonal cryoglobulinemia in SS patients and by the fact that IgVH genes of MESA-associated clones share the same restriction repertoire occurring in RF production. A recent study

suggests that salivary gland lymphoma in patients with SS frequently develops from RF-producing B cells [23]. In this study a model for the increased frequency of lymphomas involving specific RF B cells in SS patients may include chronic stimulation by IgG or more likely by IgG complexed to auto or exoantigens. It has been proposed that persistent antigenic stimulation of RF B cells within the salivary glands gives rise to clonal expansion and increases the risk of occurrence of an oncogenic event. If this is the case, then most of the SS lymphomas should have a surface immunoglobulin with RF reactivity.

It is unlikely that antigenic stimulation by itself would generate a clonal population behaving in a malignant fashion. Additional oncogenic events are usually required before clones become malignant and are capable of widespread dissemination and growth, such as inactivation of tumor suppression genes and/or activation of proto-oncogenes.

In contrast of other types of NHL where microsatellite instability seems to be absent, the replication error phenotype (REP+) appears to be a common genetic feature of MALT lymphomas, detected in approximately 50% of cases, and perhaps relates to the accumulation of genetic aberrations such as p53 mutations [24]. P53, a transcription factor, acts as a cell cycle checkpoint protein and induces cell cycle arrest in the late G1 phase or apoptosis after DNA damage. The inactivation of the p53 gene at the gene level can be caused by mutation, deletion and rearrangement. P53 inactivation, abolishing its tumor-suppressor activity, is the most common event in human malignancies. Thus, partial loss of p53 tumor-suppressor activity may play an important role in the development of low grade MALT lymphoma where complete loss (mutation of one allele and loss of the other) is associated with high grade transformation [25]. In at least some cases, mutations of the p53 gene are accompanied by over-expression of the p53 protein and in half of the cases by detection of serum anti-p53 antibodies [26]. Anti-p53 antibodies were detected at a high titer in the sera of 2 of 14 tested SS patients with low grade lymphoma [22]. Sequence analysis of the p53 gene in five SS patients with low histological grade lymphomas revealed two novel mutations of exon 5. These mutations are single-base substitutions and appear to be functional since exon 5 is included in the coding region of the p53 gene. The loss of mutant p53 tumor-suppressor activity may lead to the checkpoint failure at the level of the cell cycle, followed by uncontrolled cell proliferation. This finding indicates a probable role of this tumor-suppressor gene as a mechanism for lymphoma development in SS [27].

For several types of B cell lymphomas, chromosomal translocations into immunoglobulin heavy-chain gene segments have been described, such as translocation (14;18) in follicular lymphomas. The translocation juxtaposes the bcl-2 gene with immunoglobulin heavy-chain locus, leading to

RF = rheumatoid factor

MALT = mucosa-associated lymphoid tissue

deregulation of apoptosis and increased B cell survival, and may contribute to increased chance of lymphomatogenesis. These translocations probably reflect an error in the V(D)J recombination, a molecular process that is believed to be restricted to B cell precursors in the bone marrow but may occasionally take place in the germinal center. It is possible that the microenvironment of ectopic germinal centers in the salivary glands of SS patients, where B cell lymphocytes undergo intense proliferation, hampers variable-region gene recombination; thus failures in the control of this process appear to contribute to neoplastic transformation [28]. Pisa et al. [7] found the t(14;18) translocation in five of seven SS-associated lymphomas. Of particular interest was the finding that pre-lymphoma biopsies from seven SS patients who subsequently developed lymphoma lacked detectable t(14;18) translocation even though they exhibited oligoclonal rearrangements of their immunoglobulin genes [7].

Although some of the translocations of oncogenes or mutations of anti-oncogenes are detected in SS-associated lymphomas, recurrent molecular abnormalities that could explain the pathogenesis of these lymphomas have not been found.

Predictive factors of lymphoma development

Knowing that SS patients are at higher risk of developing lymphoma, several investigators have attempted to establish predictive factors for this progression. Although some clinical parameters may herald the imminent onset of lymphoma, few reliable markers are available to predict this progression [Table 1].

In 1971 Anderson and Talal [29] showed that a decrease in the level of serum immunoglobulin and the disappearance of RF occurred at the time of progression to lymphoma. Kassan et al. [6] showed that patients with lymphadenopathy, splenomegaly, parotid gland enlargement and previous low dose irradiation or chemotherapy had an increased risk of lymphoma development. In a study performed in our department [30] the presence of mixed monoclonal cryoglobulinemia proved to be the most significant factor in predicting the risk of lymphoma development. The cross-reactive idiotypes 17.109 and G6 are also correlated with lymphoma development. Also, the evidence of monoclonal paraproteinemia and urinary free light-chains may identify patients who are at particular risk for later lymphoma development [31]. Another study found that lymphoproliferative disorders were associated with the presence of palpable

purpura, low C4 and mixed monoclonal cryoglobulinemia. Patients without any of these factors had a negligible risk of developing lymphoma during the follow-up [32]. Other researchers have suggested that leg ulcers, which may also be manifestations of vasculitis, are predictive of lymphoma development [9]. All the above suggests that patients with these risk factors constitute a separate subgroup that should be monitored and managed more closely than other SS patients.

Unfortunately the characterization of earlier stages of lymphoproliferation in SS is still poorly defined. B cell clonal expansion is an early event in the course of SS, whose stages may range from clearly benign lymphoid infiltrates to early malignancy. The risk of developing extralymphatic lymphoma is closely related to the presence of either or both broad strands of monoclonal B cells between the MESA and the presence of monotypic immunoglobulin expression by lymphoid cells or plasma cells as detected by immunoperoxidase [33]. In contrast to the detection of monoclonality by immunoglobulin light-chain expression, detection of B cell clones in salivary gland lesions by Southern blot or polymerase chain reaction analysis of immunoglobulin gene rearrangement has not proved to be a reliable predictor of clinical behavior in MESA [15,33]. Thus, it seems that molecular genetic analysis has little or no practical value in the clinical diagnosis of salivary gland lymphoma in a setting of MESA. The different types of B cell clonal expansion (oligoclonal or monoclonal, smaller or larger, fluctuating or established, localized or disseminated) may imply a different risk of lymphoma progression [16]. Taking together all these, the focus on pre-lymphomatous stages are crucial to better understand the entire lymphomatogenesis in SS.

Clinical aspects

Pathology

The prevalence of NHL in SS patients is 4.3% and usually develops later in the illness. The median time from SS diagnosis to lymphoma diagnosis is 7.5 years [6,34]. Various histologic subtypes of NHL for patients with SS have been described in the literature, including follicular center lymphoma, lymphoplasmacytoid, diffuse large B cell lymphoma, and especially MALT lymphomas [6,22,34,35]. However, the majority of lymphomas in SS are marginal-zone B cell lymphomas [22,34,36] [Figure 2]. This term encompasses MALT lymphoma and monocytoid B cell lymphomas, the latter being the nodal counterpart of the former. These tumors have sufficient morphologic, immunophenotypic and clinical similarity to suggest that they are morphologic manifestations of the same neoplastic process [36,37]. It is worth noting that cases classified in the past as immunocytomas probably belong to the MZL entity. Neoplastic marginal-zone cells are expected to retain the homing pattern of their normal precursors, which explains the diverse distribution of lymphomas of this type [22,38]. These lymphomas arise frequently in mucosal extranodal sites as well as in extranodal

Table 1. Predictors of lymphoma development

Clinical	Serological
Persistent enlargement of parotid glands	Low levels of C4
Splenomegaly	Mixed monoclonal cryoglobulinemia
Lymphadenopathy	Cross-reactive idiotypes (17.109, G6)
Palpable purpura	
Leg ulcers	

MZL = marginal-zone B cell lymphomas

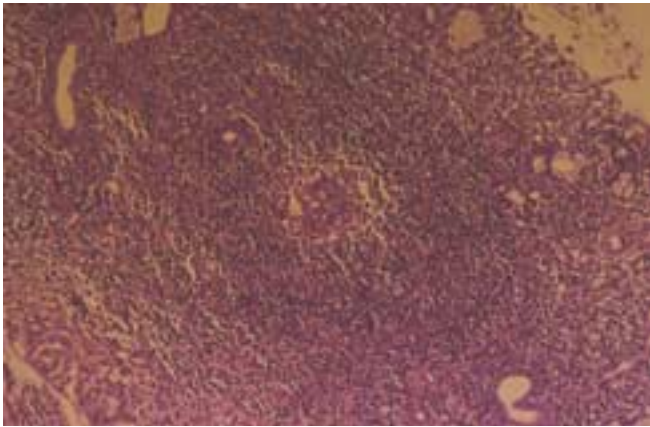


Figure 2. A low grade B cell lymphoma of marginal-zone/MALT type involving the salivary gland. Diffuse sheets of lymphoid cells surround and extend away from epimyoepithelial island (hematoxylin & eosin, x 250).

Table 2. Clinical characteristics of SS patients with low-grade MZL

	Positive(%)
Performance status (Grade 0-1)	85
B symptoms	15
Clinical stage (localized disease)	62
Involvement	
Nodal	15
Extranodal involvement	46
Both	39
Splenomegaly	7
Bone marrow infiltration	7

non-mucosal sites; most of these sites have in common the presence of epithelium, usually columnar, suggesting a homing property of these cells to epithelia rather than to mucosa [38]. In our study [34], the MZL in SS patients were primary low grade and localized (stage I and II) with extranodal manifestations [Table 2]. The salivary glands are the most common site but other extranodal sites are also involved, such as stomach, nasopharynx, skin, liver, kidney and lung. Presenting symptoms are caused by major gland enlargement, mainly in the bilateral parotid gland. Furthermore, the clinical picture in these patients is not characterized by the presence of B symptoms (fever, night sweats and weight loss), while although the performance status is particularly good. Lymph node involvement is common but is rarely seen exclusively. In disseminated disease, usually more than one extranodal site is involved, while bone marrow infiltration is very rare. This suggests that while salivary glands in SS patients are the most common initial site of B cell neoplastic transformation, other MALT sites, lymph nodes and bone marrow are also identified as initial sites of transformation. Non-exocrine manifestations occurring more often than in the general SS populations are skin vasculitis and peripheral

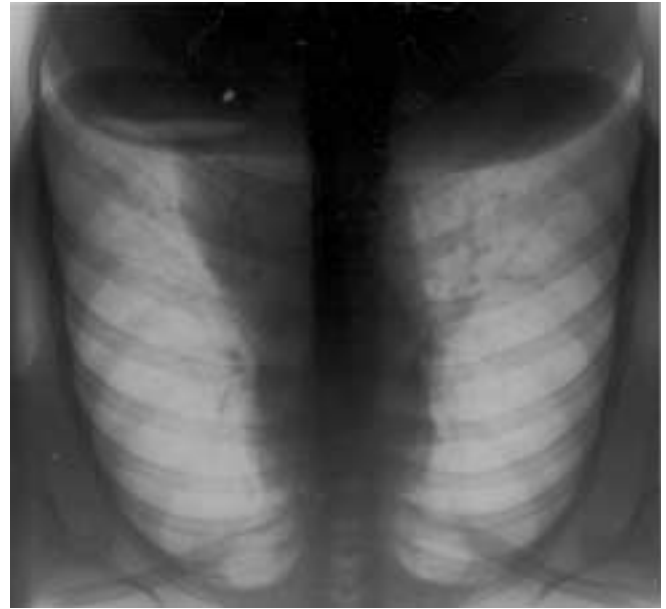


Figure 3. Chest X-ray of a patient with SS showing a mediastinal lymphadenopathy. Lymph node biopsy revealed a high grade diffuse, large B cell lymphoma.

nerve involvement. Among the hematologic and serologic parameters, anemia, lymphopenia, monoclonal immunoglobulin and cryoglobulinemia are particularly frequent in these patients.

Lymphoma may remain localized for many years and may undergo spontaneous remissions in the absence of therapy [34]. The observed regression is frequently regional and not all involved sites necessarily regress. Approximately 10% of patients with NHL have multiple histologic types of lymphoma (discordant lymphoma) identified in the biopsy tissues taken during the staging evaluation [39]. In our study we identified discordant lymphomas in SS patients, and in these cases the prognosis is the same as for the high grade component [34].

Lymphomas in SS patients tend to evolve toward a less differentiated cell type in some cases. Most high grade lymphomas in salivary glands are diffuse large B cell lymphomas. Rare cases of peripheral T cell, lymphoblastic and Burkitt-like lymphomas have been reported. During transformation the clinical picture is characterized as changing from nodal and extranodal dissemination [34] [Figure 3]. It is not known how many of the diffuse large B cell lymphomas arise from pre-existing MALT lymphomas and how many are of the nodal type or represent transformation of follicular lymphomas. Immunohistochemical, karyotypic and genotypic studies have provided convincing proof that the supervening large-cell lymphomas arise from the same clone as the low grade lymphomas [40]. Thus, the majority of the high grade lymphomas in SS patients may represent blastic variance to either marginal-zone B cell or follicular center cell lymphomas.

Therapy and prognosis

As the histologic grade is a very important prognostic factor for overall survival, the treatment of SS-associated NHL depends on the histologic grade of the lymphoma [34]. The low grade MZL has a tendency to be localized at diagnosis and to be curable with local therapy (involved-field radiotherapy or surgical removal). In our study the median overall survival of patients with low grade lymphomas is 6.3 years and is no different in treated and untreated patients [34]. Thus, in patients with localized low grade lymphoma affecting exocrine glands, a wait and watch policy should be taken, and if lymphoma is disseminated the patients may be treated with single-agent chemotherapy.

In contrast, combined chemotherapy is recommended in patients with low grade lymphoma transforming to high grade, and for those with high grade lymphoma. Over the last 15 years, a number of aggressive induction regimens have been evaluated in a pilot single institution study that included patients with high grade lymphomas. However, when these regimens has subsequently compared with cyclophosphamide, doxorubicin, vincristine and prednisone (CHOP) in large randomized trials, patients treated with CHOP had a comparable complete remission rate and overall survival. Consequently, the majority of patients with aggressive NHL in SS receives an anthracycline-containing regimen such as CHOP. Unfortunately, the median survival is estimated to be only 1.8 years in these patients. The presence of B symptoms and a large tumor diameter (7 cm) are additional independent risk factors for death [34]. We are unable as yet to identify clinical features at the initial presentation that predispose the patients to histologic progression, and there are no data that address the efficacy of treatment in presenting high grade transformation.

Conclusion

Sjogren's syndrome, at the crossroads of autoimmune disease and lymphoma malignancy, is a powerful model for the potential insight into the pathogenetic mechanisms responsible for lymphoma development.

References

1. Tapinos NI, Polihronis M, Tzioufas AG, Moutsopoulos HM. Sjogren's syndrome. Autoimmune epithelitis. *Med Adv Exp Biol* 1999;455:127-34.
2. Valesini G, Priori R, Bavoillot D, Osborn J, Danieli MG, Del Papa N, Gerli R, Pietroggrand M, Sabbadini MG, Silvestris F, Valsecchi L. Differential risk of non-Hodgkin's lymphoma in Italian patients with primary Sjogren's Syndrome. *J Rheumatol* 1997;24:2376-80.
3. Youinou P, Mackenzie L, le Masson G, Papadopoulos NM, Jouquan J, Pennec YL, Angelidis P, Katsikis P, Moutsopoulos HM, Lydyard PM. CD5-expressing B lymphocytes in the blood and salivary glands of patients with primary Sjogren's Syndrome. *J Autoimmun* 1988;1:185-94.
4. Talal N, Sokoloff L, Barth WF. Extrasalivary lymphoid abnormalities in Sjogren's syndrome (reticulum-cell sarcoma, "pseudolymphoma," macroglobulinemia). *Am J Med* 1967;43:50-65.
5. Bunim JJ, Talal N. Development of malignant lymphoma in the course of Sjogren's syndrome. *Trans Assoc Am Physicians* 1963;76:45-56.
6. Kassin SS, Thomas TL, Moutsopoulos HM, Hoover R, Kimberly RP, Budman DR, Costa J, Decker JL, Chused TM. Increased risk of lymphoma in sicca syndrome. *Ann Intern Med* 1978;89:888-92.
7. Pisa EK, Pisa P, Kang HI, Fox RI. High frequency of t(14;18) translocation in salivary gland lymphomas from Sjogren's syndrome patients. *J Exp Med* 1991;174:1245-50.
8. Pariente D, Anaya JM, Combe B, Jorgensen C, Emberger JM, Rossi JF, Sany J. Non-Hodgkin's lymphoma associated with primary Sjogren's syndrome. *Eur J Med* 1992;1:337-42.
9. Sutcliffe N, Inanc M, Speight P, Isenberg D. Predictors of lymphoma development of primary Sjogren's syndrome. *Semin Arthritis Rheum* 1998;28:80-7.
10. Adamson TC, Fox RI, Frisman DM, Howell FV. Immunohistologic analysis of lymphoid infiltrates in primary Sjogren's syndrome using monoclonal antibodies. *J Immunol* 1983;130:203-11.
11. Fox RI, Kang HI, Ando D, Abrams J, Pisa E. Cytokine mRNA expression in salivary gland biopsies of Sjogren's syndrome. *J Immunol* 1994;152:5532-41.
12. Boumba D, Skopouli FN, Moutsopoulos HM. Cytokine mRNA expression in the labial salivary gland tissues from patients with primary Sjogren's syndrome. *Br J Rheumatol* 1995;34:326-33.
13. Freimark B, Fantozzi R, Bone R, Bordin G, Fox R. Detection of clonally expanded salivary gland lymphocytes in Sjogren's syndrome. *Arthritis Rheum* 1989;32:859-69.
14. Moutsopoulos HM, Tzioufas AG, Bai MK, Papadopoulos NM, Papadimitriou CS. Association of serum IgMk monoclonicity in patients with Sjogren's syndrome with an increased proportion of k positive plasma cells infiltrating the labial minor salivary glands. *Ann Rheum Dis* 1990;49:929-31.
15. Bahler DW, Swerdlow SH. Clonal salivary gland infiltrates associated with myoepithelial sialadenitis (Sjogren's syndrome) begin as nonmalignant antigen-selected expansion. *Blood* 1998;91:1864-72.
16. De Vita S, Boiocchi M, Sorrentino D, Carbone A, Avellini C, Dolcetti R, Marzotto A, Gloghini A, Bartoli E, Beltrami CA, Ferraccioli G. Characterization of prelymphomatous stages of B cell lymphoproliferation in Sjogren's syndrome. *Arthritis Rheum* 1997;40:318-31.
17. Anaya JM, McGuff S, Banks PM, Talal N. Clinicopathological factors relating malignant lymphoma with Sjogren's syndrome. *Semin Arthritis Rheum* 1996;25:337-46.
18. Fong S, Chen PP, Gilbertson TA, Weber JR, Fox RI, Carson DA. Expression of three cross-reactive idiotypes on rheumatoid factor autoantibodies from patients with autoimmune diseases and seropositive adults. *J Immunol* 1986;137:122-8.
19. Fox RI, Chen P, Carson DA, Fong S. Expression of a cross reactive idiotypic on rheumatoid factor in patients with Sjogren's syndrome. *J Immunol* 1986;136:477-83.
20. Katsikis PD, Youinou PY, Galanopoulou V, Papadopoulos NM, Tzioufas AG, Moutsopoulos HM. Monoclonal process in primary Sjogren's syndrome and cross-reactive idiotypic associated with rheumatoid factor. *Clin Exp Immunol* 1990;82:509-14.
21. Bahler D, Miklos JA, Swerdlow SH. Ongoing Ig gene hypermutation in salivary gland mucosa-associated lymphoid tissue-type lymphomas. *Blood* 1997;89:3335-44.
22. Royer B, Cazals-Hatem D, Sibilia J, Agbalika F, Cayuela J-M, Soussi T, Maloisel F, Clauvel JP, Brouet JC, Marriette X. Lymphomas in patients with Sjogren's syndrome are marginal zone B-cell neoplasms, arise

- in diverse extranodal and nodal sites and are not associated with viruses. *Blood* 1997;90:766–75.
23. Martin T, Weber JC, Levallois H, Labouret N, Soley A, Koenig S, Korganow AS, Pasquali JL. Salivary gland lymphomas in patients with Sjogren's syndrome may frequently develop from rheumatoid factor B cells. *Arthritis Rheum* 2000;43:908–16.
 24. Peng H, Chen G, Du M, Singh N, Isaacson PG, Pan L. Replication error phenotype and p53 gene mutation in lymphomas of mucosa-associated lymphoid tissue. *Am J Pathol* 1996;148:643–8.
 25. Du M, Peng H, Singh N, Isaacson PG, Pan L. The accumulation of p53 abnormalities is associated with progression of mucosa-associated lymphoid tissue lymphoma. *Blood* 1995;86:4587–93.
 26. Soussi T. The humoral response to the tumor-suppressor gene product p53 in human cancer. Implications for diagnosis and therapy. *Immunol Today* 1996;17:354–6.
 27. Tapinos NJ, Polihronis M, Moutsopoulos HM. Lymphoma development in Sjogren's syndrome. Novel p53 mutations. *Arthritis Rheum* 1999;42:1466–72.
 28. Kuppers R, Klein U, Hansmann M-L, Rajewsky K. Cellular origin of human B-cell lymphomas. *N Engl J Med* 1999;341:1520–9.
 29. Anderson LG, Talal N. The spectrum of benign to malignant lymphoproliferation in Sjogren's syndrome. *Clin Exp Immunol* 1971;9:199–221.
 30. Tzioufas AG, Boumba DS, Skopouli FN, Moutsopoulos HM. Mixed monoclonal cryoglobulinemia and monoclonal rheumatoid factor cross-reactive idiotypes as predictive factors for the development of lymphoma in primary Sjogren's syndrome. *Arthritis Rheum* 1996;39:767–72.
 31. Walters MT, Stevenson FK, Herbert A, Cawley MID, Smith JL. Urinary monoclonal free light chains in the primary Sjogren's syndrome: an aid to the diagnosis of malignant lymphoma. *Ann Rheum Dis* 1986;45:210–19.
 32. Skopouli FN, Dafni U, Ioannidis JPA, Moutsopoulos HM. Clinical evolution, and morbidity and mortality of primary Sjogren's syndrome. *Semin Arthritis Rheum* 2000;29:296–304.
 33. Harris NL. Lymphoid proliferations of the salivary glands. *Am J Clin Pathol* 1999;111(Suppl):S94–103.
 34. Voulgarelis M, Dafni UG, Isenberg DA, Moutsopoulos HM. Malignant lymphoma in primary Sjogren's syndrome. *Arthritis Rheum* 1999;42:1765–72.
 35. Zulman J, Jaffe R, Talal N. Evidence that the malignant lymphoma of Sjogren's syndrome is a monoclonal B-cell neoplasm. *N Engl J Med* 1978;299:1215–20.
 36. Mariette X. Lymphomas in patients with Sjogren's syndrome: Review of the literature and physiopathologic hypothesis. *Leuk Lymphoma* 1999;33(1-2):93–9.
 37. Shin SS, Sheibani K, Fishleder A, Ben-Ezra J, Bailey A, Koo CH, Burke JS, Tubbs R, Rappaport H. Monocytoid B-cell lymphoma in patients with Sjogren's syndrome. *Hum Pathol* 1991;22:422–30.
 38. Pelstring RJ, Essell JH, Kurtin PJ, Cohen AR, Banks PM. Diversity of organ site involvement among malignant lymphomas of mucosa-associated tissues. *Am J Surg Pathol* 1991;96:738–45.
 39. Chan WC, Derkmezian R. Phenotypic changes in large cell transformation of small cell lymphoid malignancies. *Cancer* 1986;57:1971–8.
 40. Chan JKC, Ng SC, Isaacson PG. Relationship between high grade lymphoma and low grade B-cell mucosa-associated lymphoid tissue lymphoma (MALToma) of the stomach. *Am J Pathol* 1990;136:1153–64.
-
- Correspondence:** Dr. H.M. Moutsopoulos, M. Asias 75, Goudi, 11527 Athens, Greece. Phone: (30-1) 777-1095, 778-9480, Fax: (30-1) 770-3876, email:hmoutsop@med.uoa.gr