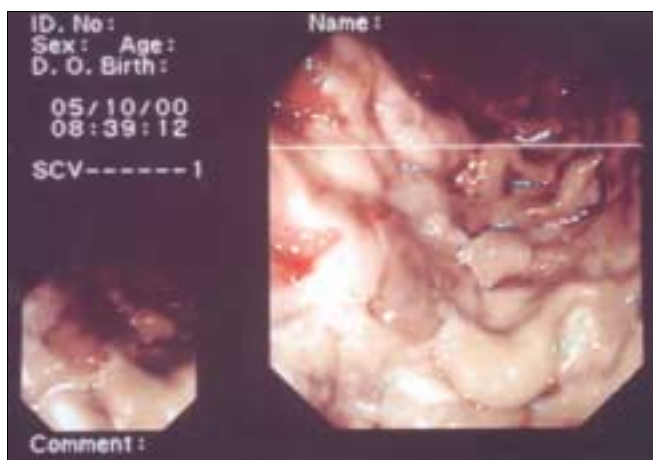


Ischemic Colitis – A Case of Triple Senses Diagnosis

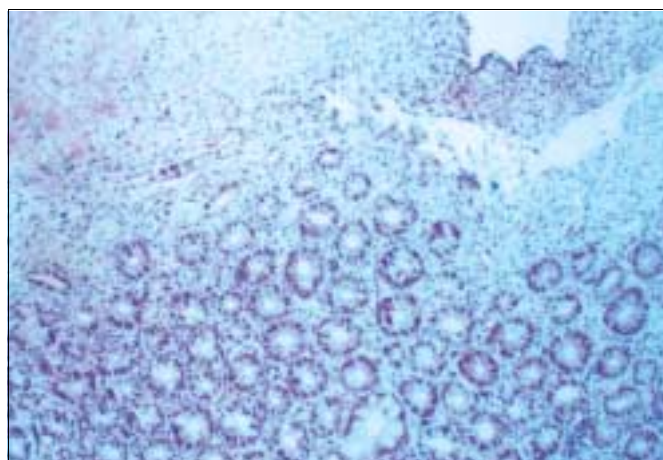
Irit Chermesh MD¹, Ofer Ben-Izhak MD² and Rami Eliakim MD¹

Institutes of ¹Gastroenterology and ²Pathology, Rambam Medical Center, Haifa, Israel

IMAJ 2001;3:626



[A] View of ischemic colon through the endoscope



[B] Ischemic colon (hematoxylin and eosin x100)

An 87 year old man was hospitalized because of bloody diarrhea, nausea and vomiting that began the previous day. His history was notable only for controlled hypertension. On admission he was conscious and hemodynamically stable. His abdomen was noted to be soft with no peritoneal signs. Per rectum was a small amount of fresh blood. Laboratory results showed leukocytosis of 42,800/ml and renal failure with creatinine of 2.6 mg/dl. Colonoscopy revealed colitis as well as what resembled necrotic tissue localized 30–40 cm from the anus [Figure A].

Inserting the biopsy forceps in order to take tissue for pathologic investigation led to sinking of the apparatus in what appeared to be decayed material. The odor of the specimen was also compatible with the above. The sight, touch and smell of the colonic finding led to the presumed diagnosis of ischemic colitis. The patient underwent emergency near-total colectomy with cholecystectomy. The colonic biopsy showed necrosis of the upper luminal portion of the mucosa with sharp demarcation from the preserved mucosal tissue in the lower (basal) portion

[Figure B, hematoxylin and eosin x100].

The postoperative course was complicated by an anastomosal leak that necessitated surgical intervention. An ileostomy was performed and drainage tubes were left in the peritoneal space. The patient did not recover and died 20 days after being admitted to the hospital.

Correspondence: Dr. E. Chermesh, Institute of Gastroenterology, Rambam Medical Center, Haifa 31096, Israel. Phone: (972-4) 854-2504, Fax: (972-4) 854-3058, email: irit_chermesh@hotmail.com

Painting is poetry that is seen rather than felt, and poetry is painting that is felt rather than seen.

Leonardo da Vinci, 1519