



Mixed Cryoglobulinemia and Hepatitis C Virus Association: Ten Years Later

Alessandra Della Rossa MD, Antonio Tavoni MD, Chiara Baldini MD and Stefano Bombardieri MD

Clinical Immunology Unit, Department of Internal Medicine, University of Pisa, Pisa, Italy

Key words: mixed cryoglobulinemia, hepatitis C virus, rheumatic manifestations

Abstract

Mixed cryoglobulinemia is a systemic vasculitis described as a triad characterized by purpura, weakness and arthralgias. Since the first description of the disease in 1964 by Meltzer and Franklin our understanding of its pathogenesis has increased considerably. The striking association of the disease with hepatitis C virus infection was initially noted in 1990. Since then, the disease has gained growing attention among investigators involved in the study of autoimmune systemic disorders because it represents one of the most intriguing models of autoimmunity triggered by a virus. Nonetheless, a number of answered questions still remain to be resolved and are reviewed in this article.

IMAJ 2001;3:430-434

Mixed cryoglobulinemia was first described by Meltzer and Franklin in 1964 as a syndrome characterized by purpura, weakness and arthralgias [1]. During the past ten years intensive research work has led to the identification of the trigger of the disease, previously referred to as “essential,” and in 1990 a clear association between HCV and MC was demonstrated [2]. However, despite the many advances in the study of this relationship over the last few years, a number of unresolved issues remain, presenting a challenge for investigators in this field.

Clinical features

During the years 1966 to 1990 analyses of large series of MC patients made it possible to define the clinical manifestations of the disease [1,3-7]. The disease combines the features of a systemic immune complex-mediated disease with those of a lymphoproliferative disorder. MC is a vasculitis involving the small arteries and veins and is associated with the presence of large amounts of mixed immunoglobulin M and G cryoglobulins with rheumatoid factor activity. The clinical hallmark of the disease is purpura, present in over 90% of patients, which is due to a leukocytoclastic vasculitis and is localized mainly in the lower extremities [3]. Liver involvement is another frequent characteristic of MC, and if severe, can seriously affect the

overall prognosis of the disease [3,4]. Renal involvement is one of the most serious complications of MC and affects approximately one-third of patients. Histologically it almost invariably takes the form of a membranoproliferative glomerulonephritis with a varying degree of interstitial and vascular damage. Clinically it ranges from isolated proteinuria to a frank nephritic syndrome. The disease course is generally characterized by periods of remission and exacerbation and, if not treated correctly, may eventually result in renal failure [5,6].

Another common manifestation of the disease is peripheral neuropathy. Although the symptoms may be mild, electro-neurographic signs of peripheral neuropathy are present in the majority of MC patients. Paresthesias or an impairment of the sensitive fibers are the most frequent manifestation. Pure motor neuropathy is a rare but disabling condition [7].

MC is frequently associated with a benign lymphoproliferative disorder in the form of distinct lymphoid infiltrates, with cells bearing surface monoclonal rheumatoid factor in the portal tracts, spleen and bone marrow [8]. This disorder can evolve to a frank non-Hodgkin's B cell lymphoma in up to 10% of patients [9].

Laboratory features

MC is a typical model of an immune complex-mediated disease. The presence of a high amount of IgM anti-IgG activates the complement system through the classical pathway, thus the presence of low levels of C4 is a common feature. Due to the presence of high levels of immune complexes and rheumatoid factor, patients with MC are considered to be at higher risk to develop hyperviscosity syndrome. However, although increased blood viscosity and reduced blood filtration can be demonstrated in a high percentage of patients, a patent hyperviscosity syndrome is relatively uncommon due to a parallel reduction in the hematocrit [10].

MC and HCV

MC is an immune complex disease with a particular geographic distribution, being more prevalent in southern Europe. This fact, together with a frequent liver involvement and the lack of a definite HLA association, points to an environmental factor – possibly a hepatotropic virus – as the actual trigger of the disease [11]. Although the first attempts to associate the prevalence of hepatitis B virus to the disease were inconclusive

HCV = hepatitis C virus
MC = mixed cryoglobulinemia

[12,13], the discovery of HCV in 1980 prompted a number of investigators to seek this agent in MC [14]. The first studies immediately disclosed the magnitude of the association. Using a first-generation test, antibodies against HCV were initially demonstrated in 30–54% of all MC patients [2,15,16]. With the introduction of the more sensitive, second-generation enzyme-linked immunosorbent assay and recombinant-based immunoblotting assay, the prevalence of serum anti-HCV in MC patients was found to range from 70 to 100% [17–19]. The high prevalence of antibodies against HCV in MC was associated with a similar prevalence (86%) of HCV viremia in the same patients [2]. The discovery of this association caught the attention of a growing number of investigators worldwide regarding a previously overlooked disease [Figure 1]. This impressive amount of information pointed to a causative role of HCV in MC. HCV was found in fact to be present in about 72% of all series worldwide.

The virus appears to be concentrated in the cryoglobulins and deposited in the target organs [20–22]. Moreover, chronic HCV infection was found to trigger the lymphoproliferative response seen in MC, eventually leading to malignant lymphoma [9]. Yet a number of questions still remain unanswered and will be the chief target of investigation in the next decade. These issues are discussed below.

How many HCV-infected individuals develop MC or systemic vasculitis?

The seroprevalence of HCV in many developed countries is about 1%. HCV infection is associated with several autoantibodies, even in the absence of rheumatic symptoms. Moreover, up to 75% of chronically infected patients have serum rheumatoid factor [23,24]. However, most patients with chronic HCV infection do not develop mixed cryoglobulinemia, the prevalence ranging from 13 to 54% among the different series. It is important to note that the presence of these autoantibodies is not necessarily associated with the appearance of symptoms, and the full-blown cryoglobulinemic syndrome appears only in a minority of cases. The mechanism leading to the formation of autoantibodies during HCV infection remains obscure. Direct infection of lymphocytes by HCV may play a role. Alternatively, chronic immune complex overproduction may influence rheumatoid factor synthesis [23]. Of interest is the potential of molecular mimicry between some types of autoantibodies and certain viral antigens (i.e., anti-GOR, anti-LKM1 and viral peptides, human IgG and c 22) [25–27].

Is MC genetically linked?

Since HCV infection is not capable of causing MC in all infected patients, other factors in addition to the virus play a role. Host factors, and mainly genetic background, are probably equally important.

The variation in autoimmune features may be a consequence of genetic polymorphism in HCV-infected individuals. For example, polymorphism of a gene coding a public conformational peptide expressed on monoclonal rheumatoid factor might represent a genetic risk factor for the development of

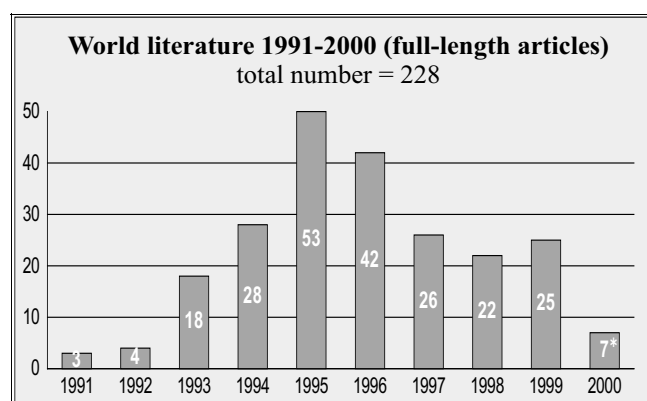


Figure 1. Number of full-length articles in the last decade

rheumatoid factor itself or cryoglobulins [28]. The few attempts to associate host HLA profiles with MC have been inconclusive, although HLA B8/DR3 was recently claimed to confer susceptibility to HCV-related mixed cryoglobulinemia [11,29]. The possibility of genetic background predisposing to MC remains an open question and further studies are necessary to explore this subject in depth.

Is MC related to the genotype of HCV?

Several reports claim a different pathogenicity and response of different HCV strains to interferon-alpha therapy. For example, genotype 1b has been associated with a significantly lower rate of response to interferon alpha as compared to other genotypes [30]. To date, attempts to find a significant association between any of the HCV genotypes and MC have been inconclusive, although it is claimed that genotype 2a, which reportedly has a higher prevalence in MC patients than in chronic HCV carriers without MC, may tend more than other genotypes to trigger lymphoproliferative disorders [31,32]. An interesting challenge for the investigator would be to study whether the quasi-species genomic distribution of HCV-infected MC patients is different from HCV-infected individuals without MC.

Is the HCV “associated” MC dependent on the host immune response?

The current literature provides scant data on the host immune response against HCV, particularly in MC. Sera from subjects infected with HCV contain antibodies reactive against most of the viral proteins. Among these proteins, recombinant NS4 has recently emerged as a useful tool in the screening for HCV infection since it is a frequent target of the immune response.

Recently our group analyzed the immune response to a dominant epitope of NS4 (sequence 1921-40) located near the C terminal region of NS4b, and found that the reactivity with the epitope varies according to the disorder examined. In fact, antibodies against NS4 1921-40 were detected in 64% of the sera from patients with autoimmune hepatitis, in 51% from chronic hepatitis C and in 22% from MC. Among the disorders studied the reactivity against peptide 1921-40 was particularly low in MC. The clinical relevance of this response has not yet been established, although it could reflect a different immune

response to the virus that might predispose the host to autoimmunity. To strengthen this observation, the small group of MC patients that produced anti-peptide antibodies was characterized by liver involvement but showed no signs of kidney involvement, suggesting that the presence of the antibodies might be related to the clinical manifestations of the disease [33]. Further studies are necessary to clarify this issue.

Is MC the only rheumatic disorder associated with HCV infection?

A wide variety of rheumatic diseases has been associated with HCV infection, namely systemic vasculitides, Sjogren's syndrome and rheumatoid arthritis. Systemic vasculitides comprise a heterogeneous group of autoimmune disorders. Until recently, the etiological factors triggering these conditions were generally unknown, with the exception of hepatitis B-associated polyarteritis. Recently however, several systemic vasculitides were found to be associated with HCV infection. Mixed cryoglobulinemia, polyarteritis nodosa and leukocytoclastic vasculitis are, in descending order of frequency, the conditions most frequently described in association with HCV infection. The strongest association is with MC, while the role of HCV in PAN and LV is still controversial. The prevalence of HCV infection is low in the former (no more than 8–10%) [23] and there are few anecdotal reports on the latter. Since HCV frequently co-infects patients with hepatitis B, the association of HCV with PAN is probably spurious and might reflect the common route of transmission of the two viruses. LV, on the other hand, might be the expression of an incomplete form of cryoglobulinemic syndrome [23,28].

HCV seems to be responsible for some cases of Sjogren's syndrome, especially in patients who lack anti-SSA/Ro and anti-SSB/La antibodies. However, compared to MC, the role of HCV in Sjogren's syndrome is less clearly demonstrated [34].

The role of HCV in rheumatoid arthritis is still anecdotal, being based on a number of cases in which an association is claimed. Although the higher prevalence of HCV among RA patients is probably fortuitous and in view of the numerous invasive procedures that RA patients must undergo, the infection is, at least in some cases, linked to the appearance of chronic synovitis [23]. It was recently suggested that anti-keratin antibodies may be a useful tool to distinguish between rheumatoid arthritis and rheumatoid factor-positive polyarthritis associated with HCV infection [35]. This question requires a more thorough investigation.

What is the time lapse from HCV infection to the appearance of MC or other related syndromes?

In the host, HCV induces a chronic infection characterized by continuous viral replication, in some cases for more than 15 years [23]. Furthermore, chronic carriers may undergo superinfection with heterologous HCV strains [33]. Genetic HCV

heterogeneity is a major challenge for the host since the immune response is isolate restricted and the immune system is in a state of continuously changing balance with the virus. The emergence of neutralizing escape mutants together with super-infection by new strains is responsible for the high rate of the infection's chronicity. Persistence of the virus in the host, along with yet undefined factors, triggers the appearance of autoimmune phenomena. The exact timing of this appearance is not defined, although our MC patients showed increased liver transaminases for as long as 7 years before the appearance of cryoglobulins. Moreover, indirect evidence from a patient seen in our unit suggests that there may be a lapse of as long as 6 years between the first detection of HCV infection and the appearance of symptoms related to mixed cryoglobulinemia [4,36].

Is MC only an HCV-related disease?

MC is actually regarded as a paradigmatic model of a viral triggered disease that shares the features of an autoimmune immune complex-mediated disease with those of a smoldering lymphoproliferative process. The viral persistence represents a continuous challenge for the host. The chronic stimulation of the immune system triggers the appearance of autoantibodies through molecular mimicry or other unidentified mechanisms on the one hand, while favoring the emergence of clones protected against apoptosis on the other, possibly maintaining through a vicious circle the pathway of autoimmunity [37]. Before the discovery of HCV as the main trigger of the disease, MC was regarded as a typical model of an idiopathic immune complex-mediated disease, and a number of studies demonstrated the pathogenesis of immune complex formation and deposition [38]. By critical analysis of the data available, we can conclude that MC should not be considered as simply a viral triggered disease, but a self-maintaining autoimmune disorder that may escape from the initial triggering factor and represents a separate entity. In other words, the autoimmune disorder may become independent of the initial stimulus represented by HCV infection and may have an independent destiny. In this context, renal involvement, which is marked by an abrupt onset and by a course with alternating periods of flares and remissions, has been studied as a model of autoimmune manifestation induced by the formation of immune complexes.

Several years ago our group detected autoantibodies reactive against a 50 kDa antigen isolated from a glomerular extract, subsequently sequenced and identified as enolase alpha. These autoantibodies were mainly represented in a group of patients with active renal involvement, and in a follow-up study the amount fluctuated either spontaneously or in response to therapy. It was then hypothesized that these antibodies could contribute to the induction of glomerulonephritis in MC through the formation of *in situ* immune complexes. Further studies have demonstrated that anti-enolase alpha can frequently be detected in other systemic autoimmune disorders. In systemic lupus erythematosus and MC they are associated with nephritis and in systemic sclerosis they are associated with severe endothelial damage. Enolase alpha is ubiquitous but is highly expressed in the kidney and also on the membrane of

PAN = polyarteritis nodosa
LV = leukocytoclastic vasculitis
RA = rheumatoid arthritis

several cell types, including endothelial cells. Thus, antibodies against enolase alpha could contribute to renal injury – not only by the local formation of immune complexes but also by direct damage to endothelial cells. It is not surprising therefore that these autoantibodies are detected in disorders that have in common endothelial injury at least in some aspects of their pathogenesis. Recently, using flow cytometry and immunoprecipitation techniques, it was demonstrated that enolase alpha is expressed not only in the cytoplasm but also on the surface of the cell. Furthermore, anti-enolase alpha antibodies, recognizing the membrane-associated form of the enzyme, are able to inhibit the binding of plasminogen [39].

What treatment should be given to MC patients?

Mixed cryoglobulinemia has a multifactorial origin and the tissue damage is due to a number of mechanisms. The most important are the deposition of (HCV-containing) immune complexes, the chronic stimulus by HCV infection, and the presence of a benign smoldering lymphoproliferative process. The spectrum of disease manifestation is characterized by a wide polymorphism, and the clinical picture may vary from very mild symptoms (such as weakness and arthralgias) to life-threatening conditions (like rapidly progressive glomerulonephritis). Furthermore, the clinical course is characterized by alternating periods of remission and exacerbation. Another feature of MC is that serological parameters cannot be used as guides to therapy, since none of these correlates with clinical activity or disease severity. Therefore, no single treatment schedule can be established for this complex multisystem disease, and management is generally aimed at controlling the prevailing symptom, chiefly the extent and severity of organ involvement. Knowledge about the disease triggers has recently been clarified. In particular, the distinct association with HCV infection now prompts the clinician to reconsider the previous approach to the disease. The aggressive use of cytotoxic drugs should be abandoned due to the risk of progression of HCV infection.

Table I summarizes the main therapeutic modalities in MC. Non-steroidal anti-inflammatory drugs can help to relieve some of the diffuse arthralgias or non-erosive polyarthritis and should be used symptomatically. Medium to low doses of corticosteroids (0.1–0.3 mg/kg/day) are usually sufficient to control most of the minor symptoms of MC such as purpura, arthralgias, arthritis and weakness. Larger doses (0.5–1.5 mg/kg/day) are used for the management of renal involvement, peripheral neuropathy and serositis [3].

In a proposed dynamic model of MC, the immune complex competes with other inputs to the mononuclear phagocytic system. Under normal conditions these inputs consist primarily of blood-borne constituents and high molecular weight exogenous substances that cross the mucosal barrier of the gut and enter the circulation through the lymph and portal vein. A diet that reduces the levels of these components could help to restore a saturated mononuclear phagocytic system, thus freeing it to remove the immune complexes. A short-term placebo-controlled study demonstrated the beneficial effect of diet in

Table 1. Principal therapeutic approaches and their clinical indications in MC

| | |
|---------------------------------------|--|
| Non-steroidal anti-inflammatory drugs | Purpura Weakness Arthralgias |
| Low dose steroids | Sensitive neuropathy |
| Low antigen content diet | Sjogren's syndrome |
| High dose steroids | Glomerulonephritis |
| Plasmapheresis | Motor neuropathy |
| Cytotoxic agents | Hyperviscosity syndrome Systemic vasculitis |
| Low antigen content diet | Liver involvement |
| Interferon alpha | Low dose steroids |

MC patients, in both clinical and laboratory parameters [40]. Although the effect of this diet on the natural history of MC is still uncertain, an open uncontrolled study showed a positive outcome in patients on a long-term intermittent diet.

Aggressive therapies such as plasma exchange are to be used in cases of life-threatening or disabling conditions. Plasma exchange, with or without immunosuppressive drugs, has been successfully employed to treat rapidly progressive glomerulonephritis, motor neuropathy and hyperviscosity syndrome. Double-filtration plasmapheresis reduces the need to substitute proteins and fluids. Cryo-apheresis takes advantage of the cold sensitivity of the cryoglobulins [41,42].

After the discovery of the indubitable association between MC and HCV infection, the use of antiviral agents such as interferon-alpha gained increasing attention. In 1986 the first pilot study on interferon in the treatment of MC was performed [43]. Given the antiviral, immunomodulatory and antiproliferative effects of interferon, the use of this agent in the treatment of MC has been advocated and several studies on its long-term effects in MC patients have been conducted. Clinical and biological remission has been reported in a high proportion of patients [44]. However, the initial enthusiasm for this drug was soon dampened by the frequent relapse rate observed after the cessation of therapy. To ensure a higher proportion of long-term responders, the administration schedule or dosage might be adjusted, or alternatively combination therapy with other agents such as ribavirin may be instituted [45,46]. The main indication for the administration of interferon therapy in MC is the presence of active liver involvement, and it should follow the program used in the management of HCV infection.

References

1. Meltzer M, Franklin EC, Elias K, McCluskey RT, Cooper N. Cryoglobulinemia. A clinical and laboratory study: cryoglobulins with rheumatoid factor activity. *Am J Med* 1966;40:837–56.
2. Ferri C, Greco F, Longombardo G, Palla P, Moretti A, Marzo E, Mazzoni A, Pasero G, Bombardieri S. Association between hepatitis C virus and mixed cryoglobulinemia. *Clin Exp Rheumatol* 1991;9:621–4.
3. Gorevich PD, Kassab HJ, Levo Y, Kohn R, Meltzer M, Prose P, Franklin E. Mixed cryoglobulinemia: clinical aspects and long term follow-up of 40 patients. *Am J Med* 1980;69:287–308.
4. Bombardieri S, Ferri C, Di Munno O, Pasero G. Liver involvement in essential mixed cryoglobulinemia. *Ric Clin Lab* 1979;9:361–8.
5. Tarantino A, De Vecchi A, Montagnino G, Imbasciati E, Minatsch MJ,

- Zollinger HU, Di Belgiojoso GB, Busnach G, Ponticelli C. Renal disease in essential mixed cryoglobulinemia: long term follow-up of 44 patients. *Q J Med* 1981;197:1-30.
6. Druet P, Leontourier P, Contet D, Mandet C. Cryoglobulinemia in human renal diseases. A study of 76 cases. *Clin Exp Immunol* 1973;15:483-96.
 7. Ferri C, La Civita L, Cirafisi C, Siciliano G, Longombardo G, Bombardieri S, Rossi B. Peripheral neuropathy in mixed cryoglobulinemia: clinical and electrophysiological investigations. *J Rheumatol* 1992;19:889-95.
 8. Monteverde A, Rivano MT, Allegra GC, Monteverde AI, Ziggrossi P, Baglioni P, Gobbi M, Falini B, Bordin G, Pileri S. Essential mixed cryoglobulinemia type II: a manifestation of a low grade malignant lymphoma? *Acta Haematol* 1988;79:20-5.
 9. Ferri C, La Civita L, Longombardo G, Lombardini F, Pasero G, Zignego AL, Monti M, Mazzaro C, Greco F, Mazzoni A. Hepatitis C virus in mixed cryoglobulinemia and B cell lymphoma. *Clin Exp Rheumatol* 1994;12:89-96.
 10. Ferri C, Mannini L, Bartoli V. Blood viscosity and filtration abnormalities in MC patients. *Clin Exp Rheumatol* 1990;8:271-81.
 11. Migliorini P, Bombardieri S, Castellani A, Ferrara GB. HLA antigens in essential mixed cryoglobulinemia. *Arthritis Rheum* 1981;24:932-4.
 12. Levo Y, Gorevich PD, Kassab HJ, Zucker-Franklin D, Franklin EC. Association between hepatitis B virus and essential mixed cryoglobulinemia. *N Engl J Med* 1977;296:1501-4.
 13. Popp JW, Dienstag JL, Wands JR, Bloch KJ. Essential mixed cryoglobulinemia without evidence for hepatitis B virus infection. *Ann Intern Med* 1980;92:379-83.
 14. Choo QL, Kuo G, Weiner AJ, Overby LR, Bradley DW, Houghton NL. Isolation of a c-DNA clone derived from a blood borne non-A, non-B viral hepatitis genome. *Science* 1989;244:359-62.
 15. Ferri C, Greco F, Longombardo G, Palla P, Marzo E, Moretti A, Fosella PV, Pasero GP, Bombardieri S. Hepatitis C antibodies in mixed cryoglobulinemia patients. *Arthritis Rheum* 1991;34:1606-10.
 16. Pascual M, Perrin L, Giostra E, Schifferli JA. Hepatitis C virus infection in patients with cryoglobulinemia type II. *J Infect Dis* 1990;162:569-70.
 17. Ferri C, Greco F, Longombardo G, Palla P, Moretti A, Marzo E, Fosella PV, Pasero G, Bombardieri S. Antibodies against hepatitis C virus in mixed cryoglobulinemia patients. *Infection* 1991;19:417-20.
 18. Disdier P, Harlò JR, Weiller PJ. Cryoglobulinemia and hepatic infection. *Lancet* 1991;338:1151-2.
 19. Taillan B, Ferrari P, Ferrari E, Fuzibet JG, Pesce A, Quaranta JF, Dujarden P. Cryoglobulinemia associated with hepatitis C virus infection: a report of 13 cases. *J Intern Med* 1992;321:372-3.
 20. Agnello V, Chung RT, Kaplan LM. Evidence for a role for hepatitis C virus infection in the pathogenesis of type II mixed cryoglobulinemia. *N Engl J Med* 1992;327:1490-5.
 21. Agnello V, Abel G. Localization of hepatitis C virus in cutaneous vasculitic lesions in patients with type II cryoglobulinemia. *Arthritis Rheum* 1997;40:2007-15.
 22. Sansonno D, Cornacchiolo V, Iacobelli AR, Stefano RD, Lospalluti M, Dammacco F. Localization of hepatitis C virus antigens in liver and skin tissues of chronic hepatitis C virus infected patients with mixed cryoglobulinemia. *Hepatology* 1995;21:305-12.
 23. Wener MH, Johnson RJ, Sasso RH, Gretch D. Hepatitis C and rheumatic disease [Review]. *J Rheumatol* 1996;23:953-9.
 24. Cacoub P, Hausfater P, Musset L, Piette JC. Mixed cryoglobulinemia in hepatitis C patients. *Ann Intern Med (Paris)* 2000;151:20-9.
 25. Hosein B, Fang X, Wang CY. Anti HCV, anti GOR and autoimmunity [Letter]. *Lancet* 1992;339:871.
 26. Yamamoto AM, Cresteil D, Homberg JC, Alvarez F. Characterization of anti-liver-kidney microsome antibody (anti-LKM1) from hepatitis C virus-positive and negative sera. *Gastroenterology* 1993;104:1762-7.
 27. Hartmann H, Schott P, Polzien F, Mihm S, Uy A, Kaboth U, Pardowitz I, Ramadori G. Cryoglobulinemia in chronic hepatitis C virus infection: prevalence, clinical manifestations, response to interferon treatment and analysis of cryoprecipitates. *Z Gastroenterol* 1995;33:643-50.
 28. Mc Murray R, Elbourne K. Hepatitis C virus infection and autoimmunity [Review]. *Semin Arthritis Rheum* 1997;26:689-701.
 29. Lenzi M, Frisoni M, Mantovani W, Ricci P, Muratori L, Francesconi R, Cuccia MC, Ferri S, Bianchi FB. Haplotype HLA B8/DR3 confers susceptibility to hepatitis C virus related mixed cryoglobulinemia. *Blood* 1998;91(6):2062-6.
 30. Matsumoto A, Tanaka E, Suzuki T, Ogata H, Kiyosawa K. Viral and host factors that contribute to efficacy of interferon-alpha 2 therapy in patients with chronic hepatitis C. *Dig Dis Sci* 1994;39:1273-80.
 31. Pozzato G, Mazzaro C, Crovatto M, Modolo ML, Ceselli S, Mazzi G, Sulfaro S, Franzin F, Tulisi P, Moretti M, Santini GF. Low grade malignant lymphoma, hepatitis C virus infection, and mixed cryoglobulinemia. *Blood* 1994;84:3047.
 32. Zignego AL, Ferri C, Monti M, La Civita L, Giannini C, Carocchia G, Giannelli F, Pasero G, Bombardieri S, Gentilizi P. Hepatitis C virus as a lymphotropic agent: evidence and pathogenetic implications [Review]. *Clin Exp Rheumatol* 1995;13(Suppl 13):S33-7.
 33. Longombardo G, Ferri C, Marchi S, Costa F, Lombardini F, Vacri L, Bombardieri S, Migliorini P. Immune response to an epitope of the NS4 protein of hepatitis C virus in HCV related disorders. *Clin Immunol Immunopathol* 1998;87:124-9.
 34. Ramos-Casals M, Garcia Carrasco M, Cervera R, Font J. Sjogren's syndrome and hepatitis C virus [Review]. *Clin Rheumatol* 1999;18:93-100.
 35. Kessel A, Rosner I, Zuckerman E, Golan TD, Toubi E. Use of antikeratin antibodies to distinguish between rheumatoid arthritis and polyarthritis associated with hepatitis C infection. *J Rheumatol* 2000;27:610-12.
 36. Della Rossa A, Tavoni A, Lorefice P, Casala F, Bombardieri S. HBV and HCV infection, polyarteritis nodosa and mixed cryoglobulinemia: a case report. *Clin Rheumatol* 2000;19(6):502-4.
 37. Zignego AL, Giannelli F, Marrocchi ME, Giannini C, Gentilini P, Innocenti F, Ferri C. Frequency of bcl-2 rearrangement in patients with mixed cryoglobulinemia and HCV positive liver diseases. *Clin Exp Rheumatol* 1997;15:711-12.
 38. Della Rossa A, Ferri C, Bombardieri S. From essential mixed cryoglobulinemia to virus induced autoimmunity: ten years of research in mixed cryoglobulinemia. In: Shoenfeld Y, ed. *The Decade of Autoimmunity*. Amsterdam: Elsevier Sciences, 1999:235-43.
 39. Pratesi F, Moscato S, Sabbatini A, Chimenti D, Bombardieri S, Migliorini P. Autoantibodies specific for α -enolase in systemic autoimmune disorders. *J Rheumatol* 2000;27:109-15.
 40. Ferri C, Pietrogrande M, Cecchetti R, Tavoni A, Cefalo A, Buzzetti G, Vitali C, Bombardieri S. Low antigen content diet in the treatment of mixed cryoglobulinemia patients. *Am J Med* 1989;87:519.
 41. Tavoni A, Mosca M, Ferri C, Moriconi L, La Civita L, Lombardini F, Bombardieri S. Guidelines for the management of essential mixed cryoglobulinemia [Review]. *Clin Exp Rheumatol* 1995;13(Suppl 13):S191-5.
 42. Della Rossa A, Trevisani G, Bombardieri S. Cryoglobulins and cryoglobulinemia. Diagnostic and therapeutic considerations [Review]. *Clin Rev Allergy Immunol* 1998;16:249-64.
 43. Bonomo L, Casato M, Afeltra A, Caccavo D. Treatment of idiopathic mixed cryoglobulinemia with alpha interferon. *Am J Med* 1987;83:726-30.
 44. Ferri C, Marzo E, Longombardo G, Lombardini F, La Civita L, Vanacore R, Liberati AM, Gerli R, Greco F, Moretti A, Monti M, Gentilini P, Bombardieri S, Zignego AL. Interferon alpha in mixed cryoglobulinemia patients: a randomized crossover controlled trial. *Blood* 1993;81:1132-6.
 45. Donada C, Crucitti A, Donadon V, Chemello L, Alberti A. Interferon and ribavirin combination therapy in patients with chronic hepatitis C and mixed cryoglobulinemia. *Blood* 1998;92:2983-4.
 46. Durand JM, Cacoub P, Lunel-Fabiani F, Cosserat J, Cretel E, Kaplanski G, Frances C, Bletry O, Soubeyrand J, Godeau P. Ribavirin in hepatitis C related cryoglobulinemia. *J Rheumatol* 1998;25:1115-17.

Correspondence: Dr. A. Tavoni, Clinical Immunology Unit, Dept. of Internal Medicine, University of Pisa, via Roma 67, 56126 Pisa, Italy. Phone: (39-050) 993-048, Fax: (39-050) 558-629, email: a.tavoni@int.med.unipi.it