

Arterial Thromboembolism from a Distal Aortic Thrombus in a Patient with Crohn's Disease

Jonathan M. Lehmann MB Bchir¹, Ali Shnaker MD¹, Daniel Silverberg MD², Kati Dayan MD² and Misha Witz MD¹

¹Vascular Surgery Unit and ²Department of Surgery A, Meir General Hospital, Kfar Saba [Affiliated to Sackler Faculty of Medicine, Tel Aviv University], Israel

Key words: arterial thromboembolism, Crohn's disease, inflammatory bowel disease

IMAJ 2001;3:226-227

We present a case of peripheral arterial thromboembolism from a distal aortic thrombus in a 50 year old woman suffering an acute exacerbation of Crohn's disease. Tests showed thrombocytosis and elevated anticardiolipin IgG antibody level. The literature contains sporadic reports of venous thrombosis in association with inflammatory bowel disease, but arterial cases are rare [1].

Patient Description

A 50 year old woman was admitted for treatment of an exacerbation of Crohn's disease from which she had suffered for 2 years. She was taking budesonide 3 mg three times daily and mercaptopurine 50 mg and Premaril Plus once daily. She gave no history of cardiovascular symptoms. On admission she was pale, thin, afebrile and normotensive with a pulse rate of 96/min. There were no cardiac murmurs. Her blood hemoglobin was 8.1 g/dl, white blood count $5.2 \times 10^3/\text{mm}^3$, platelet count $871 \times 10^3/\text{mm}^3$ and albumin 3.1 g/dl. Her erythrocyte sedimentation rate was 109. She was treated with a low fiber diet, oral steroids and antibiotics, which led to a gradual improvement in her general condition. An abdominal computed tomography scan showed bowel wall thickening in the terminal ileum and colon with mesenteric fatty infiltration and lymphadenopathy. Atheromatous changes were noted in the abdominal aorta and its branches.

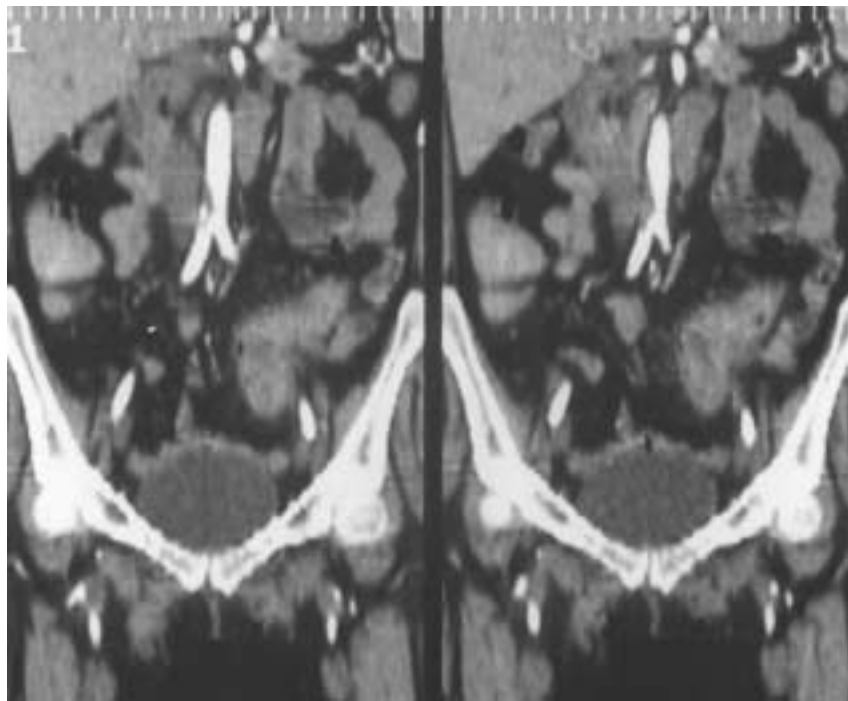
Three days after admission she suddenly developed pain, paraesthesia and weakness in her right lower leg. The right foot was cold with clumsy movements, normal light touch sensation and absent

popliteal and pedal pulses. Intraoperative arteriography showed an above knee popliteal artery occlusion, and a balloon thromboembolectomy was performed. Repeat arteriography demonstrated the anterior tibial artery to be patent to the ankle. The posterior tibial artery was not visualized. After surgery a right dorsalis pedis pulse was palpable.

Her leg symptoms reappeared gradually over the next 12 hours, with disappearance of the right dorsalis pedis and popliteal pulses. Echocardiography was normal. On review of the abdominal CT scan a filling defect was noted immediately proximal to the aortic

bifurcation. The finding was confirmed on spiral CT aortography, which showed an aortic filling defect starting 4 cm distal to the renal arteries and extending 1 cm into the right common iliac artery [Figure].

At re-operation an 0.5x1x2 cm organized thrombus was removed from the distal aorta by balloon thrombectomy through the right common femoral artery. Because the thrombus was felt to be too small to be the CT finding, a distal aortotomy was performed using a left retroperitoneal approach. There was no additional thrombus in the aorta, which showed minimal wall thickening



Sagittal reconstruction of spiral CT aortogram demonstrating a filling defect in the distal aorta extending into the origin of the right common iliac artery.

without signs of ulceration, nor were there signs of significant atheromatous changes in the femoral arteries of either side. Rethrombectomy of the right popliteal artery was performed through the right common femoral arteriotomy and 100,000 units of urokinase were instilled into the right popliteal artery over a 60 minute period. Arteriography showed a patent, irregular walled popliteal and anterior tibial artery, which filled only to the distal lower leg.

Following surgery the patient received full dose intravenous heparin. Her right foot became warm with normal motor and sensory function, and a palpable right popliteal pulse was present. Warfarin treatment was started 48 hours postoperatively. Five days following surgery she was noted to have a weak right posterior tibial pulse.

She was discharged on the seventh postoperative day taking warfarin, high dose steroid therapy and 5 amino salicylic acid. Her thrombocyte count was $582 \times 10^3/\text{mm}^3$. Lupus anticoagulant, antithrombin III, protein C and S and activated protein C resistance were within normal limits. Anticardiolipin IgG antibody was 32.6 GPL units (normal <23); IgM antibody was within normal limits.

Comment

Our patient sustained a right popliteal embolus from a thrombus in her distal aorta. No significant atheromatous peripheral arterial disease was detected on physical examination, at operation or on intraoperative angiography. At the time she was suffering from an exacerbation of Crohn's disease. Laboratory tests

showed thrombocytosis and a slightly raised cardiolipin antibody titer.

Talbot et al. [1] reported the association of thromboembolic episodes and inflammatory bowel disease in 1.3% of 7,199 patients over a period of 11 years between 1970 and 1980, with a mortality of 25%. Venous thromboembolism constituted 66% of these occurrences. Peripheral arterial thromboembolism was seen in 7 patients (0.1%), the remainder suffering coronary artery thrombosis or mesenteric and portal vein thrombosis. Overall, 60% had thrombocytosis.

In a study of thrombotic risk factors in a population of inflammatory bowel disease sufferers, Hudson et al. [2] found that in patients with Crohn's disease the mean plasma VII:C, lipoprotein (a) and fibrinogen concentrations were significantly raised as compared with normal controls. These patients might be regarded as being at increased risk for the development of thromboembolic disease. Perler et al. [3] suggested that aortic mural thrombus in young women may be a discrete clinical entity. One of their two patients had Crohn's disease. These authors attributed the thrombosis in their patients to steroid treatment in heavy smokers. In our patient the thrombosis may have been precipitated by thrombocytosis in the presence of a pathological anticardiolipin antibody titer. She was not a smoker but was on steroid therapy. In a recent report of six cases of primary aortic mural thrombus, four patients presented with acute lower limb emboli requiring embolectomy for limb salvage [4]. Following systemic anticoagulation, serial aortic studies demonstrated resolution of the thrombus. Failure to continue warfarin therapy resulted in recurrent problems.

The antiphospholipid syndrome may be associated with aortic thrombosis. Vascular surgical procedures in these cases have a high incidence of post-operative thrombosis [5]. This might explain re-thrombosis of the popliteal artery following an apparently successful embolectomy in our patient, a woman without obvious peripheral arterial occlusive disease.

It would seem that in inflammatory bowel disease patients with peripheral thromboembolism and normal echocardiogram, a search for thrombus in the aorta may be rewarding. Aortic thrombectomy may be unnecessary. Indefinite warfarin treatment is probably essential.

References

1. Talbot RW, Heppell J, Dozois RR, Beart RW Jr. Vascular complications of inflammatory bowel disease. *Mayo Clin Proc* 1986;61(2): 140-5.
2. Hudson M, Chitolie A, Hutton RA, Smith MS, Pounder RE, Wakefield AJ. Thrombotic vascular risk factors in inflammatory bowel disease. *Gut* 1996;38(5):733-7.
3. Perler BA, Kadir S, Williams GM. Acute mural thrombus in young women: premature arteriosclerosis or separate clinical entity? *Surgery* 1991;110(5):912-16.
4. Hahn TL, Dalsing MC, Sawchuk AP, Cikrit DF, Lalka SG. Primary aortic mural thrombus: presentation and treatment. *Am J Surg* 1999; 133(1):52-9.
5. Nitecki S, Brenner B, Hoffman A, Lanir N, Shramek A, Torem S. Lower limb ischaemia in primary antiphospholipid syndrome. *Eur J Vasc Surg* 1993;7(4):414-19.

Correspondence: Dr. M. Witz, Head, Vascular Surgery Unit, Meir General Hospital, Kfar Saba 44281, Israel. Phone: (972-9) 747-2978/1114, Fax: (972-9) 747-112, email: mishawi@clalit.org.il

Capsule

Killing bacteria

Neutrophils kill invading bacteria with a variety of cellular weapons. Belaouaj et al. report that an enzyme known as neutrophil elastase (NE) specifically cleaves one of the bacterial outer membrane proteins, OmpA, damaging membrane integrity and causing bacterial cell death. This

finding is of note both as a potential antibacterial target and because NE has been considered for use in treating cystic fibrosis.

Science 2000;289:1185

