

Paraneoplastic Syndromes Associated with Anti-Hu Antibodies

Horacio Senties-Madrid MD¹ and Felipe Vega-Boada MD^{1,2}

¹Department of Neurology, National Institute of Medical Sciences and Nutrition Salvador Zubiran, and ²National Research Systems, National Council of Science and Technology (CONACYT), Mexico City, Mexico

Key words: paraneoplastic syndromes, Hu-antigens, anti-Hu antibodies, paraneoplastic sensory neuropathy, paraneoplastic encephalomyelitis, small cell lung carcinoma

Abstract

Paraneoplastic syndromes are disorders associated with cancer but without a direct effect of the tumor mass or its metastases on the nervous system. Small cell carcinoma of lung associated with paraneoplastic sensory neuronopathy and/or paraneoplastic encephalomyelitis with the presence of anti-Hu antibodies has been termed "anti-Hu syndrome." Anti-Hu associated PSN-PEM is an immune disorder in which both cell-mediated and humoral mechanisms are involved. Patients are considered affected by Anti-Hu associated PSN-PEM when they develop clinical signs and symptoms of CNS dysfunction and/or sensory neuropathy not caused by metastases or other disorders, and serum or cerebrospinal fluid is positive for Hu abs. SCLC is found in more than 90% of patients with cancer and positive Hu abs. Individual patients with Hu abs associated to SCLC may suffer PSN-PEM, limbic encephalitis, brainstem encephalopathy, opsoclonus-myoclonus, paraneoplastic cerebellar degeneration or myelopathy. Hu abs have a specificity of 99% and sensitivity of 82% in detecting paraneoplastic neurological syndromes. There are two types of treatment: the first is to treat the cancer, the second is to suppress the immune reaction with the use of corticosteroids, cyclophosphamide, azathioprine, plasma exchange, intravenous immunoglobulin and immunoadsorption; however, treatment of paraneoplastic syndromes is generally unsatisfactory.

IMAJ 2001;3:94-103

Paraneoplastic syndromes are disorders associated with cancer but without a direct effect of the tumor mass or its metastases on the nervous system [1]. Small cell carcinoma of lung associated with paraneoplastic sensory neuronopathy and/or paraneoplastic encephalomyelitis with the presence of anti-Hu antibodies has been termed "anti-Hu syndrome." However, other neurological manifestations and neoplasms have been related to these antibodies. The term also includes Hu-seropositive patients without an apparent underlying neoplastic

disease. During the past few years scientific interest in paraneoplastic syndromes has been enhanced by the discovery of antibodies responsible for inducing the pathological process. Paraneoplastic syndromes are difficult to diagnose because in the majority of patients the tumor is not evident at the onset of the neurological disorder. In this article we offer an overview of paraneoplastic syndromes associated with Hu abs.

Historical considerations

At the end of the nineteenth century Oppenheim reported the earliest cases of remote effects of cancer on nervous tissues. The most common clinical manifestation, a sub-acute progressive sensory neuronopathy, was reported by Weber and Hill in 1933, when they noted a complete degeneration of the posterior columns on examination of the spinal cord from a patient with "chronic polyneuritis" and oat cell carcinoma of the lung. One year later, the central neuraxis components of this disorder were described by Greenfield under the rubric of sub-acute spinocerebellar degeneration. In 1948 Wyburn-Mason recorded a case of cancer-related "polyneuritis" and the same year Derek Denny-Brown published two cases that defined the condition's anatomic substrate as the destruction of dorsal root ganglion cells (hence its designation as a neuronopathy). Guichard's accounts in 1949 of paraneoplastic polyneuritis with neurologic complaints represent the earliest use of this term. Ten years later, Brain and Henson [2] suggested the possibility that immunological disturbances were the cause of neurological syndromes associated with carcinoma. This point of view was shared by Dorothy Russell in 1961 when she proposed that the lymphoid infiltration of carcinomatous encephalomyelitis implied a local immunological reaction that might be provoked by the tumor itself, rather than an infectious agent. Peter Wilkinson reported that the sera of four patients suffering from SCLC and sensory neuronopathy harbored antibodies active against saline extracts of human brain and DRG by complement fixation assay. Cerebrospinal fluid samples from two of these patients were also antibody positive. In 1965 the first paraneoplastic antineuronal antibody was reported by Wilkinson and Zeromski [3]. Graus et al. [4] in 1985 described the anti-Hu immunoglobulin G antibody in immunohistochemical preparations and yielded bands in the 35–40 kD region on

DRG = dorsal root ganglion

PSN = paraneoplastic sensory neuropathy

PEM = paraneoplastic encephalomyelitis

Hu abs = anti-Hu antibodies

SCLC = small cell lung carcinoma

Western blot analysis of proteins from cerebrocortical neurons, serum and CSF of patients with SCLC and sub-acute sensory polyneuropathy. They designated the antibody by the first two letters of their index patient's last name, Hu. The presence of circulating antineuronal antibodies with nuclear immunoreactivity was confirmed in additional investigations. Anderson and co-workers [5] demonstrated that anti-Hu abs correspond to IgG in the sera and CSF of patients with SCLC and encephalomyelitis complex, including bulbar and cerebellar dysfunction, myelopathy, limbic encephalitis and autonomic failure.

The Hu antigens

Hu antigens are 35–40 kD proteins expressed mainly in the nucleus (Hu proteins, Nova) but also in the cytoplasm (CDR, Tr, Ulip, amphiphysin) of all neurons of the central and peripheral nervous system as well as in the underlying tumor [6]. Normal non-neural tissues assayed for Hu expression have been negative, except for isolated cells of probable neuronal lineage in the adrenal medulla and bronchial mucosa. They can also be expressed by the testes. The principal Hu antigens in humans are: HuD, HuC, and Hel-N1, each containing three RNA recognition motifs, and 86–90% of them are identical to each other. Others are HuR, Hel-N2 and ple21. HuC and ple21 cDNAs show a very high degree of identity and may in fact correspond to a single gene. HuD was the first one to be described: it is encoded by a gene mapped to the short arm of chromosome 1 and has a molecular mass of approximately 42 kD and the presence of three RNA-binding domains. HuD, HuC and Hel-N1 expression is restricted to neurons. HuR is expressed in extraneuronal tissues.

The Hu antigens in humans constitute a family of similar proteins that could be analogous to the *Drosophila* protein Elav (embryonic lethal abnormal visual system), which is required for normal development and maintenance of the fly's eye and nervous system [7,8]. HuD has extensive sequence homology (51% identity) with Elav. Furthermore, mutation of the Elav gene prevents development of the *Drosophila* nervous system. Early expression of the Hu antigens occurs in vertebrate neurogenesis and they bind to the AU-rich (ARE) element resident in the 3'-untranslated region of the mRNA (c-myc, c-fos, Gap43 and GM-CSF) that regulates cell proliferation. Although not present in neuroblasts, Hu proteins first appear in early lineage neurons that are still capable of proliferation. Marusich and Weston [9] reported that the antigen is the first identifiable marker of neuronal maturation in quail, appearing when E2 neuroblasts become committed neurons. Thus they appear to be the earliest marker of neuronal commitment in CNS-stem cells. The exact function of Hu proteins remains unknown, but it has been postulated that they act as transactors involved in selective mRNA degradation and likely

promote differentiation and maintenance of the neuronal phenotype. Hu-related antigens can be detected in both the nucleus and the membranes of most SCLC and in 50–78% of neuroblastomas [10]. HuD, HuC and Hel-N1 have been found in patients with anti-Hu-associated PEM-PSN [11].

The Hu antibody, immune response and neuropathology

Anti-Hu associated PSN-PEM is an immune disorder in which both cell-mediated and humoral mechanisms are involved [Figure 1]. While SCLC is more common in men than in women, with ratios ranging from 1.8:1 to 3:1, the anti-Hu syndrome is more common in women, as are other autoimmune disorders.

Humoral response

Hu antibody

Hu abs belong to the IgG family. Anti-Hu is a polyclonal, complement-fixing IgG, predominantly of the IgG1 subclass [12]. Originally named anti-Hu by Graus et al. [4], these antibodies have also been called type IIa neuronal antibodies and type 1 antineuronal nuclear antibodies [12]. The terminology for antibodies in paraneoplastic syndromes proposed by Lennon in 1989 was ANNA (antineuronal nuclear antibody) and PCAb (anti-Purkinje cell cytoplasmic antibody). After Anti-Ri was characterized, Lennon now proposes the addition of numbers. Depending on the pattern of reactivity on different animal tissues, ANNA becomes ANNA-1 (anti-Hu) or ANNA-2 (anti-Ri) and PCAb becomes PCA-1 [13] [Table 1]. They immunoreact with the Hu antigens present in the nervous system and neoplasms [14]. Hu abs also react with cells of the adenohypophysis, retina and adrenal cortex, and therefore are not exclusively an antineuronal nuclear antibody. ANNA-1 also react with Purkinje cells. According to immunochemical criteria alone, the anti-Hu antibody is also a Purkinje cell antibody and a paraneoplastic cerebellar degeneration antibody. Supporting elements (e.g., Schwann cells, vasculature, etc) are not recognized by the antibody.

Immune response

The exact role of Hu abs in the pathogenesis of the disease is unknown. It is thought that the expression of the Hu antigens by the tumor triggers a humoral immune response and a cell-mediated response that cross-react with the cells of the nervous system. This hypothesis is supported by the fact that the expression of each Hu antigen is found in all SCLC patients and in up to 78% of patients with neuroblastoma. Both tumors are of neuroectodermal origin. Anti-Hu sera react with HuD, HuC and Hel-N1, however from the three antigens only HuD is expressed in SCLC. Thus, it plays a main role in triggering the immune response.

ANNA-1 = antineuronal nuclear antibodies

PCA-1 = anti-Purkinje cell cytoplasmic antibody

CSF = cerebrospinal fluid

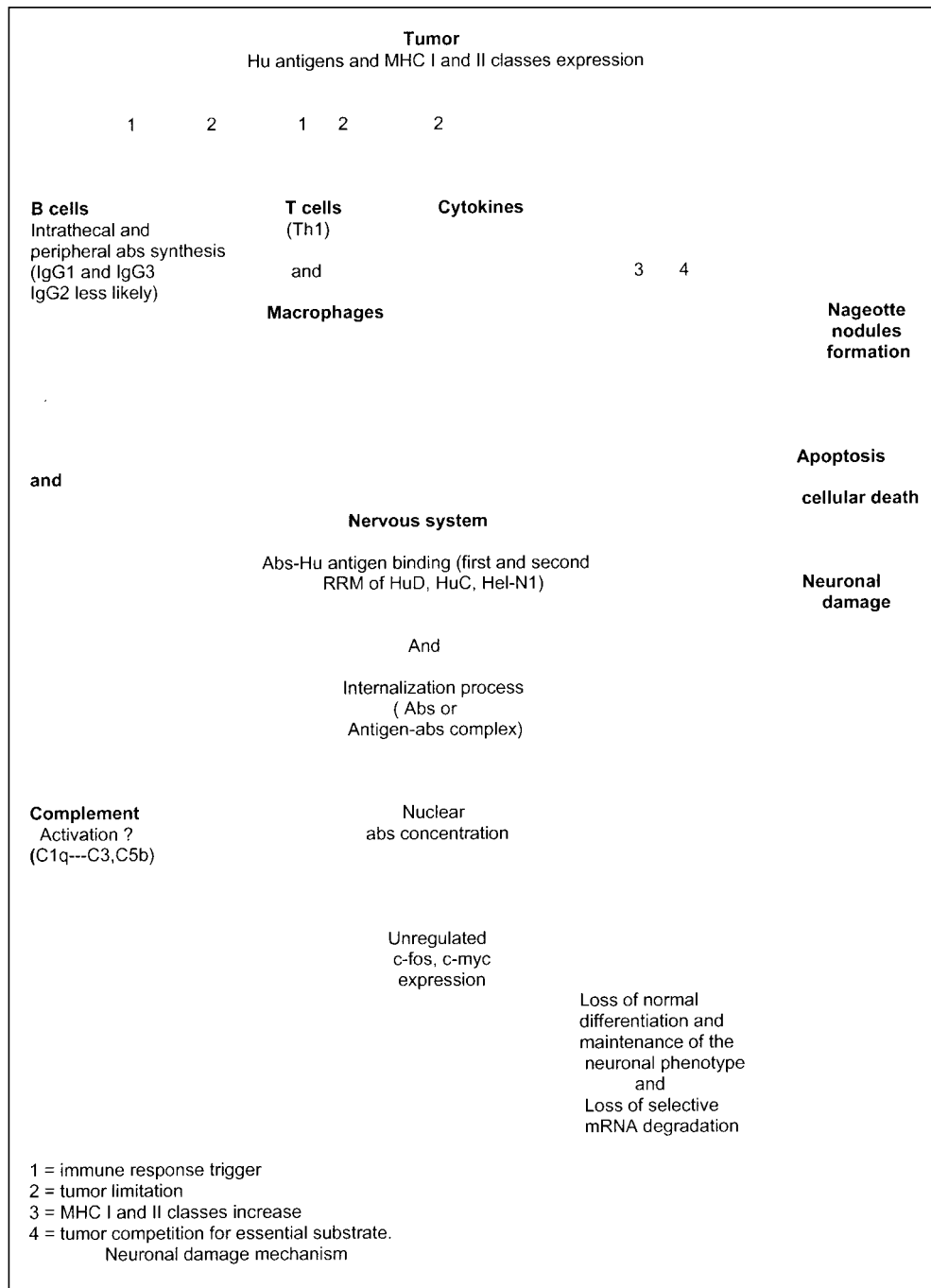


Figure 1. Neuropathogenesis of Anti-Hu syndrome

Antibody types. IgG1 and IgG3 are the predominant isotypes of the anti-Hu IgG in the serum, nervous system and tumor (particularly IgG1). A few patients also have IgG2. There is no correlation between specific IgG isotype or the reactivity of the Hu abs with HuD, HuC, Hel-N1 and neurological symptoms [15].

Antibody synthesis. Hu abs are synthesized intrathecally as well as peripherally. Furneaux et al. [16] demonstrated intrathecal

synthesis of Hu abs in six of seven patients with PEM/PSN. Plasmapheresis reduced the level of antibodies in serum without affecting that in the CSF. Vega et al. [17] showed that patients with PEM have higher intrathecal synthesis of Hu abs than patients with isolated sensory neuropathy. Hu abs are probably synthesized within the brain and perivascular spaces by B cells found in those areas. The presence of elevated intrathecal antibody synthesis has been suggested as a factor to explain the lack of clinical response to plasmapheresis or other immunosuppressive treatments. It is also possible that IgG is selectively transported from the serum into CSF, or that this transport occurs normally but antibody release from the CSF is prevented. However, there is no precedent for selective transport or reabsorption of normal IgG. The usual and logical explanation is that clones of B cells cross the blood-brain barrier and remain in the CNS to produce their antibodies. The presence within CNS of Hu-cognizant B cell clones would account for the fact that anti-Hu activity is consistently higher in CSF than in serum.

Antibody internalization. Immunohistochemical studies with intracellular staining revealed that in areas where the blood-brain barrier is broken the anti-

body migrates through the neurophil and finds its way into both glial cells and, to a greater degree, into neurons. Whether the internalization of IgG is a primary feature or secondary to the initial lesion of the neuron by other cause is presently unknown. Also, how antibodies enter the cell is an open question. One possibility is that antibodies enter at the synapse and are retrogradely transported to the cell body and finally concentrate in the nuclei. Another possibility is the internalization of the IgG via the neuronal cell body. An alternate mechanism is that the antigen represents a cell surface receptor and when the antibody binds to it, both antigen and antibody are internalized.

Table 1. Paraneoplastic antibodies, their associated cancers and neurological findings

Antibody	Antigen, Western blot molecular mass (kD)	Onconeural antigen	Associated tumor	Syndrome
Anti-Hu ANNA-1 Type IIa*	All neuronal nuclei, adenohypophysis, adrenal cortex, retina, testes 35-40	HuD, HuR HuC/ple21 Hel-N1	SCLC, SCGC, lung adenocarcinoma, neuroblastoma, prostate and thymic carcinoma, HL, rhabdosarcoma, synovial sarcoma, seminoma and NSTGCT	PSN-PEM
Anti-Yo PCA-1** Type-1	Purkinje's cytoplasm, 34, 62 52 58	CDR34 CDR62-1, 62-2 PCD17 CZF	Gynecological, breast, lung (adenocarcinoma)	PCD
Anti-Ri ANNA-2 Type IIb	Neuronal nuclei CNS, retina, 55, 80	Nova1, Nova2	Breast, gynecological, SCLC	Cerebellar ataxia, psoclonus
Anti-Ta	Neuronal nuclei and cytoplasm, 40, 50	Ta (Ma2)	Testicular	Limbic encephalitis, brainstem dysfunction
Anti-Ma	Neuronal nuclei and cytoplasm, 37, 40	Ma1, Ma2	Multiple (colon, breast, lung, parotid gland)	Cerebellar, brainstem dysfunction
Anti-CAR	Retinal photoreceptor, 23	Recoverin	SCLC, others	Photoreceptor degeneration
Anti-amphiphysin	Synaptic vesicles, 128	Amphiphysin	Breast, SCLC	Stiff-man syndrome, PEM
Anti-VGCC	Presynaptic VGCC	Alpha1 subunit	SCLC	LEMS
Anti-VGKC	Several VGKC (peripheral nerves, central neurons, glia, DRG.	Alpha subunit of several VGKC	Thymoma, SCLC, others	Neuromyotomia (Isaac's syndrome)
Anti-CV2	Glia (subset), 66	POP66	SCLC, thymoma, others	PEM, PCD
Anti-MysB	Presynaptic VGCC	Beta subunit VGCC	SCLC	LEMS
Anti-Tr	Cytoplasm neurons and Purkinje's spiny dendrites	In progress	HL, NHL	PCD.

* Greenlee et al. [39] use the names "type IIa antineuronal antibodies" for ANNA-1 reactivity, "type I antineuronal antibodies" for PCA-1, and "type IIb antineuronal antibodies" for ANNA-2.

** Most PCA-1 are probably the anti-Yo antibodies

CAR = cancer-associated retinopathy, CNS = central nervous system, DRG = dorsal root ganglia, HL = Hodgkin's lymphoma, LEMS = Lambert-Eaton myasthenic syndrome, NHL = non-Hodgkin's lymphoma, NSTGCT = non-seminomatous testicular germ cell tumors, PCD = paraneoplastic cerebellar degeneration, PEM = paraneoplastic encephalomyelitis, PSN = paraneoplastic sensory neuropathy, SCGC = small cell gallbladder carcinoma, SCLC = small cell lung cancer, VGCC = voltage-gated calcium, VGKC = voltage-gated potassium channel.

(The above text corresponds to the figure legend)

HuD and Hel-N1 do not contain any hydrophobic stretch suggestive of a transmembrane domain; in contrast, HuC/ple21 and Hel-N2 contain a hydrophobic stretch that could correspond to a transmembrane domain. Similarly, sequences of Elav and Rbp-9 contain hydrophobic stretches. The internalization process has a duration of one hour by SCLC cell lines.

Antibody attack. The anti-Hu immune response is directed towards two separate domains with at least two distinct epitopes. They bind to the first and second RRM of HuD, HuC and Hel-N1 but not HuR. For HuD the first and second RRM are essential for RNA binding. Thus, it has been suggested that Hu antigen inhibition by Hu abs might lead to unregulated expression of c-fos and c-myc, which in turn could result in cell death or apoptosis.

Complement response. Although IgG1 and IgG3 activate complement (they can bind C1q), only weak complement reactivity is found. Graus and colleagues [11] did not identify natural killer cells or deposits of complement C3 in the inflamed sensory ganglia and medulla of a patient with Hu abs-associated PEM-PSN. Neither did Jean et al. [12] identify NK cells and small amounts of complement in a few areas of the nervous system of four patients. After uptake of the antibody by rat granule cells, a neuronal destruction occurred and complement was not required, however its presence accelerated the neuronal damage. This supports the notion that complement-mediated toxicity antibody-dependent cell cytotoxicity mediated by NK cells has a minor role in PEM-PSN. An alternative would be that complement has a role but the fractions C3 or C5b can be detected immunohistochemically only for a short time.

RRM = RNA recognition motifs

NK = natural killer

Cellular response

Cellular immune response has been suggested [18] for the following reasons:

- Presence of extensive infiltrates of T cells in the nervous system.
- T cell proliferation in the tumor.
- Most tumors express major histocompatibility complex proteins, which indicate the need for antigen presentation to T cells, whereas MHC class I proteins are rarely expressed in SCLCs that are not associated with paraneoplastic syndromes.
- Passive transfer experiments do not provide evidence in favor of antibody-mediated disease alone. The transfer of Hu abs to animals does not reproduce the disease [19]. Furthermore, animals immunized with HuD develop antibodies but not symptoms. Thus, a cytotoxic mechanism may explain the difficulties in creating an animal model of the disorder by passive transfer of Hu abs.

MHC proteins: antigen presentation to cytotoxic T cells and tumor limitation

Hu is normally restricted to cells that do not express MHC antigens requisite for the triggering of immunological responses. Hu may be sequestered from the maturing immune system during the establishment of self-tolerance. Genetically determined variation in individual immunoresponsiveness, differences in Hu structure among neoplasms, or failure of all but a few small cell carcinomas to express Hu in association with MHC class I antigens can determine the different Anti-Hu responses [20]. Probably there is a greater surface expression of MHC class I and II by tumors associated with anti-Hu syndrome. Neuronal damage induced by antibodies or cytokines can result in this greater expression of MHC molecules. The development of the anti-Hu immune response may depend on the ability of the tumor to present the antigen to the immunological system, because there is a correlation between the expression of both MHC class I and Hu antigens and the development of this immune response. Co-expression of HuD and MHC class I proteins can be present and correlate with PSN-PEM. MHC class I molecule expression appears restricted to non-neuronal satellite cells, endothelium, perivascular lymphocytes and process-bearing elements morphologically consistent with microglia, and exhibits intense labeling with antibodies to HLA-DR. They are required for the presentation of viral or tumor neoantigens to cytotoxic T lymphocytes. A direct attack on the neuron by cytotoxic T lymphocytes sensitized to Hu would presumably require its surface display in association with MHC class I antigens. However, membrane expression is not a prerequisite for T cell recognition. Local MHC class II expression is greatly amplified and may contribute to the anti-Hu immune response.

IL-2 = interleukin 2

IFN γ = interferon-gamma

Tumor limitation

The immune response limits tumor spread. However, while most animals immunized with HuD cDNA showed smaller tumor volumes or rejection of the tumor, they did not develop neurological symptoms. This model is closest to the phenomenon observed in SCLC patients with low titers of Hu abs and no neurological deficits. The likely explanation for the tumor limitation in patients with paraneoplastic syndromes has a genetic basis that is closely related to MHC molecules. Neoplasms with low or no expression of MHC class I proteins have a growth advantage and increased metastatic potential. In this way, SCLC and neuroblastoma usually have low or no expression of MHC class I and have widely metastatic properties, with the exception of those patients with a paraneoplastic syndrome. In the series of Dalmau et al. [21] systemic metastases were detected in only 5 of 15 autopsied patients; the tumor was mostly confined to the chest when it was diagnosed (96%), with metastases outside the chest in only 2 patients (4%). The belief that paraneoplastic tumors are more indolent may represent an artifact, since a search for the tumor many months previously would have revealed it. The frequent neurological death limits evaluation of the natural history of the tumor and this hypothesis. A mild immune response is a good tumor prognostic factor, but an intense immune response is associated with severe neurological disease that often causes death.

T cell infiltrates can be part of a specific immune response or can result from a non-specific attraction by a pro-inflammatory environment. In the latter case one would expect to find all Vbeta families of T cell receptors with no clear predominance of any particular one. In the work of Voltz and colleagues [22], the lack of representation of some Vbeta families in the nervous system of five patients and over-representation of certain Vbeta families in three patients indicate that the T cell response is specific. Thus, T lymphocytes are specifically targeted to neuronal and tumor antigens, where they recognize this specific antigen and proliferate. Antigen-specific proliferation in peripheral blood mononuclear cells is much higher in seropositive patients. The ability of the IgG1 and IgG3 to bind Fc receptors may play role in the recruitment of monocyte/macrophage cells since they are the only two subclasses of IgG for which there exist specific receptors on monocytes/macrophages. However, aggregated IgG did not inhibit antibody binding to tumor cells, leaving uncertain the possibility that these interactions result from Fc-mediated antibody binding. There is an increase of memory helper T cells in anti-Hu seropositive patients. HuD protein stimulates peripheral blood mononuclear cells *in vitro* with a significant increase of memory helper (CD45RO+ CD4+) T cells and increased interferon-gamma/interleukin 4 ratio [22]. CD4+ cells can be Th1 and Th2 subtypes. Th1 cells secrete IL-2 and IFN- γ , activate macrophages and are responsible for delayed-type hypersensitivity, whereas Th2 cells produce IL-4, IL-5, IL-10 and IL-13 and thus favor IgE

MHC = major histocompatibility complex

Table 2. Clinical manifestations of Anti-Hu syndrome in two studies (%)

Symptom	Dalmau et al. [21] (n = 71) (%)	Voltz et al. [24] (n = 173) (%)
PSN	59	69
PEM/seizures	21	16
Autonomic dysfunction	10	10
Cerebellar dysfunction	13	23
Brainstem dysfunction	11	11
Motor weakness	14	14

production and suppress cell-mediated immunity. The distinction between Th1 and Th2 types relies on the IFN γ /IL-4 ratio. A significant increase in the IFN γ /IL-4 ratio suggests that HuD protein is an antigenic target for autoreactive CD4⁺ T cells, presumably of the Th1 type. This explains the predominance of Ig1 and Ig3 isotypes. Activated CD4 Th1 cells induce a direct cytotoxic effect, possibly through the induction of apoptosis. Moreover, an antigen-driven oligoclonal CD8⁺ cytotoxic T cell expansion due to an oligoclonal *in situ* expansion is involved in pathogenesis.

Other damage mechanisms

The tumor may compete with the nervous system for an essential substrate (glucose, tryptophan) and result in neurological dysfunction. Synthesis of hormone-like substances and secretion of cytokines (IL-1, IL-6, tumor necrosis factor-alpha) can participate in pathogenesis.

Neuropathology

The term sub-acute sensory neuronopathy is actually a misnomer since the pathological substrate is a dorsal root ganglion. Animals injected intraperitoneally with human IgG showed deposits of IgG in the interstitium of the DRG whereas the CNS was negative. There were deposits of IgG in the neurons and some glial cells of medulla and DRG of affected patients but not in the frontal cortex and medulla of controls. Thus, DRG was the initial target in 70% of patients [11]. This is due to the partial absence of the blood-brain barrier in the normal DRG. There is a distinct infiltration pattern. Inflammatory infiltrate comprises CD19⁺ (B cells), CD4⁺ (helper/inducer) cells in the perivascular spaces, CD8⁺ CD11- (cytotoxic/suppressor) cells in the interstitial spaces surrounding neurons, and less frequently plasma cells in the perivascular space. The failure of most CD8-positive cells to express the CD11 epitope suggests that these are mainly of the cytotoxic, rather than suppressor class. Also, there are infiltrates of EBM11⁺ (monocyte/macrophage) in the perivascular (macrophage phenotype) and interstitial (microglial) spaces. Associated neuronal loss and gliosis occur, and ganglion cells are replaced by reactive proliferations of satellite (capsular) cells known as nodules of Nageotte, resulting in dorsal root degeneration. Nerve biopsy reveals axonal neuropathy. In myenteric plexi a comparable inflammatory assault is responsible for gastrointestinal paresis, damage to the sympathetic ganglia and the intermediolateral cell column, leading to

dysautonomia. The central components reflect an inflammatory insult to the neuron at the level of its perikaryon. The effect has a predilection for the medial temporal lobes (hippocampi and amygdaloid nuclei), brainstem and anterior horns of the spinal cord, that correlate with limbic encephalitis, bulbar dysfunction and motor neuron disease respectively. Macroscopic evidence of injury results in brownish discoloration and contraction of the hippocampal formation, and advanced cerebellar cortical degeneration with shrinkage folia. The distribution of the more severe tissue alterations corresponds to the particularly symptomatic regions of the nervous system.

Clinical issues

Patients are considered affected by anti-Hu associated PSN-PEM when they develop clinical signs and symptoms of CNS dysfunction and/or sensory neuropathy not caused by metastases or other disorders, and Hu abs-positive serum or CSF.

Neoplasms associated with anti-Hu syndrome

SCLC has been found in more than 90% of patients with cancer and positive Hu abs. However, other malignancies have been described to cause PEM-PSN and high titer Hu abs; for example, exceptional cases of carcinoma of the lung, thymic carcinoma, synovial sarcoma, Hodgkin's disease, and non-seminomatous testicular germ cell tumors. We have encountered a case of a woman with a PSN associated with a small-cell carcinoma of the gallbladder (in press). In their series Dalmau et al. [21] found SCLC in 77.5% of patients – one had adrenal tumor, one had lung adenocarcinoma, one had chondromyxosarcoma, two had prostate carcinomas, and one had neuroblastoma. The presence of low titer antibodies is associated with limited cancer stage, a complete response to chemotherapy, and longer survival.

Clinical manifestations

Individual patients with Hu abs associated with SCLC may suffer from PSN-PEM, limbic encephalitis, brainstem encephalopathy, opsoclonus-myoclonus, paraneoplastic cerebellar degeneration or myelopathy according to the classification of Henson and Urich [23]. The onset of neurological symptoms in PSN-PEM generally begins between 6 months and 3.5 years before the detection of the tumor (median time 4 months). On the other hand, the tumor was diagnosed before the onset of neurological symptoms in 12% of patients. In Dalmau's series [21] of 71 serologically confirmed cases the disorder was more frequent in women (55%) and the median age at onset was 60 years, but the syndrome can also develop in childhood (the youngest patient was a 4 year old girl with neuroblastoma and bulbar dysfunction). Neurological manifestations preceded the detection of tumor in 83% of patients. Multifocal involvement was more frequent than unifocal (73% vs. 27%). In another large series of 173 patients with anti-Hu syndrome and pathologically confirmed SCLC, 31% had more than one presenting symptom [24] [Table 2].

PSN

Sensory neuropathy is the most common manifestation and is often the dominant feature (59% in Dalmau's series and 69% in Voltz's analysis). Symptoms are relatively pure, including the most common ones like anesthesia, paresthesias and dysesthesias of the distal extremities, proprioceptive and nociceptive sensory loss. Asymmetry is common. In a minority of patients the sensory symptoms at onset were restricted to the trunk or face, while back and/or radicular pain and flexor spasms were described by others. The sensory symptoms can evolve suddenly, but more frequently erupt in a sub-acute fashion that progresses relentlessly, often to total deafferentation and absence of muscle stretch reflexes in a matter of weeks or months. Reflexes could be abolished or increased. Severely affected patients cannot walk, stand or sit unsupported and may be unable to feed themselves despite unimpaired motor function. In the Mayo Clinic series the most affected area was the upper limbs (15 or 27 patients). Sensory ataxia was severe and disabling. The probable reason for sub-acute sensory neuropathy being the dominant manifestation is that dorsal root ganglia are readily accessible to large circulating molecules, whereas access to the central nervous system is restricted by the blood-brain barrier.

In order to obtain a precise diagnosis it is important that the physician follow a logical order when encountering a PSN patient. The exact kind of neuropathy should be categorized and differentiated from other causes of ganglionopathy such as Sjogren's syndrome, the use of cisplatin or vincristine and its analogues, vitamin B6 toxicity, HIV-related sensory neuropathy and idiopathic sensory neuropathy. Although most of the symptoms are sensory there might be other neurological manifestations.

PEM and limbic encephalitis

In Dalmau's series [21], 41% of patients had extrasensory abnormalities characteristic of PEM. These researchers reported symptomatic autonomic dysfunction in 10% of patients, seizures in 26%, brain stem dysfunction in 11%, myelitis in 14% and ataxia in 13%. In Voltz's analysis, motor incoordination, tremor or ataxia was found in 23%, limbic encephalopathy in 16%, motor weakness, fasciculations, hypo- or hyperreflexia in 14%, dysphagia, dysarthria, ocular paresis or opsoclonus in 11%, and autonomic dysfunction in 10%. PEM and PSN are different manifestations of the same nosologic process. Limbic encephalitis is the second most common clinical manifestation of anti-Hu syndrome in some series (autonomic dysfunction in others). This is characterized by confusion, disordered affect, cognitive decline and short-term memory loss. Some experience hallucinations, others have symptoms indicative of complex partial seizure activity. Limbic symptoms were presented in 21% of Dalmau's series [21].

Brainstem encephalitis

Brainstem encephalitis is manifest as diplopia, oscillopsia, dysarthria, dysphagia, supra- and internuclear gaze abnormalities, sensorineural deafness and facial numbness or palsy.

Evidence of cerebellar dysfunction (25%) includes ataxia, intention tremor, uncoordination, diminished muscle tone, nystagmus and scanning speech. Brainstem dysfunction was present in 32% of patients.

Motor neuron involvement

Present in 14% of patients, motor neuron involvement is reflected by an asymmetric pattern of loss of strength in the proximal extremities that spreads distally and is associated with muscle atrophy and fasciculations. Abnormal pseudoathetotic involuntary movements of the hands and fingers were a common finding. Denervation of the intercostal muscles may result in a fatal hypoventilatory syndrome. Thus, motor weakness should not be considered an exclusion criterion due to concomitant involvement of the motor neurons [25].

Autonomic failure

Found in 28% of Dalmau's patients [21], autonomic failure results in orthostatic hypotension, abnormal pupillary responses, urinary retention, gastrointestinal paresis, hyperhidrosis, impotence, cardiac arrhythmias, and chronic intestinal pseudo-obstruction due to neuronal destruction of the myenteric plexus neurons. The frequency of autonomic manifestations varies between the different series.

Opsoclonus-myoclonus

Hersh and co-workers [26] reported a case of opsoclonus-myoclonus and Hu abs. However, in some opsoclonus-myoclonus patients the detection of Hu abs may be coincidental or part of two paraneoplastic syndromes. There are previous reports of association between two different paraneoplastic syndromes (i.e., Lambert-Eaton myasthenic syndrome and anti-Hu associated PSN-PSM).

Prognosis

The course of the disease is usually not regressive, with the exception of a few cases of limbic encephalitis. The prognosis is poor and the median survival is 7 months (range 1.5–34). Death is due mainly to cardiac arrest or cardiovascular collapse attributable to the autonomic dysfunction and respiratory failure secondary to motor neuron disease and bulbar dysfunction, rather than to widespread metastases. A paraneoplastic etiology should be considered in patients with indolent sensory neuropathies, particularly when the neuropathies are asymmetric and the arms are involved.

Laboratory, electrophysiological and radiological studies

Electrophysiological studies

The most common finding in electrophysiologic studies is reduced or abolished sensory potentials associated with normal or mild reduction of nerve conduction, absent H responses with normal motor conduction, F waves and electromyography implicating the DRG as the site of pathology. Signs of denervation such as fibrillation or increased amplitude of motor unit potentials were found in patients in Dalmau's series [21].

Lumbar puncture

CSF protein levels are usually elevated, 10–40 white blood cells can be found, oligoclonal bands can be positive, and there is intrathecal synthesis of antibodies

Radiological studies

Magnetic resonance imaging studies are abnormal in only a few patients. Limbic encephalopathy can course with increased signal areas on T2 in the medial temporal region, which revert to normal and probably represent an early inflammatory component. With progression of the disease, scarring and contraction of the temporal lobes eventually occur [27]. Computerized tomography scan is not sufficiently sensitive to detect these abnormalities.

Hu abs essays

There are two principal assays for the detection of Hu abs: immunohistochemistry [10] (using avidin-biotin peroxidase and immunofluorescence) and Western blot analysis [28] (to identify proteins of 35–40 kD molecular mass). The use of dilutions greater than 1:500 is preferable because reactivity at lesser dilutions is sometimes associated with non-specific glial staining. Hu abs have a specificity of 99% and sensitivity of 82% in detecting paraneoplastic neurological syndromes [29]. Some antibodies with ANNA-1 reactivity are not Anti-Hu. Lovblad et al. [30] found 10% false-positive anti-Hu sera using immunohistochemistry alone. Sera of Sjogren syndrome patients reacted with 38 kD on Western blots of rat cerebellar homogenate, resembling anti-Hu immunoreactivity, but there was no reaction with purified Purkinje cells or purified recombinant HuD protein. Moll et al. [31] found that antibodies of patients with Sjogren syndrome had a reactivity similar to Hu abs by immunostaining but no reactivity with HuD recombinant protein [18]. These findings demonstrate that there are at least two groups of patients with ANNA-1, one paraneoplastic and the other non-paraneoplastic. Because there are other antibodies with identical immunohistochemical characteristics but no specific tumor association, the presence of ANNA-1 (Hu abs seropositivity) in serum and CSF – particularly in patients with unknown cancer – must be studied either with a recombinant Hu protein or the combination of immunohistochemistry and Western blot analysis of HuD protein to detect false-positive results. PSN-PEM are not restricted to the tumors found by Dalmau's team [21]; they were also encountered in other neoplasms previously mentioned. Antibodies associated with the same neurological syndrome and, conversely, that the same antibody may be associated with different syndromes led to the concept of immunological phenotypic diversity. The titers of Hu abs correlate with the presence of paraneoplastic syndromes. SCLC associated with PSN-PEM harbors higher titers of antibody (> 1:1,000). A low titer was observed in up to 16% of patients with SCLC without paraneoplastic symptoms. However, even in patients with SCLC and paraneoplastic syndromes the Hu abs are not always found. Why some patients with SCLC have no detectable immune response (Hu abs or

PSN-PEM) can be explained by factors related either to the tumor (such as expression of MHC antigens, changes in the Hu protein antigen itself) or the host (sex or genetic factors that regulate the immunological makeup of the patient). The titers of Hu abs also correlate with the differentiation of neoplasms. Tumors that are poorly differentiated in PSN patients have higher titers, whereas patients without antibodies have well-differentiated tumors. Moreover, recombinant Fab fragment against Hu proteins has been used as an index of neuronal differentiation in human brain tumors.

In the presence of positive Hu abs a search for an underlying SCLC should be undertaken. This should include an initial bronchoscopy and CT scan or MRI of the chest and radiological studies every 6 months, as some positive results are provoked by cancers that successfully eluded the initial detection owing to their small size – only a few millimeters in diameter or of microscopic proportions. Reports of Hu abs-positive patients with sensory neuropathy who did not develop cancer after a follow-up period of 4 or more years are exceptional. However, the one patient with sensory neuropathy and anti-Hu antibodies who developed SCLC 7 years after the onset of the neuropathy emphasizes the need for a long follow-up before excluding the possibility of a paraneoplastic origin. It is important to mention that 17% of patients with no cause for sensory neuropathy after the initial evaluation developed a tumor in spite of the absence of Hu abs. For this reason, the detection of an underlying tumor in anti-Hu antibody-negative patients with sensory neuropathy should be similar to that recommended for patients with Hu abs and targeted at the lung. If a tumor other than SCLC is detected but does not express Hu antigens, the presence of a second neoplasm (probably SCLC) must be considered. Lucchinetti et al. [32] identified 14 patients with positive ANNA-1 associated with SCLC and previous diagnosis of cancer, thus the search for SCLC should not end on discovering a different neoplasm. In children the detection of Hu abs should direct the search primarily for neuroblastoma.

Other antibodies

Patients with PSN occasionally harbor autoantibodies against neuronal antigens other than the Hu family, such as amphiphysin, a neuronal 66 kD protein related to axon guidance and a 106 kD neural protein of unknown function. Amphiphysin antibodies were positive in 7 of 155 patients with SCLC and paraneoplastic neurological disorders [29]. Systemic autoantibodies – antibodies against DNA, centromeres, nRNP, Sn antigen, Scl-70, Ro(SS-A), La(SS-B), mitochondria, thyroid antigens, brush border antigen, parietal cells and rheumatoid factor – were found in 52% of patients with paraneoplastic neurological syndromes, compared with 16% in the cancer-only group [33]. In 25% of patients two or more antibodies were identified. In the subgroup of Hu abs-positive patients, 33% yielded systemic autoantibodies excluding antinuclear antibodies, or 67% including ANA. Four percent of patients with anti-Hu associated PSN-PEM also have anti-Ro antibodies in the

serum, characteristic of Sjogren syndrome. On the other hand, antineuronal antibodies were present in 55% of patients with Sjogren syndrome and major neurological complications and in 11% without this complication. The presence of antineuronal antibodies does not correlate with the presence of anti-Ro/SS-A, anti-La/SS-B or ANA. Sixteen percent of patients have positive p53 antibodies, but no correlation between this antibody and tumor prognosis was found.

Treatment

Two types of treatment are practiced: the first is to treat the cancer, the second is to suppress the immune reaction with the use of corticosteroids, cyclophosphamide, azathioprine, plasma exchange, intravenous immunoglobulin and immunoadsorption. With the exception of myasthenia gravis, LEMS, neuromyotonia, dermatomyositis and certain peripheral neuropathies associated with myeloma, treatment of paraneoplastic syndromes is generally unsatisfactory. Only 2 of 71 patients in Dalmau's series [21] showed a neurological improvement following steroid treatment. Both patients suffered from limbic encephalopathy. With vigorous immunosuppressive treatment (combining high doses of steroids, cyclophosphamide and immunoglobulin) no patient improved, 56% stabilized and 44% deteriorated in the study of Keime-Guibert et al. [34]. Oh and Dropcho [35] reported two severely disabled patients with PSN-PEM and Hu abs who improved after immunosuppressors, but some caution is necessary to interpret this finding because spontaneous improvement has also been described in the anti-Hu syndrome. Isolated case reports have shown partial remission following antineoplastic therapy with or without plasmapheresis in a few patients with PEM or PCD. On the other hand, antibody-negative patients with PCD or limbic encephalitis and SCLC had major remissions after antineoplastic therapy. Most patients with improvement after immunosuppressor treatment had exclusive involvement of the peripheral nervous system with sensory neuropathy, which leads to the suggestion that the lack of a blood-brain or blood-nerve barrier at the level of the DRG could facilitate the entry and action of immunosuppressors. The second possibility is the presence of an indolent form of the disease with spontaneous stabilization. Intravenous immunoglobulin treatment in paraneoplastic CNS syndromes associated with antineuronal antibodies was not effective in the study by Uchuya and co-workers [36], but stabilization occurred in 47.6% of patients.

The results of plasmapheresis are disappointing [37] despite the few enthusiastic reports of clinical responses. No patient improved with plasmapheresis (3 to 6 plasma exchanges over 1 or 2 weeks) in the study conducted by Graus's group [38], but 4 of 7 patients remained stable and autoantibody titers in serum dropped in all. The lack of response is due to irreversible

neuronal damage, and decreased antibody titer in serum but not in CSF due to elevated intrathecal antibody synthesis or antibody may not be responsible for the symptoms but may only be a marker of the disease. Because of neuronal cell loss, a beneficial treatment might not lead to clinical improvement but to stabilization only. For this reason, if the antibody is identified early one should consider vigorous immunosuppression with plasmapheresis and steroids or cyclophosphamide. However, patients with mild sensory symptoms of several months duration at the time of diagnosis should not be included in treatment protocols unless there has been a clear progression in the previous month, since it is possible that immune suppression produces a more rapidly growing tumor. In conclusion, patients whose condition is very mild and stable or those who have been severely disabled should not be treated with immunosuppressive therapy; they should receive, exclusively, antineoplastic treatment. On the other hand, patients with evidence of progressive disease, particularly those who are mildly disabled, should be considered for immunosuppressive therapy.

Finally, membrane Hu antigen expression may provide a suitable target for the use of monoclonal antibody-based diagnostic and therapeutic strategies.

References

1. Posner JB. Neurologic Complications of Cancer. Philadelphia: FA Davis Company, 1995.
2. Brain R, Henson RA. Neurological syndromes associated with carcinoma. *Lancet* 1958;2:971-5.
3. Wilkinson PC, Zeromski J. Immunofluorescent detection of antibodies against neurons in sensory carcinomatous neuropathy. *Brain* 1959; 88:529-38.
4. Graus F, Cordon-Cardo C, Posner JB. Neuronal antinuclear antibody in sensory neuronopathy from lung cancer. *Neurology* 1985;35:538-43.
5. Anderson NE, Roseblum MK, Graus F, Wiley RG, Posner JB. Auto-antibodies in paraneoplastic syndromes associated with small-cell lung cancer. *Neurology* 1988;38:1391-8.
6. Dalmau J, Furneaux HM, Roseblum MK, Graus F, Posner JB. Detection of the anti-Hu antibody in specific regions of the nervous system and tumor from patients with paraneoplastic encephalomyelitis/sensory neuronopathy. *Neurology* 1991;41:1757-64.
7. Robinow S, Campos A, Yao K, White K. The elav gene product of *Drosophila*, required in neurons, has three RNP consensus motifs. *Science* 1988;242:1570-2.
8. Robinow S, White K. The locus elav of *Drosophila melanogaster* is expressed in neurons at all development stages. *Dev Biol* 1988;126:294-303.
9. Marusich MF, Weston JA. Identification of early neurogenic cells in the neural crest lineage. *Dev Biol* 1992;149:295-306.
10. Graus F, Ribalta T, Campo E, Monforte R, Urbano A, Rozman C. Immunohistochemical analysis of the immune reaction in the nervous system in paraneoplastic encephalomyelitis. *Neurology* 1990;40:219-22.
11. Graus F, Elkouf KB, Cordon-Cardo C, Posner JB. Sensory neuronopathy and small cell lung cancer. Antineuronal antibody that also reacts with the tumor. *Am J Med* 1986;80:45-82.
12. Jean WC, Dalmau J, Ho A, Posner JB. Analysis of the IgG subclass distribution and inflammatory infiltrates in patients with anti-Hu associated paraneoplastic encephalomyelitis. *Neurology* 1994;44:140-7.
13. Lennon VA. Paraneoplastic autoantibodies: the case for a descriptive generic nomenclature. *Neurology* 1994;44:2236-40.
14. Dalmau J, Posner JB. Neurologic paraneoplastic antibodies (anti-Yo; anti-

ANA = antinuclear antibodies

LEMS = Lambert-Eaton myasthenic syndrome

- Hu; anti-Ri): the case for a nomenclature based on antibody and antigen specificity. *Neurology* 1994;44:2241-6.
15. Manley GT, Smith PS, Dalmau J, Posner JB. Hu antigens: reactivity with Hu antibodies, tumor expression, and major immunogenic sites. *Ann Neurol* 1995;38:102-10.
 16. Furneaux HM, Reich L, Posner JB. Autoantibody synthesis in the central nervous system of patients with paraneoplastic syndromes. *Neurology* 1990;40:1085-91.
 17. Vega F, Graus F, Chen QM, Poisson M, Schuller E, Delattre JY. Intrathecal synthesis of the anti-Hu antibody in patients with paraneoplastic encephalomyelitis or sensory neuronopathy: clinical-immunologic correlation. *Neurology* 1994;44:2145-7.
 18. Benyahia B, Liblau R, Merle-Beral H, Tourani JM, Dalmau J, Delattre J-Y. Cell mediated autoimmunity in paraneoplastic neurological syndromes with Anti-Hu antibodies. *Ann Neurol* 1999;45:162-7.
 19. Sillevs-Smith PA, Manley GT, Posner JB. Immunization with the paraneoplastic encephalomyelitis antigen HuD does not cause neurologic disease in mice. *Neurology* 1995;45:1873-8.
 20. Dalmau J, Graus F, Cheung NKV, Roseblum MK, Ho A, Canete A, Delattre JY, Thompson SJ, Posner JB. Major histocompatibility proteins, antiHu antibodies, and paraneoplastic encephalomyelitis in neuroblastoma and small cell lung cancer. *Cancer* 1995;75:99-109.
 21. Dalmau J, Graus F, Rosenblum MK, Posner JB. Anti-Hu-associated paraneoplastic encephalomyelitis/sensory neuronopathy. A clinical study of 71 patients. *Medicine* 1992;71:59-72.
 22. Voltz R, Dalmau J, Posner JB, Rosenfeld MR. T-cell receptor analysis in anti-Hu associated paraneoplastic encephalomyelitis. *Neurology* 1998; 51:1146-50.
 23. Henson RA, Ulrich H. Encephalomyelitis with carcinoma. In: *Cancer and the Nervous System. The Neurological Manifestations of Systemic Malignant Disease*. London: Blackwell Scientific Press, 1982:314-45.
 24. Voltz R, Graus F, Posner JB, Dalmau J. Paraneoplastic encephalomyelitis: an update of the effects of the anti-Hu immune response on the nervous system and tumour. *J Neurol Neurosurg Psychiatry* 1997;63:133-6.
 25. Forsyth PA, Dalmau J, Graus F, Cwik V, Roseblum MK, Posner JB. Motor neuron syndromes in cancer patients. *Ann Neurol* 1997;41:723-30.
 26. Hersh B, Dalmau J, Dangond F, Gultekin S, Geller E, Wen PY. Paraneoplastic opsoclonus-myoclonus associated with anti-Hu antibody. *Neurology* 1994;44:1754-5.
 27. Dirr LY, Elster AD, Donofrio PD, Smith M. Evolution of brain MRI abnormalities in limbic encephalitis. *Neurology* 1990;40:1304-6.
 28. Dalmau J, Furneaux HM, Gralla RJ, Kris MG, Posner JB. Detection of the anti-Hu antibody in the serum of patients with small cell lung cancer - a quantitative western blot analysis. *Ann Neurol* 1990;27:544-52.
 29. Molinuevo JL, Graus F, Serrano C, Rene R, Guerrero A, Illa I. Utility of Anti-Hu antibodies in the diagnosis of paraneoplastic sensory neuropathy. *Ann Neurol* 1998;44:976-80.
 30. Lovblad KO, Boucraut J, Bourdenet S, Burger D, Bernard D, Regli F, Steck AJ. Sensory neuronopathy and small cell lung cancer: antineuronal antibody reacting with neuroblastoma cells. *J Neurol* 1993;240:327-32.
 31. Moll JWB, Markuse HM, Pijnenburg JJJM, Vecht ChJ, Henzen-Logmans SC. Antineuronal antibodies in patients with neurologic complications of primary Sjogren's syndrome. *Neurology* 1993;43:2574-81.
 32. Lucchinetti CF, Kimmel DW, Lennon VA. Clinical, oncological, and serological profiles of patients seropositive for type I anti-neuronal nuclear antibody (ANNA-1, aka "anti-Hu"). *Neurology* 1994;44(Suppl 2):A156.
 33. Moll JWB, Hooijkaas H, van Goorbergh BCM, Roos LGE, Henzen-Logmans SC, Vecht CJ. Systemic and anti-neuronal auto-antibodies in patients with paraneoplastic neurological disease. *J Neurol* 1996;243:51-6.
 34. Keime-Guibert F, Graus F, Fluery A, Rene R, Honnorat J, Broet P, Delattre J-Y. Treatment of paraneoplastic syndromes with antineuronal antibodies (Anti-Hu, Anti-Yo) with a combination of immunoglobulins, cyclophosphamide, and methylprednisolone. *J Neurol Neurosurg Psychiatry* 2000;68:479-82.
 35. Oh SJ, Dropcho EJ. Steroid-responsive paraneoplastic encephalomyelopathy. *Neurology* 1990;40(Suppl 1):246.
 36. Uchuya M, Graus F, Vega F, Rene R, Delattre J-Y. Intravenous immunoglobulin treatment in paraneoplastic neurological syndromes with antineuronal autoantibodies. *J Neurol Neurosurg Psychiatry* 1996;60:388-92.
 37. Graus F, Vega F, Delattre JY, Bonaventura I, Rene R, Arbaiza D, Tolosa E. Plasmapheresis and antineoplastic treatment in CNS paraneoplastic syndromes with antineuronal autoantibodies. *Neurology* 1992;42:536-40.
 38. Graus F, Abos J, Roquer J, Mazzara R, Pereira A. Effect of plasmapheresis on serum and CSF autoantibody levels in CNS paraneoplastic syndromes. *Neurology* 1990;40:1621-3.
 39. Greenlee JE, Brashear HR, Rodnitzky RL, Corbett JJ, Digre KB. Fall in antineuronal antibody titers and improvement of neurologic deficit following tumor removal in paraneoplastic cerebellar degeneration. *Neurology* 1986;36(Suppl 1):334.

Correspondence: Dr. F. Vega Boada, Instituto Nacional de Ciencias, Medicas y Nutricion, Salvador Zubiran, Vasco de Quiroga 15, Deleg. Tlalpan 14000, Mexico D.F. Phone: (52-5) 573-1200 Ext 5052, Fax: (52-5) 424-1155, email: sentiesh@yahoo.com