

Rituximab for Refractory Childhood Autoimmune Hemolytic Anemia

David G. Motto MD PhD, James A. Williams MD and Laurence A. Boxer MD

Department of Pediatric Hematology/Oncology, University of Michigan, Ann Arbor, MI, USA

Key words: autoimmune hemolytic anemia, rituximab, monoclonal antibodies, Evan's syndrome

Abstract

Background: Chronic childhood autoimmune hemolytic anemia is an uncommon disorder that is associated with significant morbidity. Treatment with high dose steroids, splenectomy and frequent blood transfusions results in a myriad of complications including growth failure, bone demineralization, Cushing's syndrome, immunosuppression, and transfusional hemosiderosis.

Objectives: To investigate the efficacy of the monoclonal anti-CD20 antibody, rituximab, in treating children with AIHA.

Methods: Four children with chronic AIHA, including two with prior splenectomy, who were dependent on high dose steroids and refractory to other immunosuppressive regimens were treated with four to six weekly doses of rituximab at a dose of 375 mg/m².

Results: All four patients became transfusion-independent and were taken off prednisone completely. Adverse effects included infusion-related reactions that were mild, and infectious complications of *Pneumocystis carinii* pneumonia and varicella pneumonia.

Conclusions: Treatment with rituximab appears promising for refractory AIHA; it may obviate the need for prednisone and may result in sustained disease remissions in some patients.

IMAJ 2002;4:1006–1008

Rituximab, a monoclonal antibody used originally for the treatment of B cell malignancies, induces cell and complement-mediated cytotoxicity by binding to the CD20 antigen expressed on cells of the B lineage [1]. As rituximab also transiently depletes mature non-malignant B cells from the peripheral blood and bone marrow, there has been considerable recent interest regarding its use for the treatment of immune-mediated cytopenias such as idiopathic thrombocytopenic purpura, autoimmune hemolytic anemia, Evans' syndrome, pure red cell aplasia, and hemolysis due to cold agglutinin disease [2–7].

Chronic childhood autoimmune hemolytic anemia is an uncommon disorder, but when encountered often presents a therapeutic dilemma for the pediatric hematologist. When not adequately controlled, frequent transfusions may be required to maintain minimum hemoglobin levels, resulting in total body iron overload and need for chelation therapy. Often permanent indwelling catheters are placed to facilitate transfusions and laboratory testing, and chronic bilirubin elevation can cause gallstones and liver toxicity. Morbidity resulting from treatment is ubiquitous. Unfortunately, resistance to multiple immunosuppressive agents is common, and splenectomy in young children is not

desirable or consistently effective [8,9]. Chronic high dose corticosteroid therapy is frequently the only effective treatment option; however, there is an associated risk of serious adverse effects including growth retardation, Cushing's syndrome, bone demineralization, and immune suppression.

Patients and Methods

We describe our experience with the first four children with chronic AIHA to be treated with rituximab at the University of Michigan. The patients' characteristics are presented in Table 1. Prior to rituximab therapy, all patients were receiving daily high dose corticosteroids. In three patients numerous other aggressive immunosuppressive regimens had failed, and two patients had failed splenectomy. For all the patients, pre-treatment disease and treatment-related morbidity were significant. Patient 1 had growth retardation secondary to corticosteroids and was receiving human growth hormone. Patient 2, with Evan's syndrome, was receiving chronic blood transfusions, and had a history of frequent infections including chronic otitis media, recurrent pneumonia, and frequent oral and vaginal candidiasis. Patient 3 had a history of interstitial lung disease secondary to cyclophosphamide, femoral head avascular necrosis secondary to corticosteroid-induced osteopenia, depression, splenectomy, cholecystectomy, and was receiving chronic transfusions. Patient 4 was receiving chronic transfusions, and had a history of splenectomy, cholecystectomy, multiple fractures secondary to osteopenia, medication-associated seizures, recurrent zoster and pneumonia, hepatitis, and transfusional hemosiderosis.

Informed consent was obtained, and each patient received 4–6 weekly infusions of rituximab at a dose of 375 mg/m². In patient 2, a second course of four additional weekly infusions to treat autoimmune thrombocytopenia was started at the same dose 7 months later when the hemoglobin was normal.

Results

The infusions were well tolerated, and the adverse effects – fever, chills and flushing – were managed with acetaminophen and diphenhydramine premedication, and additional use of hydrocortisone as needed. Infectious adverse events included *Pneumocystis carinii* pneumonia in patient 4 during his weekly rituximab infusions; and varicella pneumonia in patient 1 occurring 5 months following his final rituximab infusion. These events prompted us to initiate both *P. carinii* pneumonia prophylaxis and monthly intravenous immunoglobulin infusions for every patient receiving

AIHA = autoimmune hemolytic anemia

Table 1. Patient characteristics and complications

Patient	Age (yr)	Disease duration (yr)	Associated conditions	Prior therapy	Pre-rituximab complications	Post-Rituximab complications
1	3.5	3		Prednisone x 3 yr	Severe growth delay	Varicella pneumonia
2	4	1.5	Evan's syndrome (thrombocytopenia and neutropenia)	Prednisone, vincristine, cyclosporine A, tacrolimus, azathioprine, IVIG	Chronic transfusions, Infusaport placement, recurrent otitis media, recurrent candidiasis, frequent pneumonia, peripheral neuropathy	
3	15	9		Prednisone x 9 yr cytoxan, splenectomy	Chronic transfusions, Infusaport placement, osteopenia, avascular necrosis, Interstitial lung disease, cholecystectomy, depression	
4	14	4		Prednisone x 4 yr cytoxan, vincristine cyclosporine A, tacrolimus, splenectomy	Chronic transfusions, Infusaport placement, osteopenia and fractures chronic pain, hepatitis, cholecystectomy medication-associated seizures, recurrent zoster, recurrent skin abscesses, frequent pneumonia	Varicella zoster <i>P. carinii</i> pneumonia

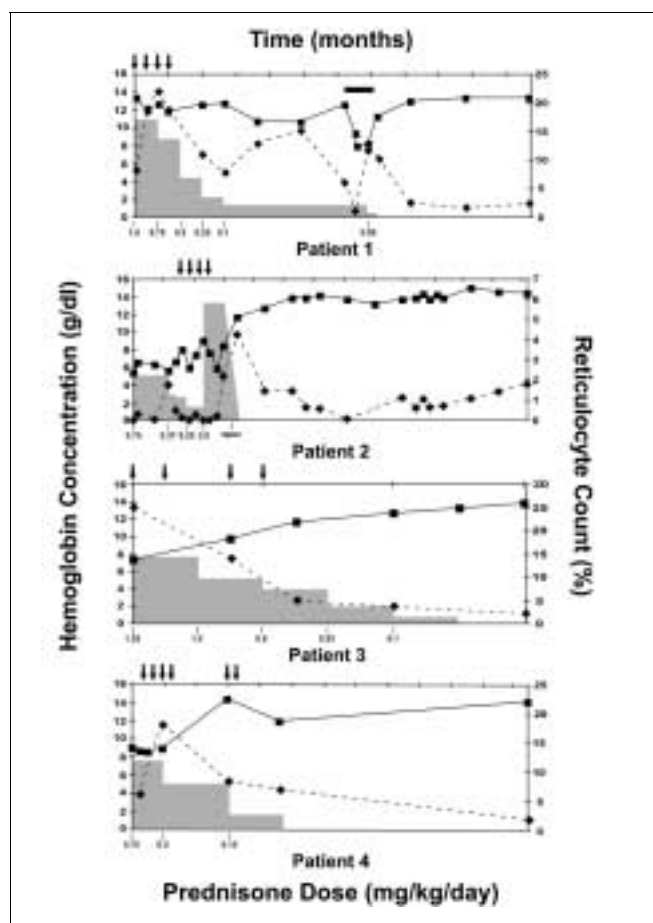


Figure 1. Evolution of hemoglobin concentration (solid lines), reticulocyte count (dashed lines), and prednisone dose (gray columns) following treatment with rituximab in four patients with AIHA. Arrows indicate rituximab doses. For patient 1, the solid bar indicates the timing and duration of his primary varicella infection.

rituximab, which we continue for a minimum of 6 months following completion of therapy.

All four patients became blood transfusion and steroid-independent. Responses to therapy are shown in Figure 1.

Discussion

These excellent results obtained with rituximab in the treatment of chronic AIHA are very encouraging. Although there is limited experience with rituximab in this disease and failures have occurred [10], our results are similar to those observed by others who used rituximab to treat pediatric patients [11,12]. Rituximab use may obviate the need for prednisone, and thus result in a reduced morbidity of Cushing's syndrome, growth failure, cataracts, osteopenia, aseptic necrosis, etc. Rituximab may also benefit as a possible splenectomy-sparing therapy. Reduction in blood transfusions will reduce the risk of transfusional hemosiderosis.

Potentially dangerous infectious complications are known to occur with rituximab [13], and, specifically, the *Pneumocystis carinii* and primary varicella pneumonia seen in our patients are likely related to the combined humoral and cell-mediated immunosuppression from long-term steroids and rituximab. For this reason, we recommend *P. carinii* pneumonia prophylaxis and intravenous immunoglobulin supplementation during the post-rituximab period for approximately 6 months until the hypogammaglobulinemia resolves.

References

- Onrust SV, Lamb HM, Balfour JA. Rituximab. *Drugs* 1999;58:79–88 (discussion 89–90).
- Stasi R, Pagano A, Stipa E, Amadori S. Rituximab chimeric anti-CD20 monoclonal antibody treatment for adults with chronic idiopathic thrombocytopenic purpura. *Blood* 2001;98:952–7.
- Abdel-Raheem MM, Potti A, Kobrinsky N. Severe Evans's syndrome secondary to interleukin-2 therapy: treatment with chimeric monoclonal anti-CD20 antibody. *Ann Hematol* 2001;80:543–5.

4. Faurschou M, Hasselbalch HC, Nielsen OJ. Sustained remission of platelet counts following monoclonal anti-CD20 antibody therapy in two cases of idiopathic autoimmune thrombocytopenia and neutropenia. *Eur J Haematol* 2001;66:408-11.
5. Ahrens N, Kingreen D, Seltsam A, Salama A. Treatment of refractory autoimmune haemolytic anaemia with anti-CD20 (rituximab). *Br J Haematol* 2001;114:244-5.
6. Zecca M, De Stefano P, Nobili B, Locatelli F. Anti-CD20 monoclonal antibody for the treatment of severe, immune-mediated, pure red cell aplasia and hemolytic anemia. *Blood* 2001;97:3995-7.
7. Patel K, Berman J, Ferber A, Caro J. Refractory autoimmune thrombocytopenic purpura treatment with Rituximab. *Am J Hematol* 2001;67:59-60.
8. Heisel MA, Ortega JA. Factors influencing prognosis in childhood autoimmune hemolytic anemia. *Am J Pediatr Hematol Oncol* 1983;5:147-52.
9. Savasan S, Warriar I, Ravindranath Y. The spectrum of Evans' syndrome. *Arch Dis Child* 1997;77:245-8.
10. Nowak-Wegrzyn A, King KE, Shirey RS, Chen AR, McDonough C, Lederman HM. Fatal warm autoimmune hemolytic anemia resulting from IgM autoagglutinins in an infant with severe combined immunodeficiency. *J Pediatr Hematol Oncol* 2001;23:250-2.
11. Mc Mahon C, Babu L, Hodgson A, Hayat A, Connell NO, Smith OP. Childhood refractory autoimmune haemolytic anaemia: Is there a role for anti-CD20 therapy (rituximab)? *Br J Haematol* 2002;117:480-3.
12. Quartier P, Brethon B, Philippet P, Landman-Parker J, Le Deist F, Fischer A. Treatment of childhood autoimmune haemolytic anaemia with rituximab. *Lancet* 2001;358:1511-13.
13. Sharma VR, Fleming DR, Slone SP. Pure red cell aplasia due to parvovirus B19 in a patient treated with rituximab. *Blood* 2000;96:1184-6.

Correspondence: Dr. D.G. Motto, L2110 Women's Hospital Box 0238, 1500 E. Medical Center Drive, Ann Arbor, MI 48109-0238, USA.
Phone: (1-734) 764-7127
Fax: (1-734) 615-0464
email: dgmotto@umich.edu

The pendulum of the mind oscillates between sense and nonsense, not between right and wrong

Carl G. Jung (1875-1961), Swiss psychiatrist and collaborator of Freud

Capsule

A gentler treatment for stroke

Although N-methyl-D-aspartate (NMDA) receptors play an important role in stroke, simply blocking them would lead to many unwanted side effects. Aarts et al. suggest a novel approach to treat ischemic brain injury without blocking NMDA receptors. They constructed peptides that bind to molecular domains governing the interaction of NMDA receptors with the post-

synaptic density protein PSD-95. Normal synaptic activity and the subsequent postsynaptic calcium influx remained intact but deleterious downstream neurotoxic signaling events were inhibited.

Science 2002;298:846

Capsule

Anti-inflammatory pathways generated with glucocorticoid and aspirin

Aspirin and dexamethasone are widely used anti-inflammatory agents yet their mechanism(s) for blocking polymorphonuclear neutrophil (PMN) accumulation at sites of inflammation remains unclear. Perretti et al. report that inhibition of PMN infiltration by aspirin and dexamethasone is a property shared by aspirin-triggered lipoxins (ATL) and the glucocorticoid-induced annexin I (ANXA1)-derived peptides that are both generated *in vivo* and act at the lipoxin A4 receptor (ALXR/FPRL1) to halt PMN diapedesis. These structurally diverse ligands specifically interact directly with recombinant human ALXR demonstrated by specific radioligand binding, and function as well as immunoprecipitation

of PMN receptors. In addition, the combination of both ATL and ANXA1-derived peptides limited PMN infiltration and reduced production of inflammatory mediators (that is, prostaglandins and chemokines) *in vivo*. Together, these results indicate functional redundancies in endogenous lipid and peptide anti-inflammatory circuits that are spatially and temporally separate, where both ATL and specific ANXA1-derived peptides act in concert at ALXR to down-regulate PMN recruitment to inflammatory loci.

Nature Med 2002;8:1296