

Listeria Infection during Pregnancy: A 10 Year Experience

Abraham Benschushan MD¹, Avi Tsafrir MD¹, Revital Arbel MD¹, Galia Rahav MD², Ilana Ariel MD³ and Nathan Rojansky MD¹

Departments of ¹Obstetrics and Gynecology, ²Microbiology and Infectious Diseases, and ³Pathology, Hadassah Medical Center (Ein Kerem and Mt. Scopus Campuses), Jerusalem, Israel.

Affiliated to the Hebrew University Medical School, Jerusalem, Israel

Key words: *Listeria monocytogenes*, pregnancy, infection, morbidity, mortality

Abstract

Background: Although *Listeria monocytogenes* is widely distributed in nature, it rarely causes clinical infection in previously healthy people. This microorganism, however, may cause severe invasive disease in pregnant women and newborns.

Objectives: To investigate – in our pregnant population – the impact, severity and outcome of listeriosis on both mother and fetus.

Method: The study was carried out at a level III, university two-hospital complex. In a retrospective chart review of 65,022 parturients during a 10 year period (1990–1999), we identified and evaluated 11 pregnant patients and their offspring with *Listeria* infection.

Results: Chorioamnionitis with multiple placental abscesses were observed in all five placentae examined. Clinically, 4 of 11 parturients had a cesarean section for fetal distress (36.3%), as compared to the 14% mean CS rate in our general population. Two of 11 had a late abortion (18.1%), as compared with the 4% rate in our hospital. Four of 11 had premature labor (36%), which was about four times the rate in our population. Finally, although no intrauterine fetal death was recorded in our series, there was one neonatal death of a term infant (1/11, 9%), which is about 10 times higher than our corrected perinatal mortality rate.

Conclusions: If not promptly and adequately treated, listeriosis in pregnancy may present serious hazards to the fetus and newborn through direct infection of the placenta and chorioamnionitis.

IMAJ 2002;4:776–780

For more than 60 years *Listeria monocytogenes* has been recognized as a human pathogen. It is a gram-positive non-spore-forming, facultative, anaerobic, motile bacillus capable of causing bacteremia and meningitis. *Listeria* causes clinical infections mainly in the elderly, in pregnant women and newborns, as well as in patients with severe immunosuppression such as AIDS, diabetes mellitus, and hepatic failure, patients on hemodialysis and treated cancer patients [1–3]. These microorganisms are widely distributed in nature and can be isolated from soil, water, vegetation and processed food. It can also be isolated from a variety of mammals, birds, fish, and insects and is frequently found in the feces of domestic and wild animals as well as humans.

The incidence of listeriosis among pregnant women is 17-fold higher than among the general population (12 per 100,000 vs. 0.7/100,000 respectively) [4]. At the Women and Infants Hospital in Providence, Rhode Island (USA), three cases of listeriosis were

identified from 1,300 perinatal autopsies performed over a 10 year period. It is estimated that 800 cases occur every year in pregnant women and fetuses in the United States. The rate in Britain is reportedly 1/18,000 live births [5].

Most cases of human listeriosis, including those seen during pregnancy, are sporadic, with a peak in incidence in the summer. The most likely reservoir for *L. monocytogenes* in humans is the gastrointestinal tract. The organism can be found in the feces of 70% of healthy people and 40% of pregnant women [6], although some authors have reported much lower rates among pregnant women, ranging from 1.1 to 3.9% [7,8]. The incidence of cervicovaginal colonization in healthy gravidas is much lower. The combined results of four studies with a total of 1,035 women yielded 1 positive culture, a rate of 0.097% [1]. Sporadic cases of perinatal listeriosis and local epidemics have been reported worldwide. These were associated with the consumption of contaminated food such as milk, soft cheese, coleslaw, undercooked meat, and unwashed raw vegetables. The perinatal case fatality rate ranged from 27 to 33% [9–11].

During the past 10 years 11 patients with listeriosis during pregnancy were diagnosed at the Hadassah Medical Center. We report our experience and discuss the clinical and pathologic implications of these cases.

Patients and Methods

Patients

During a 10 year period (1990–1999) 65,022 women were delivered at the Hadassah Medical Center, a level III referral facility in Jerusalem. Eleven of these women were identified as suffering from listeriosis in pregnancy, for an incidence of 1/5,911 parturients (0.015%). This is obviously not the true incidence of the disease in Israel since symptoms of the disease are very non-specific and the disease is probably under-diagnosed. A microbiology laboratory survey of all blood and placenta cultures positive for *L. monocytogenes* identified the study population. A retrospective chart review was conducted on all pregnant women and their offspring included in the study.

Methods

Blood cultures were performed by a radiometric method (Bactec 460, Becton Dickinson Diagnostic Instrument System, Sparks, MD, USA) until 1997 and later by a calorimetric method (Bact/Alert, OrganonTeknika, USA). *L. monocytogenes* was identified on the basis

CS = cesarean section

of Gram's stain, beta hemolysis, motility, catalase analysis and Voges-Proskauer positivity.

The placentas were submitted for pathologic examination fixed in 4% buffered formalin. Tissues were processed and embedded in paraffin and 5 μ sections were stained with hematoxylin and eosin.

Results

The dependent variables and outcomes of the 11 patients are shown in Table 1. In this small series 4 of 11 women (36.3%) had a cesarean section for fetal distress, as compared to the 15% CS rate in our general population. Four had premature labor (36%),

Table 1. Characteristics, clinical course, treatment and outcome of parturients with listeriosis

Case no.	Gestational age (wk)	Maternal age (yr)	Clinical presentation	Laboratory	Treatment	Pregnancy outcome	Pathologic examination
1	39	36	One week duration of general malaise, weakness & maternal fever up to 39°C	Normal leukocytes, positive blood cultures	IV ampicillin & gentamicin, induction of labor	Normal delivery of a healthy male baby weighing 3,390 g. Apgar score 9/10	Placental multiple microabscess
2	31	30	Premature uterine contractions followed by fever & rupture of membranes	19,270 leukocytes, positive uterine and placental cultures	Tocolysis & dexamethasone prior to signs of amnionitis, followed by IV ampicillin and gentamicin	Delivery by CS due to fetal distress and suspected amnionitis. Healthy female baby born weighing 1,730 g. Apgar score 9/10	Severe acute chorioamnionitis and placental abscesses, mainly subchorionic
3	29	24	One week duration of urinary symptoms & uterine contractions followed by fever	18,000 leukocytes, positive maternal blood cultures	IV cefuroxime replaced by ampicillin and gentamicin after receiving culture results	Spontaneous labor 24 hours after admission. Delivery by emergent CS due to fetal bradycardia. Male baby born weighing 1,680 g. Apgar score 2/4/7. Positive neonatal blood cultures for <i>L. monocytogenes</i> . Neonatal sepsis and death on day 3 due to multiorgan failure	Not examined
4	15	34	Fever, general malaise, chills	7,200 leukocytes, positive blood cultures	IV ampicillin for 3 weeks	Spontaneous labor at 39 weeks gestation. Delivery by CS due to non-reassuring fetal heart rate. Healthy neonate weighing 2,520 g. Apgar score 9/10	Not examined
5	37	37	Fever and myalgia of 1 week duration	Elevated liver functions, positive blood cultures	Post-partum IV ampicillin	Spontaneous normal vaginal delivery at 37 weeks gestation	Not examined
6	18	37	Fever and uterine contractions on day of admission	35,000 leukocytes, positive uterine cultures	IV clindamycin and gentamicin	Spontaneous late abortion	Fetus & placental blood vessels normal, acute chorioamnionitis
7	30	30	Premature contractions, fever, chest pain and cough	Positive placental culture	IV ampicillin, clindamycin and gentamicin	Spontaneous vaginal delivery on admission. Female newborn weighing 1,300 g, positive CSF cultures, normal long-term outcome	Not examined
8	18	29	2 weeks of fever and general malaise	6,300 leukocytes, positive blood cultures	IV ampicillin for 2 weeks followed by oral amoxicillin	Spontaneous normal vaginal delivery at 39 weeks. Healthy newborn weighing 2,900 g	Fibrin deposits 5% of placental surface, consistent with old abscesses
9	30	30	Chronic treatment with steroids due to SLE. Vaginal bleeding followed by fever and rupture of membranes	Positive uterine and placental cultures	IV ampicillin, clindamycin and gentamicin	Delivery by CS for fetal distress. Healthy newborn weighing 1,775 g. Apgar 7/9	Diffuse necrosis and multiple abscesses with involvement of membranes, normal vessels
10	36	23	None	Positive neonatal blood and CSF cultures	None	Spontaneous normal vaginal delivery, neonatal hypoglycemia and apnea, mild hypotonia in the first year of life, normal development on follow-up.	Not examined
11	17	27	Fever and missed abortion	33,000 leukocytes, positive cultures from D&C material	Penicillin and clavulonic acid followed by IV ampicillin, clindamycin and gentamicin	D&C	Severe inflammation

SLE = systemic lupus erythematosus, CSF = cerebrospinal fluid.

which was about four times the rate in our population. Finally, although no intrauterine fetal deaths were recorded in our series, there was one neonatal death of a term infant (1/11, 9%), which is about 10 times higher than our corrected perinatal mortality rate. Three of our more recent cases are described here in more detail, being representative of listeriosis course and outcome during pregnancy.

Case 1

A 36 year old pediatrician was admitted in the 39th week of her first pregnancy for general malaise, weakness and fever of up to 39°C that started a week earlier. Her past general and gynecologic history was unremarkable. On admission, her general physical examination revealed no findings and her vital signs were normal except for fever of 38°C. The fetus did well, as evidenced by ultrasound and non-stress test fetal heart rate monitoring with good variability and reactivity. Blood chemistry and urinalysis were normal and her hematology showed hemoglobin 12.1 g/dl, hematocrit 38%, white blood count 6,600 cells/L and blood type B rh+. A blood culture taken 2 days earlier revealed *Listeria monocytogenes*. Intravenous antibiotic treatment with ampicillin and gentamicin was immediately begun and labor was induced with vaginal prostaglandin. Eight hours later she gave birth to a healthy male baby weighing 3,390 g and with an Apgar score of 9/10. The baby underwent a full sepsis work-up that was normal, and he did well on follow-up. The patient was discharged after completing a week of IV antibiotics. The pathologic examination revealed a third-trimester placenta with multiple intervillous and intravillous micro-abscess compatible with *Listeria* infection [Figure 1].

Case 2

A 30 year old woman was admitted to the delivery room in the 31st week of her first pregnancy with premature contractions and preterm rupture of the membranes. Her past medical and gynecologic history was unremarkable. The course of the present pregnancy was normal until 3 hours prior to admission, when uterine contractions and urinary symptoms started, followed by rupture of the membranes. On admission, she had a fever of 38.3°C, was alert with normal vital signs and her general physical

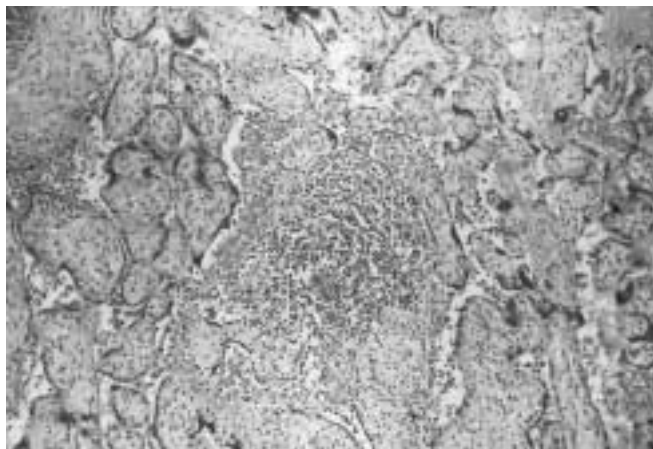


Figure 1. Placental abscess typical of listeriosis (original magnification x 40)

examination was normal. Gynecologic examination, however, revealed meconium-stained (+2) amniotic fluid and regular uterine contractions. On non-stress test a normal fetal heart rate pattern was observed. Ultrasound showed no abnormality of the placenta or the fetus. Laboratory tests showed hemoglobin 11.5 g/dl, hematocrit: 37%, and WBC count 19,270 cells/L, with biochemistry and urinalysis within normal limits. Treatment with tocolysis, dexamethasone and IV antibiotic treatment with ampicillin and gentamicin was initiated promptly. Twenty-four hours later fetal tachycardia with mild variable decelerations was observed, the leukocytosis persisted, and with a presumptive diagnosis of amnionitis and fetal distress the patient underwent a cesarean section. A female premature baby weighing 1,730 g with an Apgar score of 9/10 was delivered. Sepsis work-up of the newborn showed no abnormality. Cultures from the placenta and the uterus identified *Listeria*. The mother and newborn were treated with IV antibiotics for 2 weeks. The pathologic examination of the placenta revealed severe acute chorioamnionitis and placental abscesses, mainly subchorionic. It is of note that the premature neonate showed a leukemoid reaction that subsided only a few weeks later.

Case 3

A 24 year old woman was admitted to the delivery room in the 29th week of her third pregnancy complaining of decreased fetal movements. Her past general and gynecologic history was unremarkable, except for iron deficiency anemia, with two previous normal pregnancies and deliveries. The course of her current pregnancy was uneventful up to 1 week prior to admission when urinary symptoms appeared and urinary tract infection was diagnosed based on multiple leukocytes and Gram-positive cocci on urine examination. Oral treatment with macrodantin (500 mg 4 times a day) was initiated with only partial compliance.

On admission, except for pallor, the patient's physical examination was normal. Vital signs were normal and no fever was observed. The NST and ultrasound examination showed no abnormalities. Laboratory examination revealed a WBC of 16,500 cells/ml, hemoglobin 8.6 g/dl, hematocrit 28% and normal biochemistry and urinalysis. Four hours later she complained of dysuria and mild suprapubic tenderness, and her fever rose to 37.9°C; a repeated WBC count was 18,000 c/ml. Treatment with IV cefuroxime was initiated for suspected urinary tract infection after obtaining urine and vaginal cultures. The next morning her temperature was 37.4°C and the NST showed tachycardia with normal variability and no decelerations. Twenty-four hours following admission the patient complained of abdominal contractions. On vaginal examination the cervix was 2 cm dilated and a slight bloody discharge was noted. Tocolytic treatment with indomethacin and dexamethasone was started for suspected preterm labor complicating the urinary tract infection. Shortly after, her temperature rose to 38.8°C and the patient became restless and very irritable, complaining of painful premature contractions that were alleviated with nitrous oxide. NST was normal until sudden fetal bradycardia was observed. Emer-

WBC = white blood cell
NST = non-stress test

gency CS was immediately performed and a male newborn weighing 1,680 and covered with thick meconium was delivered. The Apgar scores were 2, 4, and 7 at 1, 5 and 10 minutes respectively, and cord blood pH was 6.75, with base excess minus 22. Both maternal and fetal blood cultures as well as a culture taken from inside the uterine cavity grew *Listeria monocytogenes*. Urine cultures were sterile. After treatment with ampicillin, gentamicin and clindamycin, the mother's general condition improved markedly and her temperature returned to normal. The newborn was intubated and ventilated immediately. He developed neonatal sepsis and gradually deteriorated, developing multisystem organ failure; he died 2 days later. An autopsy was not performed.

Discussion

We present here a series of 11 pregnant patients and their offspring infected with *Listeria*. Our small series, which is actually a collection of case reports, does not reflect the true incidence of listeriosis in pregnant women in Israel. However, it does show an increased rate of both prenatal and neonatal complications, which is in accordance with, albeit lower than, the few other small series reported in the English-language medical literature. Surprisingly, no maternal fatality occurred in our series and the perinatal complication rate was lower than that reported in the literature. This may be due to earlier diagnosis and treatment in our series.

L. monocytogenes infection has been a reportable disease in Israel since 1996. During a 5 year period (1995–99) 161 cases were identified in Israel: 70 perinatal infections (43%) and 91 non-pregnancy related (57%). The crude mortality rate in the non-pregnant population was 38% and the perinatal mortality rate 45% (unpublished data)

In 1981 an outbreak of listeriosis epidemic occurred in Nova Scotia, Canada. The source was a locally produced coleslaw [9]. Forty-one cases of listeriosis in pregnancy were reported, 34 of which were perinatal cases and 7 adult gravidas. There were 19 cases of intrauterine death and 27% of the infants who were born alive died. A second outbreak was reported from Massachusetts in 1983 [10], and the source of infection was identified as unpasteurized milk and its products. Of the 49 cases of listeriosis, 42 were in immunosuppressed adults and 7 cases were diagnosed in fetuses or neonates. The case-fatality rate was 29% in both the adult and the neonatal group. The largest epidemic occurred in Los Angeles in 1985 [11], where the source of infection was a contaminated, soft, Mexican-style cheese. During 8 months 142 cases of human listeriosis were reported, and of the 93 perinatal cases 95% were in pregnant Hispanic women. There were 29 fetal or neonatal deaths and a 33% case-fatality rate in the non-pregnant adults.

The depressed cell-mediated immunity during pregnancy might be one of the causes for the increased susceptibility to the organism. Being an intracellular organism, *Listeria monocytogenes* spreads from cell to cell without exposure to the extracellular environment. Thus, cell-mediated immunity is the primary line of defense against *Listeria*. The mode of transmission to the fetus is either transplacental via the maternal bloodstream, or less often, ascending from the birth canal [1].

The maternal clinical picture varies from no symptoms to a flu-

like disease, sometimes giving rise to urinary tract infection symptomatology. It seems that the development of preterm labor is not uncommon.

Neonatal disease has been described to take two distinct forms: early-onset disease caused by transplacental infection *in utero*, and late-onset disease probably acquired during the passage through the birth canal. The clinical characteristics are very similar to those caused by neonatal Group B *Streptococcus* infection. Early-onset disease is associated with high mortality (30–60%) unless diagnosed and treated promptly (see case 3). Onset of disease usually appears hours after birth or within a few days of life, with mean onset of neonatal symptoms at 1.5 days of life. Septicemia and involvement of the respiratory tract are the most common presenting symptoms [2]. In severe cases, widely disseminated micro-abscesses develop in the skin, liver, adrenals, spleen, lung and placenta. There is usually a maternal history of a bacteremic flu-like syndrome before the onset of labor [1,2]. Late-onset disease occurs 2 to 3 weeks after birth, with mean onset of symptoms at 14 days of life. Late-onset disease usually affects full-term infants of mothers with a history of normal pregnancy. The clinical manifestation is usually in the form of meningitis or meningoencephalitis with septicemia. In long-standing cases there is a mononuclear inflammatory response that has been described as "granulomatous." The reported neonatal mortality is up to 25%. The mode of acquisition probably occurs during passage through a contaminated birth canal [1,2]. Ultrasonic features resembling adult inflammatory conditions of the bowel were demonstrated in a case report of congenital listeriosis in a twin pregnancy [14].

Diagnosis requires culture of the organism from a sterile site. The identification usually takes 36 hours. Seven species of *Listeria* have been identified, but *Listeria monocytogenes* is the principal pathogen in humans and animals. There are several serotypes, including 1/2a, 1/2b and 4b, that are responsible for more than 90% of human infections. The bacteria grow well on most routine media when isolated from sterile sites. However, the organism may be difficult to isolate from mixed cultures such as vagina or rectum, or food products that may contain other bacteria. Therefore, selective media are recommended in these cases. Cold storage of the culture at 4°C will enhance the yield of the culture, since *Listeria* grows better at a low temperature, while the growth of competing bacteria will be inhibited. However, growth at a low temperature is slow, and it may take several weeks to identify the organism. Gram-stained preparations can be of help in the earlier stages. Interpretation can be difficult due to the bacterium's resemblance to other organisms. Selective immunohistochemical and serologic tests are used to definitively identify the pathogen [12]. Placental examination may reveal micro- and macro-abscesses and acute villitis, which strongly supports the diagnosis, although *Campylobacter* and streptococcal infections may occasionally exhibit similar histologic findings [12,13].

The treatment of choice for listeriosis is penicillin and ampicillin either alone or with gentamycin. Since *Listeria* is an intracellular organism, the response to treatment may be slow due to relatively poor cell penetration. Consequently, ampicillin treatment should be continued for at least 2 weeks. Erythromycin can be used in patients

allergic to penicillin. Trimethoprim-sulfamethoxazole is probably more effective due to its bactericidal activity and higher intracellular concentration, but it is relatively contraindicated during early and late stages of pregnancy [1,2]. Treating maternal listeriosis usually results in successful *in utero* treatment of the fetus [1,15]. The efficacy of prophylactic antibiotic therapy for high risk patients has not been evaluated.

Prevention and control are difficult, due to the fact that *Listeria* organisms are ubiquitous and most infections are sporadic. The most effective strategy is to avoid the source of infection, namely, contaminated food. Thus, pregnant women and other high risk groups should refrain from consuming raw or partially cooked food of animal origin, soft unpasteurized cheeses and raw vegetables. Interestingly, three recent reports have demonstrated that food-borne listeriosis can cause serious and even fatal febrile illness with gastroenteritis in immunocompetent healthy persons [16–18]. In France, in an outbreak of listeriosis caused by pork tongue in gelatin, 26 cases reported since December 1999 resulted in 7 deaths [16]. In the USA, hot-dogs were identified as the vehicle transmitting *Listeria*, resulting in 50 cases and 6 adult deaths reported in early 1999 [17]. In Italy, contaminated corn and tuna salad caused an outbreak of febrile gastroenteritis among 1,566 mostly healthy young people [18].

In conclusion, listeriosis is an uncommon infection, with a greater incidence during pregnancy. Neonatal infection can be a devastating disease associated with high mortality and morbidity unless promptly diagnosed and treated. A high level of suspicion with an appropriate antibiotic treatment could prevent severe neonatal disease. In any case of a pregnant woman presenting with signs of bacterial infection and preterm labor, or at term with infection of unknown source, *Listeria* infection should be suspected. Following delivery, the placenta should be carefully examined histologically.

References

- Gellin BG, Broome CV. Listeriosis. *JAMA* 1989;261:1313–20.
- Silver HM. Listeriosis during pregnancy. *Obstet Gynecol Surv* 1998;53:737–40.
- Goulet V, Marchetti P. Listeriosis in 225 non-pregnant patients in 1992:

clinical aspects and outcome in relation to predisposing conditions. *Scand J Infect Dis* 1996;28:367–74.

- Southwick F, Purich D. Intracellular pathogenesis of listeriosis. *N Engl J Med* 1996;334:770–6.
- Singer DB. Infections of fetuses and neonates. In: Wigglesworth JS, Singer DB, eds. *Textbook of Fetal and Perinatal Pathology*. 2nd edn. London: Blackwell Science Co., 1998:492–4.
- Kampelmacher E, Huysinga W, Jansen L. The presence of *Listeria monocytogenes* in feces of pregnant women and neonates. *Zentralbl Bakteriol* 1972;222:258–62.
- Lamont R, Postlethwaite R. Carriage of *Listeria monocytogenes* and related species in pregnant and non-pregnant women in Aberdeen Scotland. *J Infect* 1986;13:187–93.
- Gray JW, Barrett JF, Pedler SJ, Lind T. Faecal carriage of listeria during pregnancy. *Br J Obstet Gynaecol* 1993;100:873–4.
- Schlech WF, Lavigne PM, Bortolus R, et al. Epidemic listeriosis: evidence of transmission by food. *N Engl J Med* 1983;308:203–6.
- Fleming DW, Cichi SL, MacDonald KL, et al. Pasteurized milk as a vehicle of infection in an outbreak of listeriosis. *N Engl J Med* 1985;312:404–7.
- Linnan M, Mascola L, Lou X, et al. Epidemic listeriosis associated with Mexican style cheese. *N Engl J Med* 1988;319:823–8.
- Case records of the Massachusetts General Hospital. Weekly clinicopathological exercises. Case 15-1997. Respiratory distress and seizure in a neonate. *N Engl J Med* 1997;336:1439–46.
- Topalovsky M, Yang SS, Boonpasat Y. Listeriosis of the placenta: clinicopathologic study of seven cases. *Am J Obstet Gynecol* 1993;169:616–20.
- Quinlivan JA, Newnham JP, Dickinson JE. Ultrasound features of congenital listeriosis – a case report. *Prenat Diagn* 1998;18:1075–8.
- Crukshank D, Warenski J. First trimester maternal *Listeria monocytogenes* sepsis and chorioamnionitis with normal neonatal outcome. *Obstet Gynecol* 1989;73:469–71.
- Dorozynski A. Seven die in French listeria outbreak. *Br Med J* 2000;320:601.
- Outbreak News: Listeriosis, France. WHO, Geneva. *Wkly Epidemiol Rec* 2000;75(9):69–76.
- Aureli P, Fiorucci GC, Caroli D, et al. An outbreak of febrile gastroenteritis associated with corn contaminated by *Listeria monocytogenes*. *N Engl J Med* 2000;342:1236–41.

Correspondence: Dr. N. Rojansky, Dept. of Obstetrics and Gynecology, Hadassah University Hospital, P.O. Box 12000, Jerusalem 91120, Israel. Phone: (972-2) -67-76424 Fax: (972-2) 643-3337 email: Rojan@cc.huji.ac.il