

Radiofrequency Ablation for the Management of Liver Tumors

Gil N. Bachar MD¹, Franklin Greif MD², Eytan Mor MD³, Ran Tur-Kaspa MD^{4,5} and Alexander Belenky MD PhD¹

Departments of ¹Radiology (Interventional Radiology Unit), ²Surgery A, ³Transplantation (Liver Transplantation Unit) and ⁴Medicine D, and ⁵Liver Institute, Rabin Medical Center (Beilinson Campus), Petah Tiqva, Israel
Affiliated to Sackler Faculty of Medicine, Tel Aviv University, Ramat Aviv, Israel

Key words: radiofrequency ablation, liver neoplasm, hepatocellular carcinoma, liver metastases

Abstract

Background: Radiofrequency ablation has recently become a viable treatment option for unresectable primary or secondary lesions confined to the liver.

Objective: To study the local therapeutic efficacy, side effects and complications of radiofrequency ablation for the treatment of hepatocellular carcinoma and liver metastases. This is the first reported experience of radiofrequency ablation for treating malignant hepatic tumors in Israel.

Methods: Fifteen consecutive patients, aged 53–73 years, with 23 lesions (8 patients with HCC and 7 with secondary liver tumors) underwent radiofrequency ablation under general anesthesia. RITA nine-array 5 cm thermal ablation catheter and the model 1500 generator were used. The mean diameter of all tumors was 4.28 cm (range 1–10 cm). Three lesions were 1–3 cm in diameter (small), 17 lesions measured 3.1–5 cm (medium), and 3 measured 5.1–10 cm (large).

Results: Complete necrosis was found in 8 (66%) of 12 HCCs by computed tomography scan. Of the remainder, diffuse tumor recurrence was demonstrated in three lesions (25%) after lipiodol injection and there was one local tumor recurrence. In the metastases group complete necrosis was found in 5 of 11 lesions (45%). One major complication (peritonitis) was treated with antibiotics and four (26%) minor complications (right pleural effusion, small subcapsular hematoma) were monitored.

Conclusions: Radiofrequency ablation appears to be an effective, safe and relatively simple procedure for the treatment of liver tumors.

IMAJ 2003;5:496–500

Surgical resection is the gold standard for the treatment of primary or secondary tumors. However, only 10–20% of patients are candidates for curative resection [1] because of poor hepatic reserve resulting from coexisting liver cirrhosis or the presence of extensive tumor load. Since medical therapy is of limited benefit, regional treatment methods, such as microwave ablation [2], cryoablation [3], percutaneous ethanol injection [4], chemoembolization, and radiofrequency ablation [5] have been suggested.

The aim of the present study was to assess the efficacy, safety and complications of RFA in treating malignant hepatic tumors. This is the first report of use of this method in Israel.

Indications and contraindications

RFA is a viable treatment option for focal and nodular or encapsulated tumors that are confined to the liver, without

evidence of vascular invasion or extrahepatic metastases. Eligible patients must have a maximum of four to five lesions. For treatment in one session with one needle insertion, tumor size should ideally be up to 5 cm; larger lesions, especially hepatocellular carcinoma, can sometimes be treated in one session with multiple needle insertions.

In patients with lesions adjacent to the gallbladder or the hepatic hilum, in whom RFA poses a risk of thermal injury to the biliary tract, intraoperative RFA may be preferred. Furthermore, patients with lesions located near hepatic vessels, in whom the blood flow cools the vascular wall but the heat loss poses the risk of incomplete ablation of the area of neoplastic tissue adjacent to the vessel, are also candidates for intraoperative RFA. Patients with multiple metastases in both lobes are better treated with partial hepatectomy and intraoperative RFA. Patients who are not considered eligible for RFA treatment are those with evidence of vascular invasion, extrahepatic metastases, or proximity of the mass to organs or large vessels. Patients with a high risk for general anesthesia or with pacemakers are also not considered eligible for treatment by RFA.

Patients and Methods

Patients and tumors

The study sample consisted of 15 consecutive patients (11 men and 4 women) aged 53–73 years (mean 62.1) who were referred to the Interventional Radiology Unit for RFA between November 2000 and December 2001. Eight patients had HCC and seven had secondary liver tumors [Table 1]. Twelve underwent percutaneous RFA and 3 had intraoperative RFA. Nine patients (60%) had a single lesion, 4 (26%) had 2 lesions, 1 (6.6%) had 3 lesions, and 1 (6.6%) had 4 lesions – a total of 23 lesions. Hepatitis B surface antigen was positive in five patients (62.5%) and three (37.5%) were positive for hepatitis C virus. One patient also had alcoholic cirrhosis.

Tumors were classified according to the size and appearance of tumor margins. Diameter ranged from 1 to 10 cm (mean 4.28 cm). Three lesions measured 1–3 cm in diameter (small), 17 measured 3.1–5 cm (medium), and 3 measured 5.1–10 cm (large). Twenty tumors had smooth, well-circumscribed margins or were surrounded by a capsule at imaging and were classified as non-infiltrating. Three tumors had irregular margins or appeared non-encapsulated, and were classified as infiltrating. The goal of RFA was curative in patients with non-infiltrating tumors and palliative in patients with infiltrating tumors.

HCC = hepatocellular carcinoma

RFA = radiofrequency ablation

Table 1. Characteristics of patients with hepatic tumor treated with radiofrequency ablation

Patient	Age/Gender	Disease	No. of lesions	Size (cm)	Time of procedure (min)	Hospital stay	Complications
1	73/M	HCC	1	4.5	50	2	Subcapsular hematoma, pleural effusion
2	60/M	HCC	2	4.5–5.5	90	1	None
3	53/M	HCC	1	3.5	75	2	Mild pain
4	71/M	HCC	2	3.5	90	5	Peritonitis
5	61/F	HCC	1	4	45	2	None
6	64/M	Diffuse HCC	3	4	120	4	Mild pain
7	62/M	HCC	1	4.5	50	7	None
8	65/M	HCC	1	4.5	70	2	None
9	71/F	Colon metastases	2	4.2	90	3	None
10	57/M	Thyroid metastases	4	4–5	120	2	Subpleural hematoma, pleural effusion
11	60/M	Colon metastases	1	10	120	1	None
12	56/M	Colon metastases	1	7	100	6	None
13	57/F	Colon metastases	1	3	40	10	None
14	67/F	Colon metastases	2	1.5, 3	60	5	None
15	60/M	Colon metastases	1	4	50	2	None

Work-up before the procedure

The work-up before the treatment included transabdominal gray-scale ultrasound with color Doppler using a 5000 HDI ultrasound scanner (Advanced Technology Laboratories, Bothell, WA, USA), equipped with a 2–4 MHz broadband convex-array transducer. Multiple sagittal and axial images of the liver were obtained. In addition, non-enhanced and dual-phase contrast-enhanced Multi Scan CT was performed using an Mx 8000 CT scanner (Marconi, Medical Systems, Cleveland, OH, USA). A total of 120 ml non-ionic contrast medium (Ultravist, 300 mg iodine/ml, Schering, Berlin, Germany) was injected into the median cubital vein with an automatic injector at a rate of 3–3.5 ml/sec. The entire liver was scanned twice: after 20 seconds (arterial phase) and after 70 seconds (portal phase) of contrast material injection.

The diagnosis of HCC was established by computed tomography scan after lipoidal injection, alpha-fetoprotein levels and fine-needle biopsy when needed. The diagnosis of metastasis was established by biopsy or a combination of ultrasound and CT, demonstrating the classic pictures in the presence of known primary disease in the colon, or the thyroid in one case.

Laboratory studies done 1 week before treatment consisted of complete blood count, renal panel, liver function panel, serum albumin, and tumor markers (alpha-fetoprotein and chorioembryonic antigen).

Technique

All patients signed a written informed consent before the procedure. All procedures were performed in the radiologic interventional suite. The patients were under general anesthesia using ultrasound guidance (HDI 5000, Advanced Technology Laboratories) in the supine position. Vital signs were monitored during the procedure and for 1 hour thereafter. A diverse electrode was placed on the back and legs, the skin was cleansed with iodized alcohol, and the appropriate approach to the lesion was selected with the help of the ultrasound probe. An intercostal approach was usually preferred for lesions located in the right lobe and a

subcostal approach for lesions in the left lobe. When the lesion was located at the apical edge of the liver in the subphrenic region or associated with planned resection, the procedure was done in the operating room (intraoperative RFA) through a laparotomy incision.

All ablations were performed with the RITA (Starburst XL) nine-array, 5 cm thermal ablation catheter (14 gauge needle 25 cm long) and the RITA model 1500 generator (RITA Medical Systems, Inc). The catheter tip was positioned at the intended ablation zone under sonographic guidance, and a nine-curved prong was deployed to deliver radiofrequency electrical energy to the tissues. The RITA generator was then operated. The total ablation time, impedance, and temperature at the tip of the prong were displayed on the device panel, and a complete output of the generator was redisplayed graphically on a laptop screen. The following ablation protocol was used: area of 3 cm in diameter – 105°C for 14.5 minutes, 4 cm area – 110°C for 14 minutes, and 5 cm area – 110°C for 7 minutes. The total ablation time for one needle insertion for a 5 cm lesion was 35 minutes; the overall ablation cycle was slightly longer because of the time needed to reach the target temperature. Tumors larger than 5 cm required two to four ablation cycles and, sometimes, multiple overlapping ablations. The ablation procedure was assessed in two ways. The first and more crucial was monitoring of the thermocouple temperatures during and after ablation. The second consisted of observing the outgassing of dissolved nitrogen into the heated tissue. As the tissue is heated, the solubility of the dissolved nitrogen decreases, resulting in microbubble formation within the tissue [Figure 1]. This appears as an echogenic blush that gradually enlarges to encompass the zone of ablation. The area of increased echogenicity progressively increased in size over the course of ablation and usually covered the entire tumor. The appearance and progression of the hyperechogenicity were used to guide the duration of therapy; radioenergy was applied until the tumor appeared completely hyperechoic. Furthermore, in cases in which multiple electrode insertions were required, each subsequent electrode placement was directed to an area of the tumor where hyperechogenicity was not

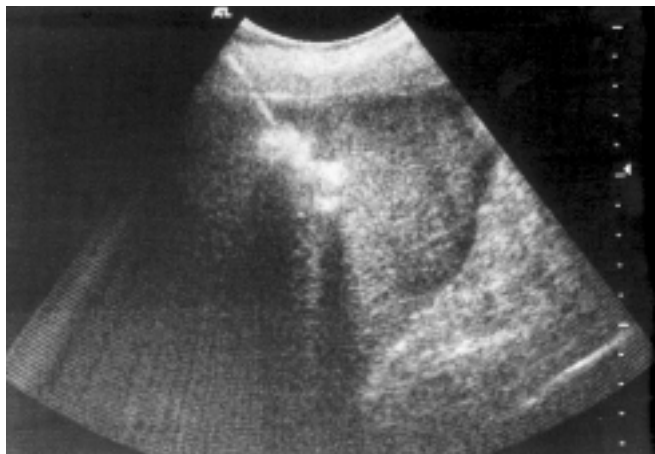


Figure 1. A 60 year old patient with 4.5 cm HCC. Sonogram scan shows that the RF electrode has been placed in the lesion, and dissolved nitrogen in the heated tissue is demonstrated as a hyperechoic patch around the electrode tip.

evident. At the end of the procedure, as the needle was withdrawn, ablation was performed to coagulate the needle tract and prevent bleeding and tumor seeding.

Follow-up

Follow-up ranged from 1 to 12 months (mean 4 months). Visits were conducted 1 month after RFA and every 3 months thereafter, and included clinical evaluation and the same laboratory tests performed before the procedure. To evaluate the response to RFA, contrast-enhanced CT was performed with the same parameters as the pretreatment scanning. Every patient also underwent gray-scale and color Doppler ultrasound to evaluate tumor necrosis and identify residual viable tumor foci. Tumor necrosis was considered complete when no foci of enhancement were seen within the tumor or its periphery. Treatment was considered as a partial or complete failure when the residual tumor was detected on follow-up imaging or when the disease became diffuse, with enhancing tissue around the treated tumor in the same segment.

Results

Lesion size was 1–10 cm, and the number of needle insertions ranged from one to six. The procedures lasted 40–120 minutes. Patients were hospitalized for 1–5 days after the procedure, except for three patients who underwent laparotomy and required a stay of 3–10 days.

The eight patients in the primary HCC group had a total of 12 lesions. Contrast-enhanced CT performed 1 month after RFA showed complete necrosis in 8 (66%) of the 12 tumors. Of the remainder, three tumors (25%) showed diffuse spread on CT with lipoidal injection, and one showed local recurrence. The patients with diffuse disease were treated with chemotherapy or chemo-embolization.

The metastases group consisted of seven patients with 11 lesions: six patients had colorectal liver metastases and one patient had medullary carcinoma of the thyroid with liver metastases. One patient in this group had a very large lesion (10 cm), which was treated with six needle insertions in one session.

The patient with thyroid carcinoma had eight metastases, which were treated in two sessions. Another patient underwent left lobectomy for liver metastases. Nine months later he had tumor recurrence in segment 8. Intraoperative RFA was performed because of the location of the tumor [Figure 2].

Two patients with ascites underwent catheter drainage before the procedure. In three selected patients, we performed intraoperative RFA because the lesion was located along the surface of the liver in a subphrenic area or near the great vessels or the hilum. One patient with multiple metastases in both lobes underwent partial hepatectomy of one lobe and intraoperative RFA in the other. Contrast-enhanced CT performed 1 month after treatment in the patients with metastases showed complete necrosis of 5 of the 11 metastases. In one patient with two metastases that were treated successfully, multiple additional metastases developed 1 month after treatment, and chemotherapy was given. Multiple metastases in the lungs were noted in the patient with thyroid carcinoma.

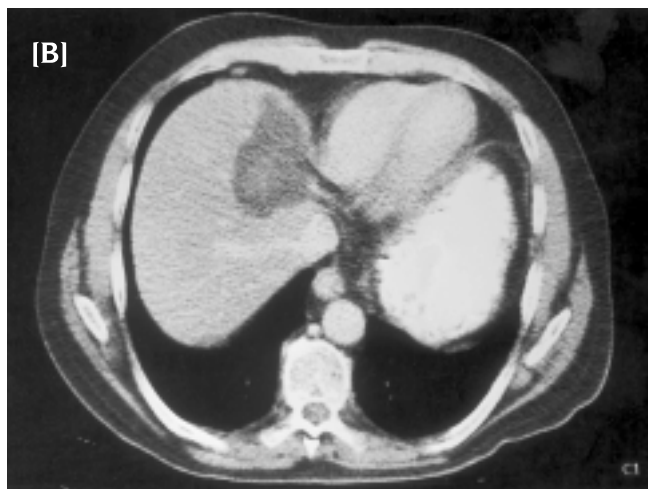
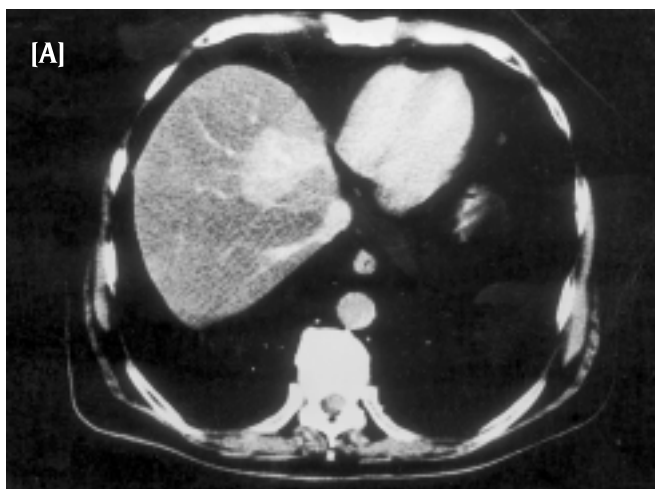
Figure 2. A 56 year old patient after left hepatic lobectomy for liver metastases. **[A]** Arterial phase CT scan obtained before RFA demonstrated a 7 cm hyperattenuating mass in segment 8 consistent with recurrence. **[B]** CT obtained 2 months after intraoperative RFA revealed complete ablation without recurrence.

Complications

Because the procedures were performed under general anesthesia, most of the patients had mild postprocedural pain, which was treated with oral analgesics. One patient had moderate pain requiring hospitalization for an extra day. In two patients (13.3%) a small asymptomatic right pleural effusion was noted which lasted less than 1 month, and two patients (13.3%) had a small subcapsular hematoma which was followed with ultrasound and resolved after 1–2 months. In the majority of patients, transaminase levels increased two to threefold over baseline levels during the first 3 days after the procedure and normalized by day 7. No significant changes in other laboratory parameters were observed.

During RFA, one patient with ascites was found to have hyperpyrexia with leukocytosis and peritonitis, which was treated with antibiotics. The duration of his hospital stay was 5 days.

Discussion

Of the procedures developed in recent years for the treatment of liver tumors, percutaneous ethanol injection has been shown to be safe and effective for nodular-type HCC [6,7], with a long-term outcome almost equal to that for resection. However, PEI cannot be applied to large HCC lesions or to lesions containing intramural septa (because of alcohol diffusion within the tumor and because residual viable neoplastic tissue persists after the procedure). In addition, PEI was shown to be ineffective in the treatment of liver metastasis [8]. A good alternative may be offered by percutaneous RFA [5,9], where energy at a frequency of 400–500 kHz is delivered into the tumor. The resulting electron vibrations within the tissue cause resistive heating. At temperatures over 50°C, the cell membranes melt and fuse, leading to protein denaturation and irreversible cell death [10]. To the best of our knowledge, this is the first study describing the use of percutaneous RFA to treat primary and secondary liver tumors in Israel.

In the patients with primary HCC in the present series, the success rate (complete tumor necrosis) for RFA was 66%. This figure is close to the 71% success rate reported by Livraghi et al. [11] for tumors of similar size (3.1–5 cm in their study and 1–5.5 cm in ours), but considerably lower than the 90% reported by the same group for smaller tumors (1.0–3 cm) [12].

For large, secondary tumors, the present study shows that the technique used here has important advantages over other available percutaneous thermal (microwave, laser) therapies regarding the volume of tumor necrosis achieved and the procedure time [2,11–13]. This is also true for PEI, which generally requires carefully planned multiple sessions to ensure that the ethanol is distributed throughout the tumor volume [12], and for conventional RFA, performed with a single monopolar electrode, which was capable of producing thermal necrosis in lesions not more than 1.6 cm in diameter and required several insertions to treat lesions of 5.0 cm or more. To overcome these limitations, we used a larger, nine-array, 5 cm ablation catheter with a newer-model generator. This enabled the creation of larger ablation sites without additional morbidity or mortality. We were thus able to treat 83% of the lesions

with a single ablation cycle. The largest lesion in our series measured 10 cm, and the largest number of insertions required to treat a single lesion was six. The largest number of lesions treated in one patient in a single session was four. Nevertheless, to be considered for RFA treatment, the tumor must be confined to the liver, without evidence of vascular invasion or extrahepatic metastases. Tumor size should ideally be up to 5 cm, although larger lesions can be treated by multiple needle insertions. In addition, lesions located adjacent to the gallbladder or hepatic hilum or near large vessels risk causing thermal injury. Lesions located along the surface of the liver may be associated with a higher risk of complications and intraoperative RFA can be used. Patients with a high risk for general anesthesia or with pacemakers are also not considered eligible for treatment by RFA.

Llovet et al. [14] and Casella et al. [15] reported that 4 of 32 patients (12.5%) who underwent RFA with a cooled-tip needle had biopsy-proven needle-tract seeding 4–18 months later. In light of this finding, in our study, using the RITA (Starburst XL) thermal ablation catheter and model 1500 generator, we performed tract ablation when the needle was withdrawn at the end of the procedure. After 12 months of follow-up we did not observe any neoplastic seeding along the tract.

To evaluate response to RFA, Livraghi et al. [12] performed contrast-enhanced CT 1 day and 1 month following treatment. They reported that during the portal phase of the 24 hour scan, a hyperattenuation surrounding the region of coagulated tumor was apparent in the majority of cases. They attributed this finding to reactive hyperemia rather than residual viable tumor. This assumption was supported by the disappearance of the rim on subsequent scans. In our protocol, we first evaluated response only 1 month following the procedure to avoid misinterpretation.

Livraghi and colleagues [11] performed all their RFA procedures under conscious sedation. One major complication occurred in a patient in whom severe hiccups led to erratic diaphragmatic movements during electrode placement, resulting in massive bleeding from the liver capsule and tumor. We used general anesthesia in all our patients and there were no major complications.

The absence of major complications is particularly noteworthy considering that our series consisted of several tumors near the hepatic capsule gallbladder and major blood vessels. We noted only a few minor complications: moderate pain leading to an increased hospital stay in one patient, and an asymptomatic right pleural effusion and small subcapsular hematoma in two patients each that resolved without treatment. One patient with ascites and peritonitis underwent drainage of 10 L of fluid before RFA and was treated by antibiotics. In three patients with lesions located along the surface of the liver in a subphrenic area or near great vessels or the hilum, we performed intraoperative RFA. All outcomes were successful, although hospitalization was longer than for percutaneous RFA (2–10 days versus 1–5 days).

In summary, RFA, a relatively new, minimally invasive modality for the thermal treatment of hepatic tumors, appears to be effective, safe and easy to use. It is associated with only a few and minor complications. Our current department policy considers RFA the

PEI = percutaneous ethanol injection

treatment of choice for inoperable nodular-type HCC and meta-chronous metastases. Nevertheless, further investigation is warranted before definitive recommendations can be made.

References

1. Ravikumar TS, Kane R, Cady B. A 5-year study of cryosurgery in the treatment of liver tumors. *Arch Surg* 1991;126:1520-4.
2. Seki T, Wakabayashi M, Nakagama T. Percutaneous microwave coagulation therapy for solitary metastatic liver tumors from colorectal cancer. A pilot clinical study. *Am J Gastroenterol* 1999;94:322-7.
3. Gaitini D, Kopelman D, Soudak M, et al. Impact of intraoperative sonography on resection and cryoablation of liver tumors. *J Clin Ultrasound* 2001;29:265-72.
4. Shiina S, Tgawa K, Niwa K. Percutaneous ethanol injection therapy for hepatocellular carcinoma results in 146 patients. *Am J Roentgenol* 1993;160:1023-8.
5. Livaraghi T, Goldberg SN, Lazzaroni S, Meloni F, Solbiati L, Gazelle GS. Radiofrequency of large hepatocellular carcinoma. *Radiology* 2000;214:761-8.
6. Livaraghi T, Giorgio A, Marin G. Hepatocellular carcinoma and cirrhosis in 746 patients: long-term results of percutaneous ethanol injection. *Radiology* 1995;197:101-8.
7. Lencioni R, Pinto F, Armillotta N. Long-term results of percutaneous ethanol injection therapy for hepatocellular carcinoma in cirrhosis. A European experience. *Eur Radiol* 1997;7:514-19.
8. Livaraghi T, Vettori C, Lazzaroni S. Liver metastases: results of percutaneous ethanol injection in 14 patients. *Radiology* 1991;179:709-12.
9. Goldberg SN, Gazelle GS, Mueller PR. Thermal ablation for focal malignancy: a unified approach to underlying principles, technique and diagnostic imaging guidance. *Am J Roentgenol* 2000;174:323-31.
10. McGahan JP, Brock JM, Tesluk H. Hepatic ablation with use of radio-frequency electrocautery in the animal model. *J Vasc Interv Radiol* 1992;3:291-7.
11. Livaraghi T, Goldberg SN, Lazzaroni S, et al. Hepatocellular carcinoma-radio-frequency ablation of medium and large lesions. *Radiology* 2000;214:761-8.
12. Livaraghi T, Goldberg SN, Lazzaroni S, Meloni F, Solbiati L, Gazelle GS. Small hepatocellular carcinoma: treatment with radio-frequency ablation versus ethanol injection. *Radiology* 1999;210:655-61.
13. Gillams AR. Thermal ablation of liver metastases. *Abdom Imaging* 2001;26:361-8.
14. Llovet JM, Vilana R, Bru C, et al. Increased risk of tumor seeding after percutaneous radiofrequency ablation for a single hepatocellular carcinoma. *Hepatology* 2001;33:1124-9.
15. Casella G, Cacparado E, Rovere G, Buda CA, Cascinu S, Baladini B. Cutaneous seeding after ultrasound-guided percutaneous ethanol injection for treatment of hepatocellular carcinoma. *J Clin Ultrasound* 2001;29:354-8.

Correspondence: Dr. G.N. Bachar, Det. of Radiology, Rabin Medical Center (Beilinson Campus), Petah Tiqva 49100, Israel.
Phone: (972-3) 937-7090
Fax: (972-3) 937-7095
email: drbachar@netvision.net.il