

Transinguinal Laparoscopic Examination: An End to the Controversy on Repair of Inguinal Hernia in Children

Gad Lotan MD¹, Yigal Efrati MD¹, Sorin Stoler MD² and Baruch Klin MD¹

Departments of ¹Pediatric Surgery and ²Anesthesiology, Assaf Harofeh Medical Center, Zerifin, Israel
Affiliated to Sackler Faculty of Medicine, Tel Aviv University, Ramat Aviv, Israel

Key words: inguinal hernia, laparoscopy, exploration, processus vaginalis, children

Abstract

Background: Contralateral exploration of the groin has been common practice among pediatric surgeons for nearly 50 years, based on the high incidence of patent processus vaginalis on the contralateral side with the potential for the subsequent development of a hernia.

Objectives: To evaluate transinguinal laparoscopic examination of the contralateral side during repair of inguinal hernia in children in order to reach a decision regarding exploration of the contralateral side.

Methods: Over a 21 month period 124 children with unilateral inguinal hernia underwent laparoscopic evaluation of the contralateral groin. The operations were performed under general anesthesia as ambulatory procedures.

Results: Transinguinal contralateral laparoscopic exploration was positive (patent processus vaginalis) in 26 children (21%) and negative (closed processus vaginalis) in 88 (71%). Failure to introduce the telescope occurred in 10 patients (8%) due to a friable or narrow hernia sac. Twenty-five children below 2 years of age were spared exploration of the contralateral side as a result of the negative laparoscopic examination. On the other hand, 15 children aged 2–17 had their contralateral groin explored because of a positive finding at laparoscopy.

Conclusions: Transinguinal laparoscopic examination of the contralateral side during repair of inguinal hernia in children is a simple, safe and quick method to avoid systematic bilateral explorations and should be part of every pediatric surgeon's experience.

IMAJ 2004;6:339–341

For Editorial see page 367

Inguinal hernia repair is one of the most frequently performed operations in children. Bilateral inguinal hernias are relatively common, especially in children under the age of 2 years. For nearly 50 years controversy has raged concerning the need for routine exploration of the contralateral side when performing surgery on a unilateral symptomatic inguinal hernia. The advent of transinguinal laparoscopic visualization of the contralateral internal ring helped to end this controversy and is the subject of this report.

Patients and Methods

Over a period of 21 months 124 children (100 males and 24 females) with unilateral inguinal hernia underwent laparoscopic evaluation of the contralateral groin. Patients ranged in age from 1 month to 17 years, with an average of 4.6 years. Eighty-four hernias were on the right side and 40 on the left. The operations were performed as ambulatory procedures under general anesthesia. The hernial sac was dissected free from the spermatic cord and traced to the

internal ring. The sac was opened and a 5 mm reusable cannula was introduced through the hernial sac and secured with a silk tie. Carbon dioxide insufflation was accomplished at a flow rate of 1 L/min to a pressure of 8–10 mmHg. A 70 degree angle telescope was then introduced and the contralateral internal ring was easily visualized. If a patent processus vaginalis was seen [Figure 1], a contralateral inguinal hernia repair was performed. If the processus vaginalis was not patent [Figure 2], the telescope was removed and the hernia repair completed.

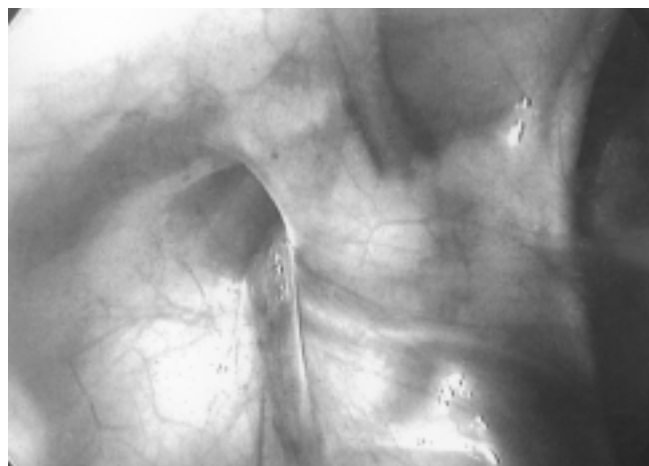


Figure 1. Laparoscopic view of left internal inguinal ring. The vessels and vas are seen entering the ring with the patent processus vaginalis.

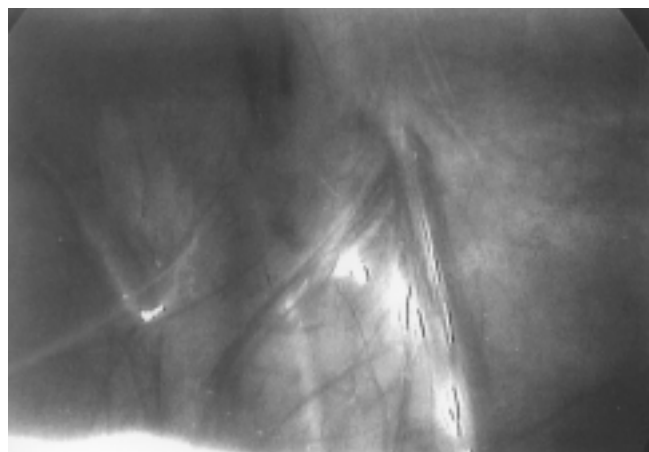


Figure 2. Laparoscopic view of right internal inguinal ring. The vessels and vas are exiting the ring with the closed processus vaginalis.

Results

Transinguinal contralateral laparoscopic exploration was positive (PPV) in 26 children (21%) and negative (closed processus vaginalis) in 88 (71%). In 10 patients (8%) the telescope could not be introduced due to a friable or narrow hernial sac. Of the 114 children where laparoscopy was accomplished, 26 (22.8%) demonstrated a PPV on the asymptomatic side, with the peak incidence occurring during the first year of life. The laparoscopic observation of the contralateral side took approximately 2 minutes. There were no operative complications as a result of this procedure, and all the patients were discharged on the day of the operation except for those under 1 year of age. Over a period of follow-up ranging from 1 to 3 years no child with a negative laparoscopy (closed processus vaginalis in the contralateral side) has subsequently developed an inguinal hernia on that side.

Discussion

Since the introduction of routine bilateral groin exploration for inguinal hernia in the early 1950s, this policy has been the subject of much discussion and controversy. Contralateral exploration of the groin has been common practice among pediatric surgeons for many years, based on the high incidence of PPV on the contralateral side with the potential for the subsequent development of a hernia [1]. Approximately 80–94% of newborns have a PPV, some 60% of which will obliterate in the first 2 years of life [2,3]. Nakayama and Rowe [4] reported that a PPV exists in about 60% of infants with unilateral inguinal hernia and that one-third of PPVs obliterate within 2 years, one-third develop into a subsequent hernia, and in the remaining one-third the PPV remains without a clinically apparent hernia developing.

The reported incidence of metachronous contralateral inguinal hernia (5.8–11.6%), which is much lower than the reported rate of PPV (48–61%), supports the well-known fact that a PPV is not necessarily an inguinal hernia [5–8] and questions the validity of the systematic bilateral exploration approach. In most series, contralateral hernia repair is estimated to be required in only about 10–20% of children with a PPV. In spite of this, most pediatric surgeons still routinely explore the contralateral groin in boys under 2 years of age and in girls under 5 [9]. Children with ventriculo-peritoneal shunts, peritoneal dialysis catheters and ascites are at increased risk of becoming symptomatic due to the increased intraabdominal pressure, and should have contralateral surgical exploration unless laparoscopic examination is performed.

Routine exploration of the contralateral groin is not without complication, with a 1.6% risk of injury to the vas deferens [10]. Even more impressive are the results of the animal studies performed by Shandling and Janik [11]. They demonstrated a 10% incidence of vasal luminal narrowing following even gentle manipulation of the cord during dissection. Other potential complications include testicular atrophy (1–2%), decreased testicular size (2.7–13%), testicular malposition, and wound infection.

In an effort to avoid routine and unnecessary exploration of the

contralateral groin, preoperative and intraoperative means of diagnosing unsuspected inguinal hernias have been developed. Contrast herniography [12], pneumoperitoneum (Goldstein's test) [13], and probing of the contralateral groin with Bakes dilators [14] have only historical value today. Ultrasound of the groin, as an effective alternative for evaluation of the contralateral groin before surgery, was reported by Erez et al. in 1993 [15]. A correct sonographic diagnosis was obtained in 185 of 200 children (93%) with known unilateral and bilateral inguinal hernias. Laparoscopic inguinal exploration of the asymptomatic contralateral side was first reported by Lobe and Schropp in 1992 [16]. They reported 96% accuracy in their initial experience, with no complications. Chu et al., in 1993 [17], reported laparoscopy through the hernia sac in the involved side, a natural extension of the Goldstein test, instead of the usual approach through the umbilicus, thereby significantly decreasing the possibility of complications. The positive laparoscopic findings reported by Wolf and Hopkins [18] included an obvious opening or funnel defect, bubbles, crepitation, veil with opening, and concentric peritoneal rings distal to the internal ring. Many reports of transinguinal laparoscopic examination of the contralateral groin in pediatric hernia repair followed, confirming the accuracy of this method [19–23].

In the present study 25 children under the age of 2, who would have been routinely explored on the contralateral side by most surgeons, were now spared the exploration because of the negative laparoscopic exploration. In children under 1 year of age, the results were even more convincing. Of the 27 children within this age range, 22 boys and 5 girls, 15 boys (55.6%) and 1 girl (3.7%) were found to have a closed processus vaginalis on laparoscopic evaluation of the contralateral side. The practical consequence of these findings is that 16 of 27 children less than 1 year of age were spared the routine exploration of their contralateral side – which is still the usual practice followed by most pediatric surgeons. These findings support our conclusion that many unnecessary explorations were avoided by the simple use of transinguinal laparoscopic examination of the contralateral internal ring during the operation. The other side of the coin relates to the 82 children in our study between the ages of 2 and 17 years. Most surgeons agree that exploration of the contralateral side is not essential, except in cases where a hernia is clinically suspected. Fifteen of the 82 examined children in this age range were found to have a PPV on the contralateral side and underwent bilateral inguinal hernia repair. Had it not been for the laparoscopic exploration, they would probably have presented at a later time with a hernia in the contralateral side – an unpleasant experience for both surgeon and patient. The advantages of examining the contralateral groin include avoiding a second anesthesia, sparing the child the risk and mental trauma of a second operation, sparing the parents the anxiety associated with a second operation, and sparing the physician the embarrassment associated with the appearance of a second hernia at a later time.

Diagnostic laparoscopic examination for a potential contralateral hernia is a simple, accurate, fast, and effective way of reducing negative explorations, and can be said to mark the end of the systematic bilateral exploration controversy. The technique

PPV = patent processus vaginalis

is easily learned and should be part of every pediatric surgeon's therapeutic armamentarium when treating inguinal hernias in children.

Acknowledgment. We thank Hagit Abramson for her continuous help in maintaining the laparoscopic equipment and for her contribution.

References

1. Rothenberg RE, Barnett T. Bilateral herniotomy in infants and children. *Surgery* 1955;37:947-50.
2. Snyder WH, Greaney EM Jr. Inguinal hernias. In: Mustard UT, Ravitch MM, Snyder WH Jr, et al., eds. *Pediatric Surgery*. 2nd edn. Chicago: Year Book Medical Publishers, 1969:692-707.
3. Rowe MI, Copelson LW, Clatworthy HW. The patent processus vaginalis and the inguinal hernia. *J Pediatr Surg* 1969;4:102-7.
4. Nakayama DK, Rowe MI. Inguinal hernia and the acute scrotum. *Pediatr Rev* 1989;11:87-93.
5. Muraji T, Noda T, Higashimoto Y, et al. Contralateral incidence after repair of unilateral inguinal hernia in infants and children. *Pediatr Surg Int* 1993;8:455-7.
6. Tackett LD, Breuer CK, Luks FI, et al. Incidence of contralateral inguinal hernia: a prospective analysis. *J Pediatr Surg* 1999;34:684-8.
7. Kiesewetter WB, Parenzan L. When should hernia in the infant be treated bilaterally? *JAMA* 1959;171:287-90.
8. Chin T, Liu C, Wei C. The morphology of the contralateral internal inguinal rings is age-dependent in children with unilateral inguinal hernia. *J Pediatr Surg* 1995;30:1663-5.
9. Rowe MI, O'Neill JA, Grosfeld JL, et al. Inguinal and scrotal disorders. In: O'Neill JA, Rowe MI, Grosfeld JL, eds. *Essentials of Pediatric Surgery*. St. Louis: Mosby Year Book, Inc., 1995:446-61.
10. Sparkman RS. Bilateral exploration in inguinal hernia in juvenile patients. *Surgery* 1962;51:393.
11. Shandling B, Janik JS. The vulnerability of the vas deferens. *J Pediatr Surg* 1981;16:461-4.
12. Jewett TC Jr, Kuhn JP, Allen JE. Herniography in children. *J Pediatr Surg* 1976;11:451.
13. Harrison CB, Kaplan GW, Scherz HC, et al. Diagnostic pneumoperitoneum for the detection of the clinically occult contralateral hernia in children. *J Urol* 1990;144:510-11.
14. Kramer SG, Davis SE. Transperitoneal detection of occult inguinal hernia. *Milit Med* 1967;132:512-14.
15. Erez I, Kovalivker M, Schneider N, Glaser E, et al. Elective sonographic evaluation of inguinal hernia in children – an effective alternative to routine contralateral exploration. *Pediatr Surg Int* 1993;8:415-18.
16. Lobe TE, Schropp KP. Inguinal hernias in pediatrics: initial experience with laparoscopic inguinal exploration of the asymptomatic contralateral side. *J Laparoendosc Surg* 1992;2:135-40.
17. Chu CC, Chou CY, Hsu TM, Yang TH, Ma CP, Cywes S. Intraoperative laparoscopy in unilateral hernia repair to detect a contralateral patent processus vaginalis. *Pediatr Surg Int* 1993;8:385-8.
18. Wolf SA, Hopkins JW. Laparoscopic incidence of contralateral patent processus vaginalis in boys with clinical unilateral inguinal hernias. *J Pediatr Surg* 1994;29:1118-21.
19. Rescorla FJ, West KW, Engum SA, Scherer III LR, Grosfeld J. The "other side" of pediatric hernias: the role of laparoscopy. *Am Surg* 1997;63:690-3.
20. Holcomb III GW. Diagnostic laparoscopy for congenital inguinal hernia. *Semin Laparosc Surg* 1998;5:55-9.
21. Mittenburg DM, Nuchtern JG, Jaksic T, Kozinetz C, Brandt ML. Laparoscopic evaluation of the pediatric inguinal hernia – a meta-analysis. *J Pediatr Surg* 1998;33:874-9.
22. Guvenc BH. Diagnostic laparoscopic evaluation of the contralateral internal inguinal ring: the search for a prospective hernia. *Pediatr Endosc Surg Innov Techn* 2001;5:259-65.
23. Geisler DP, Jegathesan S, Parmley MC, McGee JM, Nolen MG, Broughan TA. Laparoscopic exploration for the clinically undetected hernia in infancy and childhood. *Am J Surg* 2001;182:693-6.

Correspondence: Dr. G. Lotan, Dept. of Pediatric Surgery, Assaf Harofeh Medical Center, Zerifin 70300, Israel.
Phone: (972-8) 977-9102
Fax: (972-8) 977-9108
email: lotan@asaf.health.gov.il