

Abdominal Aortic Aneurysm in Behçet's Disease: New Treatment Options for an Old and Challenging Problem

Samy S. Nitecki MD¹, Amos Ofer MD², Tony Karram MD¹, Henry Schwartz MD¹, Ahuva Engel MD² and Aaron Hoffman MD¹

Departments of ¹Vascular Surgery and ²Radiology, Rambam Medical Center, Haifa, Israel
Affiliated to Technion Faculty of Medicine, Haifa, Israel

Key words: Behçet's disease, vascular Behçet, abdominal aortic aneurysm, endovascular repair, anastomotic pseudoaneurysm

Abstract

Background: Arterial involvement in Behçet's syndrome is rare. Aneurysms are common among the arterial lesions, affecting various arteries but mostly the abdominal aorta. Surgical interposition graft insertion is the treatment of choice for large aneurysms. However, vasculitis in these patients is the reason for the notorious surgical complications that result in up to 50% false aneurysms in anastomotic sites. Recently, endovascular repair for abdominal aortic aneurysms has been established.

Objectives: To learn more about vascular Behçet and, specifically, to compare the results of surgical treatment and endovascular repair of AAA in patients with Behçet's syndrome.

Methods: We retrieved the medical records of all 53 patients with Behçet disease admitted to Rambam Medical Center during the years 1985 and 2001, and analysed the results and follow-up of open surgery versus endovascular repair of AAA in patients with known Behçet's syndrome.

Results: Of the 53 patients with Behçet's disease 18 had vascular manifestations (34%). AAAs were encountered in 8 patients (15%) and 5 were treated. Open surgery (group 1), under general anesthesia, lasted less than 3 hours with an average aortic clamping time of 34 minutes (range 26–41 min) after which the patients were transferred to the intensive care unit for 24–48 hours. Endovascular treatment (group 2), although lasting about the same time without the need for intensive care, necessitated contrast media and fluoroscopy. The length of hospital stay was considerably shorter for patients after endovascular repair compared to open surgery (3 days vs. 6 days). Combined mortality and morbidity was higher in patients who underwent open surgery compared to endovascular repair (one death, one major amputation and three anastomotic pseudoaneurysms compared to one temporary contrast-induced nephropathy).

Conclusions: Vasculo-Behçet patients with AAA are better candidates for endovascular treatment than atherosclerotic patients. Combined morbidity (especially anastomotic pseudoaneurysms) and mortality of Behçet patients after endovascular repair is considerably lower than after open surgery.

IMAJ 2004;6:152–155

For Editorial see page 162

The triad of recurrent ulcers in the oral and genital mucosa coupled with eye inflammation (uveitis) was first described in 1937 by the Turkish dermatologist Hulusi Behçet [1]. Many patients have since been diagnosed and additional organ involvements have been

reported, but the etiology is still unknown; the highest prevalence is in the Middle East and Japan [2,3].

Vasculitis is the predominant histopathologic lesion in Behçet syndrome [2–5]. Arteries and veins of all sizes may be involved [6]. Vascular lesions occur in up to 25–35% of patients (34% in this study) and mostly in the form of venous thrombosis and arterial aneurysms [5–8]. The lesions are different from usual atherosclerotic lesions and the use of angiography and computerized tomography may be helpful in distinguishing vascular Behçet from other conditions [7]. Approximately 68% of all Behçet patients with vascular involvement have both venous and arterial lesions, 25% have venous lesions alone, and only 7% have exclusive arterial lesions [5–9]. Although vascular complications are the major cause of death in patients with Behçet syndrome, they are not one of the five major criteria for diagnosis [4,9].

Aneurysms, in Behçet syndrome, were reported in the left ventricle, pulmonary, carotid, renal and hepatic arteries and arteries of the extremities [10,11]. The most frequently encountered aneurysm, however, occurs in the abdominal aorta. In the present study we compared the results of conventional open surgery to those of endovascular repair for large AAA.

Patients and Methods

We performed a retrospective analysis of all the medical data of patients with Behçet's disease admitted to Rambam Medical Center between 1985 and 2001. There were 53 admissions of patients with Behçet's disease diagnosed according to known international criteria. The vast majority of patients was admitted to the Department of Dermatology with typical recurrent oral and genital ulcers. Eighteen patients had vascular manifestations (34%), of whom 5 were treated for abdominal aortic aneurysms. Three other patients had small aneurysms (diameter < 4 cm) and underwent follow-up rather than surgical treatment. All the aneurysms (in 15% of all patients) were saccular, located in the infrarenal aorta [Figure 1] and had a mean diameter of 5.8 cm (range 5.4–7.3 cm). Additionally, one patient also had a small (1.3 cm) right popliteal aneurysm. All patients were males with a mean age of 43 years (range 36–49 years). Abdominal and back pain were the leading symptoms in three patients with symptomatic AAA in whom a tender pulsatile abdominal mass could be felt. The other two were asymptomatic, with incidental finding of the aneurysm by ultrasonography for cholecystitis in one patient and recurrent urinary tract infection in the other.

AAA = abdominal aortic aneurysm

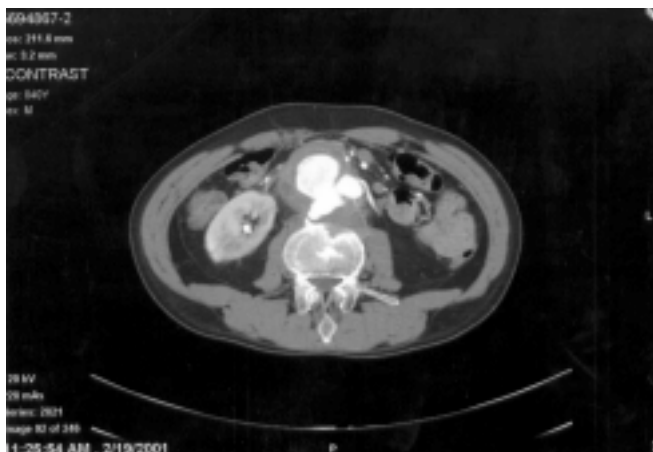

Figure 1. An axial slice from CT angiography showing the abdominal aorta with a large (5.5 cm) irregular aneurysm extending from the anterior abdominal wall to the vertebral column. The inferior mesenteric artery (IMA) is patent. There is erosion of the vertebral body.

Laboratory results were within the normal range except for elevated white blood cells in one patient and increased erythrocyte sedimentation rate in two. Screening for thoracic aneurysm by CT scan and carotid artery disease by duplex was negative in all patients. Treatment decisions for AAA were based on CT or CT angiography.

Results

Treatment was decided based on patients' symptomatology and aneurysmal size as measured by CT scan or CT angiography with three-dimensional reconstructions. Patients were prepared for treatment, with special attention paid to Behçet syndrome and to their co-morbid diseases. Age, clinical and laboratory findings were similar for patients who underwent open surgery compared to those who had endovascular repair for AAA.

Group 1 comprised three patients (two symptomatic) in whom midline laparotomy was performed under general anesthesia. These patients presented before we began to practice endovascular repair for AAA. Dacron tube graft was employed in two patients and aortobifemoral graft in one. Aortic clamping time averaged 34 minutes (range 26–41 min). There were no cardiac events associated with either clamping or declamping of the aorta. In addition, a reversed short saphenous vein graft was used in one patient, coupled with exclusion of a right popliteal aneurysm. After surgery, patients were transferred to the intensive care unit for 24–48 hours. Recovery was uneventful aside from lymphorrhea in one patient, and they were discharged on the 5th–7th postoperative day. Approximately 14 months after surgery the patient who was operated on for both AAA and popliteal aneurysms was readmitted with right leg ischemia. Angiography revealed a thrombosed femoropopliteal graft and two suspected anastomotic aneurysms that were confirmed by ultrasound. During surgery, a 3.6 cm femoral anastomotic aneurysm was found. A new, end-to-side anastomosis was performed between the right aortofemoral (dacron) limb and distal iliac artery with pladget enforcement. Also, a new iliopopliteal bypass using the contralateral saphenous vein was fashioned.

The deep femoral artery was re-implanted to the graft. Distally, in the popliteal anastomosis, a smaller 1.9 cm thrombosed aneurysm was found and excluded. The new anastomosis was carried down to the tibio-peroneal trunk. The patient was discharged after an uneventful recovery but was readmitted with right leg ischemia 9 months later, this time without anastomotic aneurysm. Three limb salvage procedures were performed, but infection and ischemia necessitated right above-knee amputation [Table 1].

The second patient was admitted to the emergency room 3 years after his surgery, in severe hypovolemic shock due to rupture of an aortic anastomotic pseudoaneurysm. Secondary midline laparotomy was done with aortic cross-clamping. Unfortunately disseminated intravascular coagulation developed and the patient died. The third patient is well without anastomotic pseudoaneurysm almost 12 years after his operation [Table 1].

In this group of patients there were three abdominal aortic aneurysms and one popliteal aneurysm. Altogether, eight anastomoses were performed and three of these patients had anastomotic pseudoaneurysms resulting in the death of one patient and major limb amputation in another [Table 1].

Group 2 consisted of two patients (one symptomatic) who underwent endovascular treatment. Right and left groin incisions were performed under epidural anesthesia. A bifurcated Talent endoprosthesis (Medtronic, USA) was used. The aortic stent-graft with its single limb was inserted via a transverse arteriotomy in the right common femoral artery. The covered part of the stent-graft was positioned just below the renal arteries. The contralateral limb was then inserted via the left common femoral artery incision. The landing zone was in the common iliac arteries just above the origin of the internal iliacs in one case and distal to its origin in the other (after embolization of one internal iliac artery). The stent-graft was expanded with a low pressure (2 Atm) balloon. Completion

Table 1. Conventional open surgery for AAA

Patients	Symptoms	Complications	Follow-up and outcome
Conventional open surgery for AAA			
1	Abdominal pain	None	12 years
2	None	Aortic pseudoaneurysm at 36 months	Died
3	Abdominal and back pain, and claudication	Ischemic leg, femoral and popliteal pseudoaneurysms at 14 months, and ischemic leg at 23 months	Above-knee amputation
Endovascular repair for AAA			
1	Back pain	Periprocedural fever	34 months
2	None	Periprocedural fever and transient nephropathy	28 months

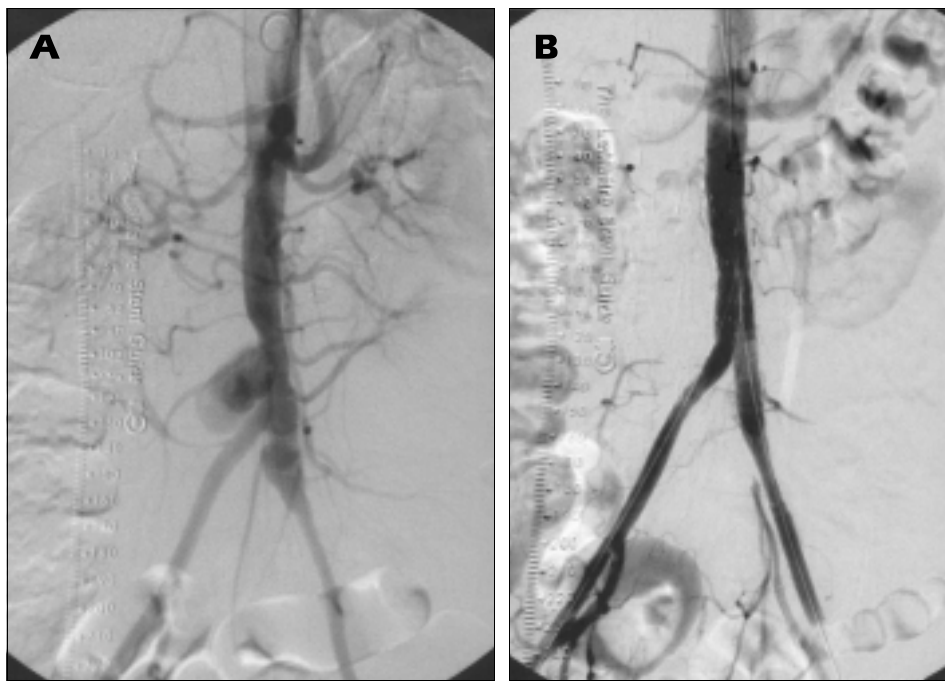


Figure 2. [A] Anterior-posterior projection of a transfemoral angiogram showing a pigtail catheter in the supracoeliac aorta, an irregular saccular aneurysm in the distal aorta and a fusiform aneurysm in the left iliac artery. [B] Angiogram of the same patient after insertion of a Talent stent-graft demonstrating complete occlusion of the aneurysm.

arteriography demonstrated the well-positioned stent-graft without leaks [Figure 2]. Overall, the procedures were completed in less than 2 hours using a maximum of 115 ml contrast medium (Iopamiro). These two patients returned to the ward after a short stay in recovery and were discharged on the third postprocedural day. Recovery was uneventful apart from fever on the night of the procedure in both patients, and temporary contrast-induced nephropathy (rise in creatinine level to 1.7 mg/dl) in one. At follow-up visits the abdomen was not tender and there were no aneurysms in the groins in either patient. CT angiography was obtained 1 month following the endovascular treatment and every 6 months thereafter. Good positioning and patency of the graft was demonstrated. A protocol of early and late CT scans confirmed that there were no leaks. The aneurysmal sac showed a considerable regression. At the present time, 34 and 28 months after the procedure, the patients are without anastomotic pseudoaneurysm.

Discussion

It is common practice to treat large AAAs in order to prevent rupture and death. Surgery is performed in the majority of these patients. Technical difficulties associated with surgical treatment in Behçet syndrome are due to the nature of the histopathologic changes: namely, vasculitis in the vasa vasorum and thickening of the media with separation of the elastic fibers. Recurrent false aneurysms in anastomotic sites may result in as high as 30–50% of cases [12–14]. To avoid such complications the anastomoses should be done in macroscopically disease-free segments. Some authors have also suggested aneurysmorrhaphy, ligation of aneurysms when possible, or wrapping the anastomoses by sutures

with pledget [13–15]. In the present study, when open surgery was performed the anastomoses were placed as far as possible from the aneurysm. Early postoperative follow-up was normal. However, 14 months and 3 years after surgery, pseudoaneurysms were encountered in 3 of 8 anastomoses (38%), an incidence in agreement with other studies [13–15]. Anastomotic pseudoaneurysms in patients with Behçet syndrome tend to grow and rupture and still harbor the notorious risk of recurrent anastomotic aneurysm after every repair. The threat, especially when dealing with the aorta, is so real that it warrants meticulous follow-up with ultrasound, CT angiography, or magnetic resonance angiography at least every 6 months after vascular surgery [16].

In the last years endovascular repair was established and gained popularity especially for poor risk surgical patients [17–19]. Review of the literature revealed only a handful

of case reports in which endovascular treatment (for fistulae and aneurysms) was used in patients with Behçet syndrome [20–24]. The first published report was in 1998 [20]; and treatment of one patient, described herein, followed as a short report [22].

We did not encounter any of the potential difficulties of the endovascular repair technique, enabling a straightforward short procedure. The aneurysmal sac [Figure 1 and 2A] was short, as seen with saccular rather than diffuse aneurysms, and a long neck allowed better anchoring of the stent-graft to the aorta (in order to avoid proximal – type I – leak). Only one embolization was necessary to prevent a type II leak (retrograde leak from the inferior mesenteric artery or lumbar arteries). The patients were relatively young and therefore had only mild atherosclerotic changes and no elongation or tortuosity of the iliac arteries, enabling easier passage of the introducer. Sharp angles might increase material wear and tear, resulting in migration or fracture in a long-standing stent-graft. Overall, the postoperative course was easier and the length of hospital stay considerably shorter in our patients treated with endovascular repair (3 vs. 6 days). The short and mid-term result is favorable, demonstrating shrinkage of the aneurysmal sac. Moreover, clinically and radiologically, after follow-up of 28–34 months, there is no evidence of a leak or development of a femoral pseudoaneurysm. Although late pseudoaneurysm may occur eventually in the common femoral artery due to the dissection and sutures, it lends itself to an easier treatment as compared to aortic pseudoaneurysm.

The enthusiasm for endoluminal treatment is considerable, however there are some major concerns regarding long-term durability since no prosthesis has remained in continuous

unmodified use for long. In addition, various kinds of endoleaks, migration of the stent-graft, and the fact that more than 20% of patients require re-intervention (proximal or distal extensions or embolizations) after 1 year, prompted a leading article that referred to endovascular treatment as “a failed experience” [25].

The advantages of durability, less contrast media required before and after treatment, and immediate availability of the open surgical procedure compared to endovascular repair are less striking in young and non-atherosclerotic patients especially when avoiding the notorious anastomotic aneurysms.

In summary, vasculo-Behçet patients with AAA are better candidates for endovascular treatment than are atherosclerotic patients. Technical feasibility increases in these young patients due to the nature of the disease, enabling better positioning of a stent-graft and avoiding the notorious complication of anastomotic pseudoaneurysms in the aorta. Meticulous follow-up is mandatory, not only to ascertain the absence of anastomotic aneurysms in the femoral arteries but also to detect early on the migration of the stent-graft, late occurring leaks and wear and tear fractures of the device.

References

- Behçet H. Über rezidivierende Aphthose, durch ein Virus verursachte Geschwüre am Mund, am Auge und den Genitalien. *Derm Wochenschr* 1937;36:1152–7.
- Shimuzu T, Ehrlich GE, Inaba G. Behçet's disease (Behçet's syndrome). *Semin Arthritis Rheum* 1979;8:233–60.
- Kontogiannis V, Powell RJ. Behçet disease. *Postgrad Med J* 2000;76:629–37.
- Barnes CG. Behçet's syndrome – classification criteria. *Ann Med Interne (Paris)* 1999;150:477–82.
- Cacoub P, Sbai A, Wechsler B, et al. Vascular manifestations of Behçet's syndrome associated with solitary ulcerations and resolved with immunosuppressants. *Rev Med Intern* 2000;21:353–7.
- Lie JT. Vascular involvement in Behçet's disease: arterial and venous and vessels of all sizes. *J Rheumatol* 1992;19:341–2.
- Ko GY, Byun JY, Choi BG, Cho SH. The vascular manifestations of Behçet's disease: angiographic and CT findings. *Br J Radiol* 2000;73:1270–4.
- Koc Y, Gullu I, Akpek G, et al. Vascular involvement in Behçet's disease. *J Rheumatol* 1992;19:402–10.
- International Study Group for Behçet's Disease. Criteria for diagnosis of Behçet's disease. *Lancet* 1990;335:1078–80.
- Filiz A, Dikensoy O. Lethal aneurysm formation of pulmonary arteries in a woman with Behçet's disease. *Rheumatology* 2000;39:222–4.
- Okita Y, Ando M, Minatoya K, Kitamura S, Matsuo H. Multiple pseudoaneurysms of the aortic arch, right subclavian artery, and abdominal aorta in a patient with Behçet's disease. *J Vasc Surg* 1998;28:723–6.
- Mercan S, Sarigul A, Koramaz I, Demirturk O, Boke E. Pseudoaneurysm formation in surgically treated Behçet's syndrome. *Angiology* 2000;51:349–53.
- Barlas S. Behçet's disease. An insight from a vascular surgeon's point of view. *Acta Chir Belg* 1999;99:274–81.
- Freyrie A, Paragona O, Cenacchi G, Pasquinelli G, Guiducci G, Faggioli GL. True and false aneurysms in Behçet's disease: case report with ultrastructural observations. *J Vasc Surg* 1993;17:762–7.
- Tuzun H, Besirili K, Sayin A, et al. Management of aneurysms in Behçet's syndrome: an analysis of 24 patients. *Surgery* 1997;121:150–6.
- Ascione R, Modi P, Triggiani D, Iannelli G, Spampinato N. Detection of postoperative pseudoaneurysms following abdominal aortic aneurysm repair in Behçet's disease by MRA. *J Cardiovasc Surg* 2002;43:251–4.
- Parodi JC. Endovascular repair of aortic aneurysms, arteriovenous fistulas, and false aneurysms. *World J Surg* 1996;20:655–63.
- May J, White GH, Yu W, Waugh R, Stephen MS, Harris JP. Repair of abdominal aortic aneurysms by the endoluminal method: outcome in the first 100 patients. *Med J Aust* 1996;165:549–51.
- Blum U, Voshage G, Lammer J, et al. Endoluminal stent-grafts for infrarenal abdominal aortic aneurysms. *N Engl J Med* 1997;336:13–20.
- Vasseur MA, Haulon S, Beregi JP, Le Tourneau T, Prat A, Warembourgh H. Endovascular treatment of abdominal aneurysmal aortitis in Behçet's disease. *J Vasc Surg* 1998;27:974–6.
- Bonnote B, Krause D, Fanton AL, Theron J, Chauffert B, Lorcerie B. False aneurysm of the internal carotid artery in Behçet's disease: successful combined endovascular treatment with stent and coils. *Rheumatology* 1999;38:576–7.
- Nitecki SS, Ofer A, Karram T, Engel A, Hoffman A. Abdominal aortic aneurysm in Behçet's disease treated by endoluminal stent-graft. *EJVES Extra* 2001;2:78–81.
- Park JH, Chung JW, Joh JH, et al. Aortic and arterial aneurysms in Behçet disease: management with stent-grafts – initial experience. *Radiology* 2001;220:745–50.
- Kutlu R, Gulcan O, Akbulut A, Turkoz R, Baysal T. Endovascular treatment of a huge saccular abdominal aortic aneurysm in a young Behçet patient: mid-term result. *BMC Med Imaging* 2002;2:1–4.
- Collin J, Murie JA. Endovascular treatment of abdominal aortic aneurysm: a failed experience. *Br J Surg* 2001;88:1281–2.

Correspondence: Dr. S.S. Nitecki, Dept. of Vascular Surgery and Transplantation, Rambam Medical Center, P.O. Box 9602, Haifa 31096, Israel.
Phone: (972-4) 854-3119
Fax: (972-4) 854-3119
email: s_nitecki@rambam.health.gov.il