

## Ischemic Finger Ulcer as a Presenting Symptom of Systemic Sclerosis

Alexandra Balbir-Gurman MD, Doron Markovits MD PhD, Abraham M. Nahir MD PhD, Alexander Rozin MD and Yolanda Braun-Moscovici MD

Department of Rheumatology, Rambam Medical Center, Haifa, Israel

**Key words:** ischemic finger ulcer, low molecular weight heparin, Raynaud's phenomenon, systemic sclerosis

*IMAJ 2005;7:531-532*

Raynaud's phenomenon is a well-recognized feature of systemic sclerosis. It generally precedes the appearance of other manifestations of the disease, such as skin thickening and internal organ involvement. Ischemic finger ulcers are often the result of severe long-standing RP, but as a presenting symptom of scleroderma are extremely rare. The treatment of ischemic ulcers due to RP is challenging. In cases of uncontrolled finger ischemia, Ca-channel antagonists are not efficient, and prolonged hospitalization with numerous intravenous infusions of a stable prostacyclin analog, iloprost, may be necessary. We describe a patient with acute ischemic finger ulcer that preceded the appearance of typical RP attacks and scleroderma skin changes.

### Patient Description

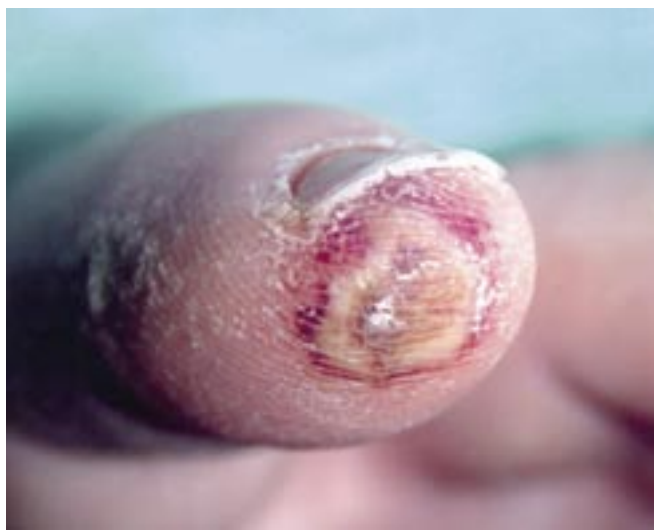A 48 year old woman with an uneventful medical history presented to our Emer-

gency Department complaining of severe pain and the appearance of an ulcer on the top of her left index finger 2 weeks earlier. The patient denied smoking and the use of ergotamins or oral contraceptives. There was no history of thrombosis, spontaneous abortion, or changes in skin color upon exposure to cold. General physical examination, including skin, heart, lung and abdomen, was unremarkable. Pulses above the radial, ulnar, dorsalis pedis, and tibialis posterior arteries were palpable. A necrotic skin ulcer (4 mm diameter) surrounded by an ischemic area (10 mm diameter) was found on the top of her left index finger [Figure A]. Laboratory tests, including complete blood count, general biochemistry, lipid status, coagulation tests (prothrombin time, activated partial thromboplastin time, lupus anticoagulant, antithrombin III, protein C, protein S, homocystein), and general urine were

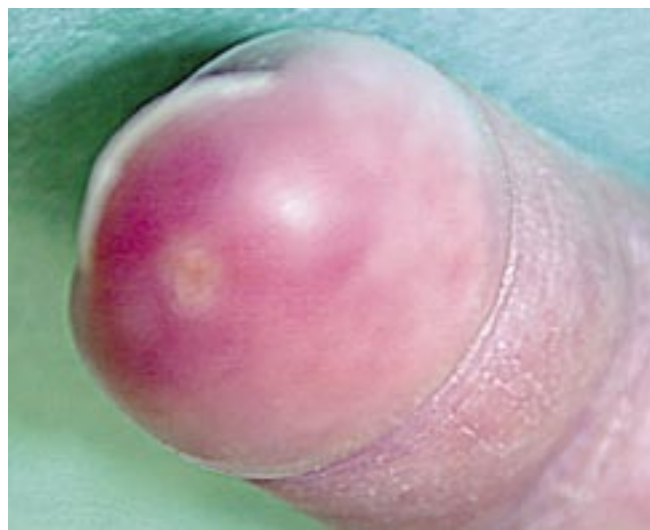
normal. Erythrocyte sedimentation rate was slightly elevated (40 mm/hour). Tests for antinuclear (speckled pattern) and anticentromere antibodies were positive; antibodies to DNA, extractible nuclear antigen, topoisomerase, and cardiolipin were not found. X-rays of her hands did not reveal underlying calcinosis. Normal arterial blood flow was reported in the radial, ulnar, common palmar digital, dorsal metacarpal, palmar digital, and dorsal digital arteries on Doppler ultrasonography. Capillaroscopy of the nailfold bed revealed several enlarged capillary loops accompanied by a prominent capillary loop dropout.

Treatment with intravenous infusions of the synthetic prostacyclin analog iloprost, 50 µg/daily for 5 consecutive days, led to partial pain relief and a halt to the spread of necrotic skin changes. At

RP = Raynaud's phenomenon



[A]. Central area of skin and underlying tissue necrosis with surrounding ischemic skin



[B]. Repaired skin ulcer after 3 months of LMWH treatment

that point, the treatment regimen was switched to daily ambulatory subcutaneous injections of low molecular weight heparin (enoxaparin 1 mg/kg) and nifedipin (30 mg/daily). Under this treatment regimen, progressive healing and complete repair of her index finger ulcer was achieved over the next 3 months [Figure B]. LMWH was then discontinued.

Six months later, the patient started to suffer from rare but typical RP attacks on exposure to cold, without new ulcers, but scleroderma finger skin thickening limited to the fingers alone was noted during follow-up. Skin biopsy showed characteristic changes of scleroderma – collagen accumulation and perivascular lymphocyte infiltration in the epidermis.

### Comment

This patient's course was unusual, in that she presented with finger-top necrosis as the initial manifestation of systemic sclerosis. Findings of destroyed capillary bed on capillaroscopy and a positive speckled pattern of antinuclear and positive anticentromere antibodies were the only clues of underlying collagen vascular disease [1]. It should be emphasized that finger ischemic ulcers, abnormal capillary bed changes on microscopy, and positive anticentromere antibodies are not included in the diagnostic criteria of systemic sclerosis. We contend that an abnormal immune study and/or signs of capillary

damage could be helpful in identifying patients at high risk for the development of scleroderma.

The treatment of ischemic finger ulcer due to SSc is problematic. The effectiveness of Ca-channel blockers has been demonstrated in patients with RP but not with active ischemic finger ulcer. Iloprost is effective in healing ischemic ulcerations but requires prolonged and often in-patient treatment. The role of anticoagulation in RP secondary to SSc has not yet been established. In other ischemic conditions (unstable angina and non-ST segment elevation myocardial infarction, recurrent ischemic strokes), LMWH led to sustained clinical improvements in ischemic outcomes (reduction in the rate of recurrent myocardial infarctions and mortality in patients with acute coronary syndrome; reduction in recurrent ischemic neurologic events and disability in patients with strokes) [2]. The rationale for using LMWH in SSc patients could be based on findings of endothelial dysfunction, intimal proliferation, vascular wall thickening, and enhanced platelet aggregation in involved vessels [3]. In patients with severe Raynaud's phenomenon, LMWH was well tolerated and potentially beneficial. It improved mean finger blood flow recovery time after 4 weeks of treatment, and reduced serum levels of circulating adhesion molecules ICAM-1, VCAM-15 and E-selectin [4]. In our patient, treatment with LMWH was effective in healing the ulcer; it was well tolerated and safe as an ambulatory treatment option.

In conclusion, we present a patient in whom ischemic finger necrosis preceded

the development of Raynaud's phenomenon and systemic sclerosis. A search for immune abnormalities (antinuclear antibodies, anticentromere antibodies) and changes in the nail capillary bed could be helpful in similar cases for predicting the development of collagen vascular disease. In the absence of effective ambulatory therapies for ischemic finger ulcer, the addition of LMWH to a short course of iloprost intravenous infusions may be useful in finger ulcer repair.

**Acknowledgment.** The authors thank Mrs. M. Perlmutter for her help in the preparation of this paper.

### References

1. Weiner ES, Hildebrandt S, Senecal JL, et al. Prognostic significance of anticentromere antibodies and anti-topoisomerase I antibodies in Raynaud's disease. A prospective study. *Arthritis Rheum* 1991;34:68-77.
2. Turpie AG. State of the art – a journey through the world of antithrombotic therapy. *Semin Thromb Hemost* 2002;28(Suppl 3):3-11.
3. Kahaleh MB. Vascular involvement in systemic sclerosis (SSc). *Clin Exp Rheumatol* 2004;22(Suppl 33):S19-23.
4. Denton CP, Howell K, Stratton RJ, et al. Long-term low molecular weight heparin therapy for severe Raynaud's phenomenon: a pilot study. *Clin Exp Rheumatol* 2000;18:499-502.

**Correspondence:** Dr. A. Balbir-Gurman, Consulting Rheumatologist, Dept. of Rheumatology, Rambam Medical Center, P.O. Box 9602, Haifa 31096, Israel. Phone: (972-4) 854-2268. Fax: (972-4) 854-2985. email: a\_balbir@rambam.health.gov.il

LMWH = low molecular weight heparin

SSc = systemic sclerosis

ICAM = intercellular adhesion molecule

VCAM = vascular cell adhesion molecule

## Capsule



### No rest for microglial cells

Resident microglial cells, the brain's immune surveillance cells, are thought to remain in a quiescent dormant state until they respond to damage or disease. Nimmerjahn et al. filmed living fluorescent microglia *in situ* for up to 10 hours and found that so-called resting microglia in the normal brain are, in fact, not resting at all but continuously exploring their

microenvironment. Microglia responded extremely rapidly to disturbances (lesions created in the blood-brain barrier with a laser) by switching their behavior from patrolling the brain to shielding the injured site.

*Science* 2005;308:1314

Eitan Israeli