Darier's Disease

Eyal Reinstein MD PhD and Yehuda Shoenfeld MD FRCP

Department of Medicine B and Center for Autoimmune Diseases, Sheba Medical Center, Tel Hashomer, Israel
Affiliated with Sackler Faculty of Medicine, Tel Aviv University, Ramat Aviv, Israel

IMAJ 2006;8:588

A 59 year old man was admitted due to chest pain and dyspnea. Physical examination revealed numerous skin-colored, yellow and brown warty keratotic papules over the chest and abdomen, consistent with Darier's disease. The patient reported that the disease had been diagnosed about 50 years previously, but since it was asymptomatic he was never treated.

Darier's disease (keratosis follicularis) is a genetic disorder of an autosomal dominant trait attributed to mutations in the gene *ATP2A2* that encodes a sarcoplasmic reticulum Ca^{2+} pump. The disease is characterized by hyperkeratotic papules in the epidermis, nails and mucous membranes; it follows a chronic course with exacerbations and remissions. The main complaint of patients with Darier's disease is pruritus in the affected skin areas. Various treatments exist, depending on the severity of the disease. Mild and moderate cases require moisturizers, sunscreens and topical steroids, whereas severe cases are treated with topical and oral retinoids and, sometimes, surgery.

Correspondence: Dr. Y. Shoenfeld, Head, Dept.. of Medicine B and Center for Autoimmune Diseases, Sheba Medical Center, Tel Hashomer 52621, Israel.
Phone: (972-3) 530-2652
Fax: (972-3) 535-2855
email: shoenfel@post.tau.ac.il

Erratum

In the June issue, in the article by Desatnik et al, entitled "The transient efficacy of a single intravitreal triamcinolone acetonide injection for diabetic macular edema" (page 383–87), the legend accompanying the figure was incorrect. The correct legend appears here with the figure.

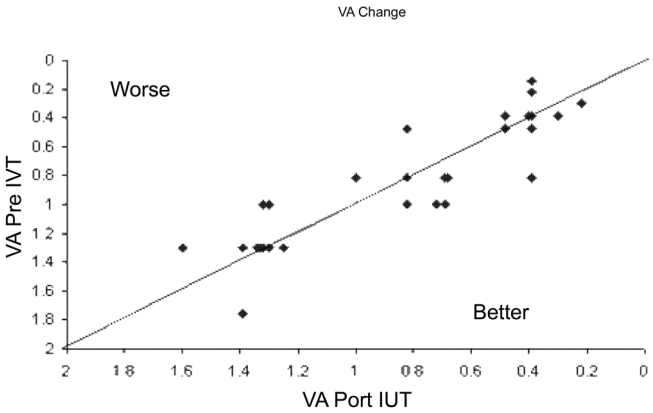

Figure 1. Individual final vs. initial visual acuity (VA) results. The VA data are given in logMAR units. Note: some of the points in the graph represent more than one eye.