

Stroke in Congenital Heart Disease and Patent Foramen Ovale

Rafael Hirsch MD¹ and Jonathan Y. Streifler MD²

¹Adult Congenital Heart Unit, Department of Cardiology, Rabin Medical Center (Beilinson Campus), Petah Tikva, Israel

²Neurology Unit, Rabin Medical Center (Golda Campus), Petah Tikva, Israel

Affiliated to Sackler Faculty of Medicine, Tel Aviv University, Ramat Aviv, Israel

Key words: congenital heart disease, patent foramen ovale, paradoxical embolism, percutaneous device closure

Abstract

Congenital heart disease is usually regarded as an esoteric field of medicine, dealt with primarily by dedicated specialists. However, over the last two decades, increased attention has been given by the medical profession, the media and the general public to the possible association between a minor and common congenital heart defect, namely patent foramen ovale, and stroke. In recent months, unusual and unfortunate circumstances have made this topic one of the most fiercely debated medical issues in Israel. It is the belief of the authors of this paper that the association of PFO and stroke can be better understood if the PFO is viewed as part of the broader context of congenital heart disease, and as such it will be presented. Paradoxical embolism is a mechanism of stroke unique to congenital heart disease. The direction and volume of shunted blood in various conditions have a central role in determining the risk of stroke, as will be explained. With this basic knowledge in mind, we shall critically assess the potential role of PFO in stroke patients, suggesting that each case be evaluated individually using the above-mentioned principles. Conditions that enhance the formation of clot or other embolic material will be discussed briefly. The review will conclude with the various treatment options and our center's own experience with this challenging topic.

IMAJ 2005;8:798-802

Since this review deals with a controversial issue, we shall start the discussion on safe ground, with children and adults who have cyanotic congenital cardiac malformations, a well-established risk for stroke and brain abscess.

Stroke and brain abscess in cyanotic congenital heart disease

In the normal circulatory system, the pulmonary capillary bed acts as a filter, preventing embolic material carried by the venous blood from reaching the systemic circulation. A systemic embolic event, including stroke, which is a result of embolic material originating in the venous compartment bypassing the pulmonary capillary filter, is defined as paradoxical embolism [1-5].

Cyanosis is the clinical presentation of low oxygen content in systemic arterial blood, resulting from a large volume of

venous blood (usually 1-2 L/min) that is shunted directly into the systemic circulation, with the potential of carrying a clot or other embolic material to cause stroke or brain abscess. Fallot's tetralogy and the Eisenmenger syndrome are two of the better known examples of cyanotic conditions. This mechanism of stroke via paradoxical embolism is well established [6-9]. In cases of infected clot, brain abscess ensues [7]. Such patients are also at risk of iatrogenic events, caused by the inadvertent introduction of small amounts of air into an intravenous line, and special precautions are needed to prevent this complication.

Other congenital heart defects with a potential for paradoxical embolism

As paradoxical embolism requires an abnormal communication between the venous and arterial compartments, by definition, all patients suspected of having had a stroke by this mechanism must have some sort of congenital heart defect. These include patients who had corrective surgery for cyanotic disease, those with a shunt lesion shunting predominantly left to right and patients with a patent foramen ovale. When compared to cyanotic malformations, all the other above-mentioned cardiac conditions carry a much lower risk of stroke by paradoxical embolism. That is where the controversy begins. From our large experience with congenital heart disease, we believe that what is often lacking in the literature, and could be the reason for contrasting conclusions, is a careful evaluation of key factors in cardiac morphology and hemodynamics. Those are: right atrial pressure, left atrial pressure, size and shape of the communication, the coexistence of other structural anomalies such as an atrial septal aneurysm and a prominent eustachian valve, and conditions that enhance clot formation. A brief discussion of the various factors will follow. For a more detailed review we refer readers to our previously published article "Congenital heart disease and stroke" [10].

Elevated right atrial pressure

The best-known condition with a constantly high right atrial pressure is the Fontan circuit. An interatrial communication in these patients will constantly shunt right to left. There is a well-known increased risk of stroke in Fontan patients, although paradoxical embolism is not the only mechanism.

Paradoxical embolism is not entirely eliminated by surgical repair or palliation of a cyanotic congenital malformation [11-16]. Patients who had suboptimal or late repair of cyanotic malforma-

This paper is an adaptation of a previous publication in: *Seminars in Cerebrovascular Disease and Stroke*, volume 5(1):13-20, © 2005 Elsevier Inc., with permission of Elsevier [ref. 10].

PFO = patent foramen ovale

tions often have increased right atrial pressure. If they still have an interatrial communication, they are at increased risk of stroke [17].

In patients with a PFO, conditions that temporarily raise right atrial pressure also increase the risk of stroke; for example, acute myocardial infarction with right ventricular involvement and acute pulmonary embolism.

Elevated left atrial pressure

Elevated left atrial pressure could be considered a safeguard against paradoxical embolism. Often, in elderly hypertensive patients, the left atrium dilates, stretching the two layers of the oval fossa until a small left-to-right shunt ensues. This small jet, easily recognized on color Doppler because of its relatively high velocity, is often referred to as a PFO. However, patients with this finding are the least likely of any with an interatrial communication to have a stroke by paradoxical embolism, as the embolus must cross “up-stream” against a relatively strong and constant current. On the other hand, these patients usually have a higher incidence of the well-established risk factors for stroke due to their older age, arterial hypertension, atrial fibrillation, etc. The fact that these particular PFOs are the ones most easily diagnosed, but least likely of all PFOs to cause harm, may lead to an underestimation of the risk incurred by a PFO in stroke patients.

Size, shape and additional features of the interatrial communication

In order for a blood clot to cause stroke, it must be able to occlude a cerebral artery, i.e., have a diameter of about 3 mm. A communication that does not enable passage of a clot this size should not be considered a potential risk of stroke. Once the size is big enough for the easy passage of a clot, a larger size does not necessarily correlate with a further increase of risk. Hemodynamics and anatomic features of the communication and surrounding structures are much more important than size itself.

An atrial septal defect, as large as it may be, carries a relatively low life-long risk of stroke [18]. We have many ASD patients who have been diagnosed or treated at an advanced age. Still, only a few have experienced stroke before treatment, and those who did often had atrial fibrillation or age-related risk factors and, therefore, the correlation with the congenital defect could not be well established. This low risk despite a large communication is a result of the usual large left-to-right shunt throughout most of the cardiac cycle, preventing a clot from crossing right to left. However, an abrupt increase in intrathoracic pressure – as during cough or the Valsalva maneuver – will result in a brief period of shunt reversal with a potential for paradoxical embolism, requiring the coincidental presence of a clot in the right atrium at that time.

Unlike a true ASD, a PFO is not a hole but a rather complex anatomic structure consisting of two overlapping flaps of tissue, creating a channel. In most instances the amount of blood that

crosses it in either direction is very small. The anatomy of the PFO is such that during an increase in left atrial pressure the two flaps come together; however, with an increase in right atrial pressure the two flaps separate, allowing right-to-left shunting. In patients who have a thin and mobile inferior aspect of the PFO, as is the case with a coexisting atrial septal aneurysm, this transient separation of the flaps creates a much larger communication, which allows a relatively large volume of venous blood into the systemic circulation. During balloon sizing of the defect at catheterization of patients with PFO+ASA, it is not unusual to see the PFO stretching four to six times its original size. It is the unique combination of anatomy and hemodynamics that make these particular defects prone to paradoxical embolism [19-21].

When viewed from the right atrial aspect, the PFO is oriented caudo-cranially, so that blood from the IVC is better oriented than blood from the SVC for crossing into the left atrium. The IVC flow across the PFO is further increased with the coexistence of a prominent Eustachian valve, which at the same time prevents SVC flow from reaching anywhere near the defect. This has important implications when testing PFOs for their embolic potential, as will be described.

Testing the potential for paradoxical embolism

Overtly cyanosed patients are at increased risk for paradoxical embolism by definition, and do not need any further testing. The following discussion concerns all other patients with stroke suspected to be a result of paradoxical embolism.

In real-life conditions, not all the above-mentioned hemodynamic and anatomic considerations are easily discerned, especially when diagnosis with non-invasive techniques is sought. As mentioned above, color Doppler is excellent for detecting left-to-right shunts, but poor in detecting right-to-left shunts due to their very low velocity and often transient nature. The solution is contrast-echocardiography, performed during transthoracic echocardiogram or transesophageal echocardiogram and contrast transcranial Doppler. All those tests share the same principle, applying an intravenous injection of echogenic “micro-bubbles,” prepared with agitated saline or commercial echo-contrast material, and looking for them in the arterial circulation, i.e., for those micro-bubbles that were “paradoxically embolized.” The number of micro-bubbles appearing in the systemic circulation correlates with the risk of embolism. When no micro-bubbles appear spontaneously, a provoked passage is attempted by asking by the patient to cough or by performing a Valsalva maneuver.

In general, TEE is the most informative investigation [22-24]. It provides anatomic information on the structure of the interatrial septum and related structures – such as a septal aneurysm and an elongated eustachian valve, and the size, shape and number of interatrial communications – and will help rule out other potential risks for stroke, e.g., thrombus in the left atrial appendage

ASA = atrial septal aneurysm

IVC = inferior vena cava

SVC = superior vena cava

TEE = transesophageal echocardiogram

ASD = atrial septal defect

and aortic atheroma. When combined with contrast-echo study, it will show the amount of bubbles crossing, but it should be borne in mind that the patient is often sedated which may have an impact on physiology (usually to reduce atrial pressure and decrease the right-to-left shunt) and prevent the performance of a Valsalva maneuver. It is also an unpleasant investigation and too cumbersome as a screening test in most cases.

Contrast-TCD has been shown in several studies to be a sensitive and reliable method for detecting right-to-left shunts [23,25]. It is well standardized, and is at least semi-quantitative, with significant right-to-left shunt resulting in "curtains" of micro-bubbles reaching the middle cerebral artery. One drawback of this method is the inability to see the quality of the injected bolus. On echocardiography, one must see dense opacification of the right heart chambers for a contrast study to be informative. The other drawback is more important and has not yet been addressed, to the best of our knowledge. Most sources of venous embolism are in the lower extremities and pelvis [26]. In the event of paradoxical embolism the thrombus had reached the heart via the IVC, not the SVC. Yet, we perform our contrast studies by injecting into the arm. In case of a prominent eustachian valve, contrast injected in the arm may be prevented from reaching the PFO, giving a false negative study [Figure 1]. Therefore, if either a contrast-TTE or contrast-TCD are relied upon for screening the potential for paradoxical embolism, it is better to inject in the leg, despite the inconvenience.

The other component – the embolic substance

Having discussed the conditions enabling the paradoxical passage of embolus, we shall briefly discuss conditions that produce the embolic substance.

Medical conditions associated with hypercoagulability, either genetic or acquired, predispose to venous rather than arterial thrombosis. However, with the coexistence of PFO and other congenital heart conditions, this may translate to increased risk of stroke [27-29]. Among acquired conditions that enhance venous thrombosis, one can name malignancy, major surgery, orthopedic insults, other bedridden states, and even long-haul flights [30,31]. Some of our PFO patients had a stroke under these circumstances.

The PELVIS study [26] showed that patients with cryptogenic stroke have a higher incidence of deep vein thrombosis, suggesting stroke occurred by mechanism of paradoxical embolization.

Indwelling catheters increase the risk of thrombus formation and paradoxical embolization [32]. Intravenous drug abuse has been associated with stroke and cerebral abscess.

Patients with a PFO or other conditions associated with right-to-left shunting have an increased risk of decompression sickness when performing deep water diving [33]. In order to prevent this complication, especially in professional divers, it is advised to perform transcatheter PFO closure.

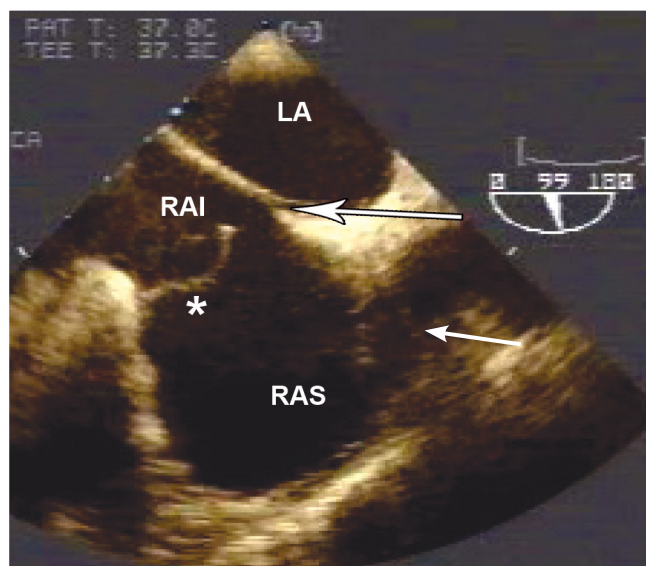


Figure 1. A vertical plane TEE showing a prominent eustachian valve (*) separating the right atrium into two distinct chambers – inferior (RAI) with blood coming from the inferior caval vein directed towards a PFO (arrow), and a superior chamber (RAS). Contrast study performed through the arm gave a false negative result, because bubbles arriving from the superior caval vein remained in the superior chamber. The same study performed through the legs was strongly positive for right-to-left shunting.

Treatment options

In order to treat a condition, it must be regarded as one that poses a real medical threat, and in the case of stroke, the threat of stroke recurrence. There are no prospective studies on the natural history of stroke recurrence in a large cohort of patients with cryptogenic stroke and suspected paradoxical embolism, and such studies are unlikely to ever be conducted. Studies to date have shown a great variation in annual recurrence rate, ranging from 0 to 19% [20,21,34]. It would be possible to study the primary event rate of stroke in people who have the substrate for paradoxical embolism, after screening very large populations of young adults, e.g., by contrast-TCD, and following them for many years, if the resources for conducting such a large scale study became available.

Not knowing the recurrence rate makes it difficult if not impossible to analyze the effect of any treatment method provided for secondary prevention. Therefore, most practitioners treat this condition according to their personal synthesis of the incomplete and often conflicting data in the literature and their own experience.

As paradoxical embolism requires both a clot and an abnormal anatomic communication, treatment should address one of the two: either preventing the formation of more clots by using medication (antiplatelet agents, anticoagulants), or closing off the communication by a mechanical barrier at surgery or catheterization.

With regard to medical treatment, coumadin has not been shown to be superior to aspirin in most studies, except for small

TCD = transcranial Doppler
TTE = transthoracic echocardiogram

high risk groups where it had a marginal benefit, but it should be borne in mind that in other conditions involving thromboembolism, deep vein thrombosis, pulmonary embolism and atrial fibrillation, the treatment of choice is anticoagulants and not antiplatelets. Some of these conditions – e.g., atrial fibrillation – were studied extensively and involved thousands of patient-years before this conclusion was reached, an option that is not practical in the relatively small group discussed here.

With the extensive experience that has been gained in recent years with several PFO closure devices, endovascular closure of PFO has been shown to be easy and safe and, consequently, has become very popular. Some physicians advocate its use without further studies [35]. In a recent publication on the use of a single device, namely, the Amplatzer septal occluder (both ASD and PFO devices), there were only 28 major complications including 4 deaths, from among 80,000 procedures [36]. It is believed that device closure enables stopping medical treatment about 6 months after a successful closure.

Most studies today try to compare the medical approach with the interventional one. However, researchers have difficulty in convincing patients to accept and physicians to provide the medical arm. Although this preference of device closure may seem appealing, it cannot be considered scientifically sound. A retrospective study comparing transcatheter closure to medical treatment found a small, non-statistically significant advantage of the former at 4 years follow-up, which was apparent mainly in the higher risk group [37].

The Rabin Medical Center Experience

With present knowledge, the issue of PFO and stroke remains highly controversial in terms of both causality and treatment. The concluding section of this paper will discuss the approach of the Adult Congenital Heart Unit at Rabin Medical Center and summarize our experience.

Unlike other congenital cardiac malformations, a PFO does not cause damage to the heart. Stroke is a neurologic event, and the role of the cardiologist is in providing a service to the neurologist. The neurologist should be the one to assess the likelihood that the stroke was caused by an embolic event. Only if remote embolism is suspected and other etiologies have been ruled out, should a PFO be considered at all.

We often prefer contrast-TCD as a screening study, and only if positive do we proceed with TEE. In young patients we sometimes choose TEE as a first study (according to the literature, the cutoff point for age is around 55 years). TTE is not a good screening test since it will most likely detect by color-Doppler those PFOs with spontaneous left-to-right shunts, which are the ones least likely to enable paradoxical embolization, and miss the ones with no shunt or with a right-to-left shunt, that are the real threats but often do not produce an adequate Doppler signal.

On TEE, the size of the PFO is measured, and the coexistence of additional septal defects, ASA, a prominent eustachian valve and direction of flow, spontaneous and provoked, are established. The potential for paradoxical embolization is judged indepen-

dently from the clinical context [38]. A PFO that is judged to have a low probability of causing paradoxical embolism is usually not considered for closure, even in the very young. On the other hand, if it is sizable, with ASA and spontaneous right-to-left shunting, it may be considered for closure even in older patients, especially if they had recurrent events. During TEE we rule out other sources of embolism, e.g., left atrial appendage thrombus and aortic atheroma. If the stroke was recent, the patient also has an ultrasound study of the legs and pelvis to rule out venous thrombosis. Young patients are screened for hypercoagulability disorders.

As far as medical treatment is concerned, it is our policy to treat these patients with coumadin, at international normalized ratio levels of 2–2.5. We consider percutaneous PFO closure a “coumadin-sparing” procedure. Coumadin is continued for 6 months after the procedure, and is stopped when a repeat contrast-TCD is negative. If it remains positive, we consult the neurologist whether to continue coumadin or switch to aspirin.

Since 1999, we have performed 34 procedures of PFO closure for the prevention of stroke (and around 120 procedures for hemodynamic ASDs). There were 17 female patients (50%) with a mean age of 47 ± 13 years (range 24–73 years). One patient had previously undergone surgery for Fallot's tetralogy and one had congenitally corrected transposition of the great arteries. The others had otherwise normal cardiac structure. In 29 patients (85%), an Amplatzer ASD occluder was used, mean device diameter 13 ± 5 mm (range 7–24 mm), and in 5 an Amplatzer PFO occluder – three large devices (35 mm) and two small (25 mm). The PFO devices were used only in non-stretchable defects, which would not be suitable for the ASD device. We prefer the ASD device; not only is it smaller in absolute size, but it also closes off the defect more efficiently. There were no procedural complications. One patient suffered a hemorrhagic stroke while on coumadin, awaiting the procedure (he later had his PFO closed).

Mean follow-up duration was 18 ± 17 months (range 1–60). There were two cases with positive contrast-TCD after 6 months, one is continuing treatment with coumadin, and one was switched to aspirin. Two cases of recurrence of minor neurologic events have been reported, both of which occurred after the cessation of coumadin.

Summary

We discussed the association of congenital heart disease and stroke through paradoxical embolism. We started with the cyanotic anomalies that are a well-established risk factor for stroke and cerebral abscess, and continued through the spectrum of anomalies, trying to show that some of the important anatomic and hemodynamic components that predispose to stroke in more complex congenital disease also exist in a subset of PFOs that we call “real” PFOs. These should be viewed as part of a continuum of malformations with a potential risk rather than a separate entity. In a carefully selected group of patients, we believe that percutaneous PFO closure is clinically justified, highly successful, and carries a very low risk.

References

1. Delvigne M, Vermeersch P, van den Heuvel P. Thrombus-in-transit causing paradoxical embolism in cerebral and coronary arterial circulation. *Acta Cardiol* 2004;59:669–72.
2. Kimura K, Hashimoto Y, Ishihara A, Miyayama H, Uchino M, Ando M. A case of paradoxical cerebral embolism through a patent foramen ovale diagnosed by necropsy. *Rinsho Shinkeigaku* 1994;34:56–60.
3. Garrett PJ, Mulcahy K, Burden RJ, Ng WC, Price PA. Paradoxical cerebral embolism originating from thrombus in tumour veins as presenting manifestation of retroperitoneal liposarcoma. *Br J Clin Pract* 1993;47:45–6.
4. Riding G, Daly K, Hutchinson S, Rao S, Lovell M, McCollum C. Paradoxical cerebral embolisation. An explanation for fat embolism syndrome. *J Bone Joint Surg [Br]* 2004;86:95–8.
5. Pham Dang C, Pereo Y, Champin P, Delecrist J, Passuti N. Paradoxical air embolism from patent foramen ovale in scoliosis surgery. *Spine* 2002;27:E291–5.
6. Iserin L. Cyanotic heart disease in the adult. *Arch Mal Coeur Vaiss* 2002;95:1100–3.
7. Kurlan R, Griggs RC. Cyanotic congenital heart disease with suspected stroke. Should all patients receive antibiotics? *Arch Neurol* 1983;40:209–12.
8. deVeber G. Arterial ischemic strokes in infants and children: an overview of current approaches. *Semin Thromb Hemost* 2003;29:567–73.
9. Pellicer A, Cabanas F, Garcia-Alix A, Perez-Higueras A, Quero J. Stroke in neonates with cardiac right-to-left shunt. *Brain Dev* 1992;14:381–5.
10. Hirsch R, Streifler JY. Congenital heart disease and stroke. *Semin Cerebrovasc Dis Stroke* 2005;5:13–20.
11. Mathews K, Bale JF Jr, Clark EB, Marvin WJ Jr, Doty DB. Cerebral infarction complicating Fontan surgery for cyanotic congenital heart disease. *Pediatr Cardiol* 1986;7:161–6.
12. Chun DS, Schamberger MS, Flaspohler T, et al. Incidence, outcome, and risk factors for stroke after the Fontan procedure. *Am J Cardiol* 2004;93:117–19.
13. Burkhart HM, Dearani JA, Mair DD, et al. The modified Fontan procedure: early and late results in 132 adult patients. *J Thorac Cardiovasc Surg* 2003;125:1252–9.
14. Bando K, Turrentine MW, Park HJ, Sharp TG, Scavo V, Brown JW. Evolution of the Fontan procedure in a single center. *Ann Thorac Surg* 2000;69:1873–9.
15. Day RW, Boyer RS, Tait VF, Ruttenberg HD. Factors associated with stroke following the Fontan procedure. *Pediatr Cardiol* 1995;16:270–5.
16. du Plessis AJ, Chang AC, Wessel DL, et al. Cerebrovascular accidents following the Fontan operation. *Pediatr Neurol* 1995;12:230–6.
17. Shneider H, Shiran A, Lorber A. Right ventricular diastolic dysfunction and patent foramen ovale causing profound cyanosis. *Heart* 2004;90:e31.
18. Shah D, Azhar M, Oakley CM, Cleland JG, Nihoyannopoulos P. Natural history of secundum atrial septal defect in adults after medical or surgical treatment: a historical prospective study. *Br Heart J* 1994;71:224–7.
19. Mattioli AV, Bonetti L, Aquilina M, Oldani A, Longhini C, Mattioli G. Association between atrial septal aneurysm and patent foramen ovale in young patients with recent stroke and normal carotid arteries. *Cerebrovasc Dis* 2003;15:4–10.
20. Mas JL, Arquizan C, Lamy C, et al., for the Patent Foramen Ovale and Atrial Septal Aneurysm Study Group. Recurrent cerebrovascular events associated with patent foramen ovale, atrial septal aneurysm, or both. *N Engl J Med* 2001;345:1740–6.
21. Messe SR, Silverman IE, Kizer JR, et al. Practice parameter: recurrent stroke with patent foramen ovale and atrial septal aneurysm. Report of the Quality Standards Subcommittee of the American Academy of Neurology. *Neurology* 2004;62:1042–50.
22. Blum A, Reisner S, Farbstein Y. Transesophageal echocardiography (TEE) vs. transthoracic echocardiography (TTE) in assessing cardio-vascular sources of emboli in patients with acute ischemic stroke. *Med Sci Monit* 2004;10:CR521–3.
23. Job FP, Ringelstein EB, Grafen Y, et al. Comparison of transcranial contrast Doppler sonography and transesophageal contrast echocardiography for the detection of patent foramen ovale in young stroke patients. *Am J Cardiol* 1994;74:381–4.
24. Meier B, Lock JE. Contemporary management of patent foramen ovale. *Circulation* 2003;107:5–9.
25. Droste DW, Lakemeier H, Ritter M, et al. The identification of right-to-left shunts using contrast transcranial Doppler ultrasound: performance and interpretation modalities, and absence of a significant side difference of cardiac micro-emboli. *Neurol Res* 2004;26:325–30.
26. Cramer SC, Rordorf G, Maki JH, et al. Increased pelvic vein thrombi in cryptogenic stroke. Result of the Paradoxical Emboli from Large Veins in Ischemic Stroke (PELVIS) Study. *Stroke* 2004;35:46–50.
27. Vomberg PP, Breederveld C, Fleury P, Arts WF. Cerebral thromboembolism due to antithrombin III deficiency in two children. *Neuropediatrics* 1987;18:42–4.
28. Rodriguez CJ, Homma S. Hypercoagulable states in patients with patent foramen ovale. *Curr Hematol Rep* 2003;2:435–41.
29. Ahmed S, Sadiq A, Siddiqui AK, Borgen E, Mattana J. Paradoxical arterial emboli causing acute limb ischemia in a patient with essential thrombocytosis. *Am J Med Sci* 2003;326:156–8.
30. Lapostolle F, Borron SW, Surget V, Sordelet D, Lapandry C, Adnet F. Stroke associated with pulmonary embolism after air travel. *Neurology* 2003;60:1983–5.
31. Isayev Y, Chan RKT, Pullicino PM. "Economy Class" stroke syndrome. *Neurology* 2002;58:960–1.
32. Johnson C, Galindez L. Multiple systemic emboli complicating the course of a patient with an atrial septal defect, an atrial septal aneurysm and an endocardial right atrial pacemaker lead. *P R Health Sci J* 1998;17:281–4.
33. Torti SR, Billinger M, Schwerzmann M, et al. Risk of decompression illness among 230 divers in relation to the presence and size of patent foramen ovale. *Eur Heart J* 2004;25:1014–20.
34. Homma S, Sacco RL, Di Tullio MR, Sciacca RR, Mohr JP. Effect of medical treatment in stroke patients with patent foramen ovale: patent foramen ovale in Cryptogenic Stroke Study. *Circulation* 2002;105:2625–31.
35. Furlan AJ. Patent foramen ovale and recurrent stroke: closure is the best option: Yes. *Stroke* 2004;35:803–4.
36. Amin Z, Hijazi ZM, Bass JL, Cheatham JP, Hellenbrand WE, Kleinman CS. Erosion of Amplatzer septal occluder device after closure of secundum atrial septal defects: review of registry of complications and recommendations to minimize future risk. *Catheter Cardiovasc Interv* 2004;63:496–502.
37. Windecker S, Wahl A, Nedeltchev K, et al. Comparison of medical treatment with percutaneous closure of patent foramen ovale in patients with cryptogenic stroke. *J Am Coll Cardiol* 2004;44:750–8.
38. De Castro S, Cartoni D, Fiorelli M, et al. Morphological and functional characteristics of patent foramen ovale and their embolic implications. *Stroke* 2000;31:2407–13.

Correspondence: Dr. R. Hirsch, Head, Adult Congenital Heart Unit, Department of Cardiology, Rabin Medical Center (Beilinson Campus), Petah Tikva 49100, Israel.
 Telefax: (972-3) 937-7063
 email: rafaelh@clalit.org.il