

## Endobronchial Stent for Malignant Airway Obstructions

Rinat Yerushalmi MD<sup>1</sup>, Eyal Fenig MD<sup>1</sup>, David Shitrit MD<sup>2</sup>, Danielle Bendayan MD<sup>2</sup>, Aaron Sulkes MD<sup>1</sup>, Dov Flex MD<sup>1</sup> and Mordechai R. Kramer MD<sup>2</sup>

<sup>1</sup>Oncology and <sup>2</sup>Pulmonary Institutes, Rabin Medical Center (Beilinson Campus), Petah Tiqva, Israel  
Affiliated to Sackler Faculty of Medicine, Tel Aviv University, Ramat Aviv, Israel

**Key words:** endobronchial stent, malignant obstruction, ambulatory procedure, brachytherapy, high dose rate

### Abstract

**Background:** Endobronchial stents are used to treat symptomatic patients with benign or malignant airway obstructions.

**Objectives:** To evaluate the safety and outcome of airway stent insertion for the treatment of malignant tracheobronchial narrowing.

**Methods:** The files of all patients with malignant disease who underwent airway stent insertion in our outpatient clinic from June 1995 to August 2004 were reviewed for background data, type of disease, symptoms, treatment, complications and outcome.

**Results:** Airway stents were used in 34 patients, including 2 who required 2 stents at different locations, and one who required 2 adjacent stents (total, 37 stents). Ages ranged from 36 to 85 years (median 68). Primary lung cancer was noted in 35% of the patients and metastatic disease in 65%. Presenting signs and symptoms included dyspnea (82%), cough (11.7%), hemoptysis (9%), pneumonia (5.9%), and atelectasis (3%). The lesions were located in the left mainstem bronchus (31%), trachea (26%), right mainstem bronchus (26%), subglottis (14.3%), and bronchus intermedius (2.9%). Conscious sedation alone was utilized in 73% of the patients, allowing for early discharge. Eighteen patients (50%) received brachytherapy to the area of obstruction. Complications included stent migration (one patient) and severe or minimal bleeding (one patient each). Ninety-four percent of the patients reported significant relief of their dyspnea. Three of the four patients who had been mechanically ventilated before the procedure were weaned after stent insertion. Median survival from the time of stent placement was 6 months (range 0.25–105 months).

**Conclusion:** Stent placement can be safely performed in an outpatient setting with conscious sedation. It significantly relieves the patient's symptoms and may prolong survival.

*IMAJ 2006;8:615–617*

Neoplastic lesions in the lung, either primary or metastatic, may cause airway obstruction or stenosis, with consequent respiratory distress, bleeding and infection. Several endoscopic treatments are currently available for the management of lung lesions. Metallic or silicone stents are inserted to maintain patency in cases of extrinsic compression, airway collapse, or obstructing endobronchial tumor. Nd:YAG laser is used for photocoagulation of bulky endobronchial lesions, and high dose rate brachytherapy delivers radiation directly to the target tissue, preventing tumor or granulation tissue growth [1-6]. This technique consists of placing radioactive sources close to or in contact with the target tissue. The source is capable of delivering a high dose rate of radiation directly to the target tissue, meaning treatment ses-

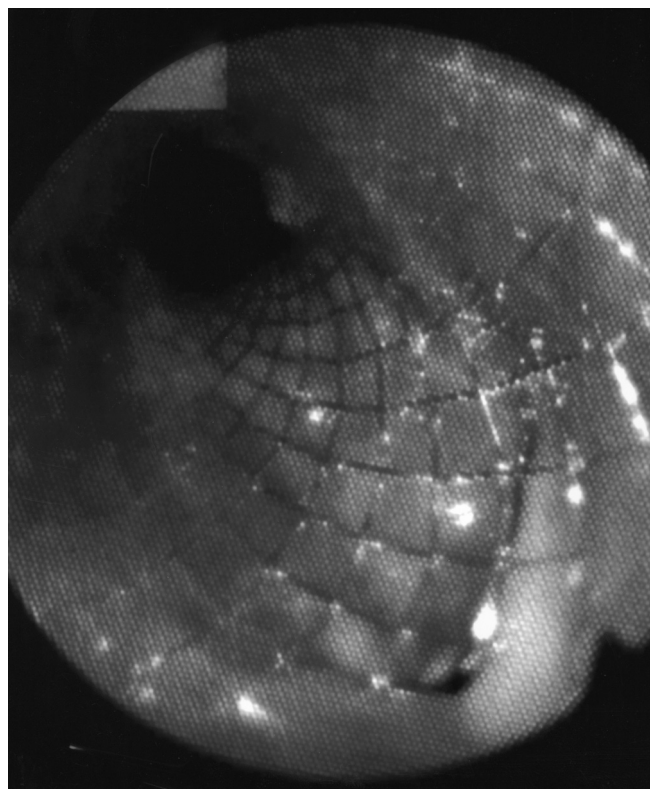
sions of a few minutes. All these methods can be applied in an ambulatory setting and are often combined for optimal effect.

The aim of the present study was to evaluate the safety and outcome of airway stent insertion, alone or in conjunction with other methods, for the treatment of malignant tracheobronchial narrowing.

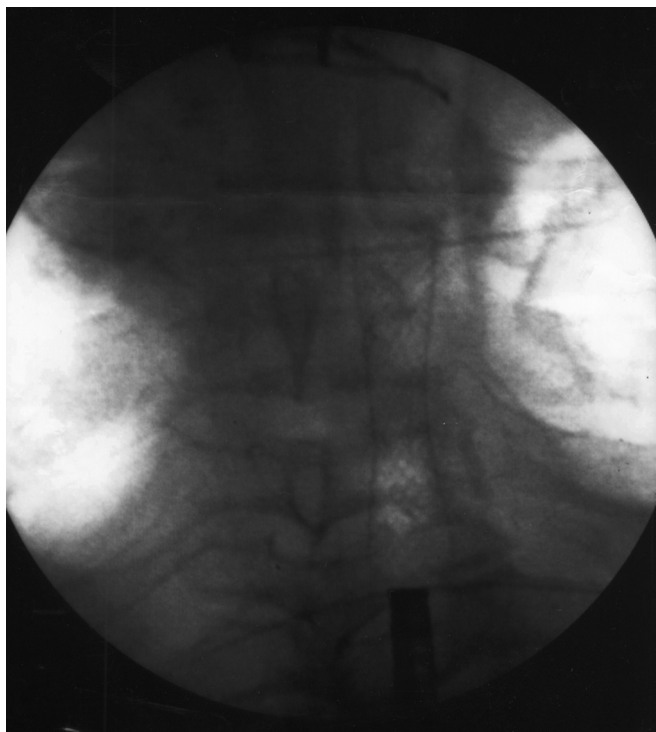
### Patients and Methods

The files of all patients with malignant pulmonary disease who underwent airway stent insertion at Rabin Medical Center from January 1995 to August 2004 were reviewed. Data were collected on patient characteristics, type of disease, symptoms, treatment, complications and outcome.

Metal Wallstents® (Boston Scientific, Natick, MA, USA) were used in all cases. We found that metal stents are easier to



**Figure 1.** Bronchoscopic view of endobronchial stent (metal Wallstent®, Boston Scientific, Natick, MA, USA)



**Figure 2.** Chest X-ray. A radiopaque marker was placed on the skin right above the target, and the stent guide containing the compressed stent was advanced through the bronchoscope until its tip lay distal to the lesion. The stent was then opened to maintain patency of the lumen.

introduce than silicone stents, do not migrate, and keep the airway patent. Stent insertions were performed with an Olympus 240 video-flexible bronchoscope (Olympus, Tokyo, Japan). The obstructed area was identified and a stent of appropriate diameter and length was selected. If necessary, the endoluminal tumor was resected by Nd:YAG laser or electrocautery. A radiopaque marker was placed on the skin right above the target, and the stent guide containing the compressed stent was advanced through the bronchoscope until its tip lay distal to the lesion. The stent was then opened to maintain patency of the lumen [Figures 1 and 2].

When high dose rate brachytherapy was deemed necessary, catheters were passed through the metal stents under direct fluoroscopic guidance and secured externally to the patient's nose. The bronchoscope was removed, and the patient was transferred to the Radiation Therapy Unit. Treatment was planned with the CadPlan BT brachytherapy system and simulation workstations (Varian Medical System, Palo Alto, CA). Radiation was delivered by Varisource high dose rate brachytherapy remote afterloader with an  $^{192}\text{Ir}$  source (10 Ci nominal activity) (Varian Medical System). A single dose of 7.5 Gy was delivered to a distance of 1 cm from the center of the source, with a margin of 1 cm from the proximal and distal ends of the stent. Follow-up consisted of repeated bronchoscopies at 3 month intervals.

## Results

The study group included 34 patients in whom a total of 37 stents were used: two patients needed two stents at different locations, and one needed two adjacent stents. Patient age ranged from 36 to 85 years (median 68). Thirty-five percent of the patients had primary lung cancer and 65% had metastatic disease. Four patients were receiving mechanical ventilation before the procedure. Lesion sites were as follows: left mainstem bronchus (31%), trachea (26%), right mainstem bronchus (26%), subglottis (14%), and bronchus intermedius (3%). Conscious sedation alone was utilized in 73% of the patients, allowing for their discharge from the ambulatory day-care unit within a few hours of the procedure. In 18 patients (53%), brachytherapy was delivered to the affected area several days after stent insertion.

Complications occurred in three patients: stent migration in one, severe bleeding requiring transfusion of two units of packed cells in one, and minimal bleeding in one. Both patients with bleeding had also received laser treatment on the day of stent insertion. The dyspnea was substantially relieved in the vast majority of patients (94%). Three of the four patients who had been intubated were weaned from the ventilator following stent insertion.

During follow-up, recurrent stenoses and obstructions were identified bronchoscopically and were treated by laser resection. All patients underwent at least one bronchoscopy for follow-up and maintenance, except for three who died before such intervention was indicated. All but one needed a recurrent laser procedure because of the appearance of mild granulation.

Complete stent obstruction was detected in three patients at 2, 5 and 40 months after treatment; one stent was obstructed twice. None of these had undergone primary brachytherapy, thus treatment consisted of laser resection and endoluminal irradiation.

Since most of the patients in the study had end-stage metastatic disease, the most important outcome parameter was the subjective response. The vast majority of patients (94%) experienced substantial relief of their dyspnea. In addition, six patients (18%) had pulmonary function both before and after stent insertion, and all showed an improvement in forced expiratory volume in 1 second (5–35%) and forced vital capacity (5–15%). Median survival from the date of stent placement was 6 months (range 0.25–105 months).

## Discussion

This study indicates that stent placement successfully reduces respiratory distress in patients with pulmonary tumors, thereby improving quality of life. The procedure can be safely performed in an outpatient setting with conscious sedation alone, sparing patients the inconvenience of hospitalization and reducing healthcare costs. Most of the patients were discharged home on the same day of the procedure, with no complications.

With regard to the palliative effect and complications of the procedure, our results are similar to those reported in other studies [7-9]. There was only one case of stent migration in our series. We used self-expanding wire mesh stents to decrease

the risk of migration and added endoluminal brachytherapy to reduce the risk of granulation tissue formation above and below the mesh stents, or neoplastic infiltration through the mesh into the lumen [10]. The rationale was based on studies showing endoluminal brachytherapy to be effective in reducing stent occlusion in coronary vessels [11-14]. Its mechanism of action may involve inhibition of fibroblast-mediated collagen gel retraction, myofibroblast recruitment, and cytokine cascades [15,16]. However, there are few reports on the use of endobronchial radiation to down-regulate the wound-healing process and prevent granulation tissue formation in stents in patients with pulmonary disease [17,18], and randomized studies with larger samples are required to validate its effect. In the present study, over 50% of the patients received brachytherapy, most of them following stent placement. Our policy today is to follow the stent procedure with two doses of brachytherapy radiation as soon as possible, sometimes even on the same day.

Although the median survival from the time of stent insertion in our series was 6 months, the individual range was very wide, with some patients surviving up to 8 years. Santos et al. [19] retrospectively compared the effect of a single palliative endobronchial modality versus a combination of modalities in patients with primary lung disease. They found that the longest survival was associated with the use of laser treatment, stents and brachytherapy. Whether stent insertion contributes only to symptom relief or has an impact on patient survival as well needs to be further investigated.

## References

- Cavaliere S, Venuta F, Foccoli P, Toninelli C, La Face B. Endoscopic treatment of malignant airway obstructions in 2008 patients. *Chest* 1996;6:1536-42.
- Chao KSC, Perez CA, Brady LW. Radiation Oncology: Management Decisions. Philadelphia: Lippincott-Raven, 1999:79.
- Raben A, Mychalczak B. Brachytherapy for non-small cell lung cancer and selected neoplasms of the chest. *Chest* 1997;112:276S.
- Mehta M, Shahabi S, Jarjour N, Steinmetz M, Kubsad S. Effect of endobronchial radiation therapy on malignant bronchial obstruction. *Chest* 1990;97:662-5.
- Rubin P, Williams JP, Riggs PN, et al. Cellular and molecular mechanisms of radiation. *Int J Radiat Oncol Biol Phys* 1998;40:929-41.
- Yarmolovsky A, Katz A, Fenig E, et al. High dose endobronchial brachytherapy for malignant airway obstruction: first study of 30 patients. *Harefuah* 2000;138:429-31 (Hebrew).
- Waples JM, Harrison R, Heffelfinger B, Cohen E. Endobronchial treatment of airway obstruction in the outpatient community setting. *Proc Am Soc Clin Oncol* 2003;22:697 (Abstract 2805).
- Wood DE, Liu YH, Vallieres E, Karmy-Jones R, Mulligan MS. Airway stenting for malignant and benign tracheobronchial stenosis. *Ann Thorac Surg* 2003;76:167-72.
- Miyazawa T, Miyazu Y, Iwamoto Y, et al. Stenting at the flow-limiting segment in tracheobronchial stenosis due to lung cancer. *Am J Respir Crit Care Med* 2004;169:1096-102.
- Madden BP, Park JE, Sheth A. Medium-term follow-up after deployment of Ultraflex expandable metallic stents to manage endobronchial pathology. *Ann Thorac Surg* 2004;78:1898-902.
- Wiedermann JG, Marboe C, Amols H, Schwartz A, Weinberger J. Intra-coronary irradiation markedly reduces neointimal proliferation after balloon angioplasty in swine: persistent benefit at 6-month follow-up. *J Am Coll Cardiol* 1995;25:1451-6.
- Crocker I. Radiation therapy to prevent coronary artery restenosis. *Semin Radiat Oncol* 1999;9:134-43.
- Teirstein PS, Massullo V, Jani S, Tripuraneni P. Radiation therapy to inhibit restenosis: early clinical results. *Mt Sinai J Med* 2001;68:192-6.
- Krotz F, Sohn HY, Klauss V, Schiele TM. Intra-coronary brachytherapy - clinical state and pathophysiological considerations. *Curr Pharm* 2005;11:421-33.
- Rubin P, Soni A, Williams JP. The molecular and cellular biologic basis for the radiation treatment of benign proliferative diseases. *Semin Radiat Oncol* 1999;9:203-14.
- Carnevali S, Mio T, Adachi Y, et al. Gamma radiation inhibits fibroblast-mediated collagen gel retraction. *Tissue Cells* 2003;35:459-69.
- Kennedy AS, Sonett JR, Orens JB, King K. High dose rate brachytherapy to prevent recurrent benign hyperplasia in lung transplant bronchi: theoretical and clinical considerations. *J Heart Lung Transplant* 2000;19:155-9.
- Brenner B, Kramer MR, Katz A, et al. High dose rate brachytherapy for nonmalignant airway obstruction. New treatment option. *Chest* 2003;4:1605-9.
- Santos RS, Raftopoulos Y, Keenan RJ, Halal A, Maley RH, Landreneau RJ. Bronchoscopic palliation of primary lung cancer: single or multimodality therapy? *Surg Endosc* 2004;18:931-6.

**Correspondence:** Dr. M.R. Kramer, Pulmonary Institute, Rabin Medical Center (Beilinson Campus), Petah Tiqva 49100, Israel.  
Phone: (972-3) 937-7221  
Fax: (972-3) 924-2091  
email: kramerm@netvision.net.il