A T Drain Approach to Anastomotic Leaks: Another Important Tool in the General Surgeon's Armamentarium

Yaron Rudnicki MD, Ian White MD, Barak Benjamin MD, Lauren Lahav MD, Baruch Shpitz MD and Shmuel Avital MD

Department of Surgery B, Meir Medical Center, affiliated with Sackler Faculty of Medicine, Tel Aviv University, Tel Aviv, Israel

ABSTRACT **Background:** Following an intestinal anastomotic leak, stoma creation may be the safest approach. However, this method may be challenging and cause significant morbidity. In selected cases, a T drain approach can be beneficial and a stoma can be avoided.

Objectives: To present one group's experience with a T drain approach for anastomotic leaks.

Methods: Data on patients who underwent emergent re-laparotomy following gastrointestinal anastomotic leaks were retrieved retrospectively and assessed with a new intra-operative leak severity score.

Results: Of 1684 gastrointestinal surgeries performed from 2014 to 2018, 41 (2.4%) cases of anastomotic leaks were taken for re-laparotomy. Cases included different sites and etiologies. Twelve patients were treated with a T-tube drain inserted through the leak site, 18 had a stoma taken out, 6 re-anastomosis, 4 were treated with an endosponge, and one primary repair with a proximal ileostomy was conducted. T drain approach was successful in 11 of 12 patients (92%) with full recovery. The condition of one patient did not improve and the patient underwent reoperation with resection and re-anastomosis. A severity score of anastomotic integrity is provided to help surgeons in decision making.

Conclusions: A T drain approach can be an optimal solution in selected cases following an intestinal anastomotic leak. When the leak is limited, the remaining anastomosis is intact and the abdominal environment allows it, a T drain can be used and a stoma can be avoided.

IMAJ 2020; 22: 435–440

KEY WORDS: anastomotic leak, Crohn's disease, leak severity score, postoperative complications, T tube drain

A leaking Intestinal anastomosis following abdominal surgery may have a devastating effect on patient well-being. Following intestinal resection and anastomosis, 0.5–21% of anastomoses are bound to leak. A clinically significant leak of small or large bowel will manifest in 1–12 % of patients, with mortality rates ranging from 3% to 22% [1-6]. Patients with Crohn's disease are especially prone to anastomotic leaks and intra-abdominal sepsis than patients with other intestinal diseases [7].

The safest and most common surgical strategy for a septic patient with a leaking anastomosis during re-laparotomy is to resect the leaking anastomosis and take out a stoma of some sort. In an effort to save the compromised anastomosis, a proximal diverting loop ileostomy can be fashioned with a primary repair of the leak site or repeat of the anastomosis [8-10]. Choosing to take out an enterostomy in a recently operated, leaking, septic environment might prove to be very challenging, with severe adhesions, a short mesentery or a thick abdominal wall restricting the elevation of the bowel through the abdominal wall [10]. In some cases creating a stoma might lead to adverse consequences, such as a very proximal stoma with its morbidity, fear of losing bowel length in Crohn's disease patients, or when the burden of a prolonged operation is too much for the patient to endure. Following a stoma creation, 64% of patients will develop at least one complication during the index hospitalization or will be readmitted mainly due to dehydration with a high output ileostomy. One out of four stomas will never be reversed and of the ones that will, almost 10% will require a midline laparotomy [11].

In selected cases of gastrointestinal anastomotic leaks a different approach can be taken by inserting a T drain tube through the leaking site, creating a temporary controlled fistula, and avoiding the need for a stoma. In this study we present our experience with an array of gastrointestinal anastomotic leaks that necessitated re-laparotomy, and the surgical approaches taken to treat them, with an emphasis on the T drain approach. In the first few cases the decision to use a T drain approach was made following difficulty applying the traditional method of stoma exteriorization as we previously reported [6]. However, following the success of the first cases we adopted this approach as the procedure of choice when the surgical environment allowed it. A new intra-operative leak severity score (INOPLESS) is proposed to help choose a proper treatment.

PATIENTS AND METHODS

Data were retrospectively retrieved from a prospectively collected database of all patients who underwent emergent re-laparotomy for a leaking gastrointestinal anastomosis. The index surgeries were elective or emergent colorectal, small bowel

or gastric surgery, excluding bariatric operations, from January 2014 to December 2018. All patients were treated with an abdominal lavage and either with a stoma creation, a T drain insertion through the leak site, redo of the anastomosis, Endo-SPONGE® (B. Braun Medical BV, Melsungen, Germany) or primary repair with proximal diverting ileostomy.

This study was approved by the appropriate institutional research committee and was performed in accordance with the ethics standards presented in the 1964 Declaration of Helsinki and its later amendments or comparable ethics standards.

Based on our experience we created an intraoperative leak severity score (INOPLESS), which may help the surgeon to select the appropriate surgical approach based on the size of staple line disruption, bowel perfusion appearance and abdominal cavity environment [Table 1]. Data recorded included age, gender, American Society of Anesthesiologist (ASA) class, preoperative diagnosis, indication for surgery, index operation, including type of anastomosis performed, and complete medical history. Follow up data included postoperative day patients were taken back to surgery, report of the leakage site, the appearance of the anastomoses, the adjacent bowels and abdominal environment upon re laparotomy, the approach taken to treat the leak and in case of a T drain use, the drain size (mm). Following the re-laparotomy, postoperative parameters were recorded and included physical examination, inflammatory marker, imaging, need for another laparotomy, length of stay (LOS) and postoperative day the T drain was removed.

After re-laparotomy, all patients underwent a thorough inspection of the abdominal cavity and gastrointestinal tract identifying the leak site. An abdominal lavage was performed and a latex T-drain tube was inserted through the leak site and taken out transcutaneously. The side arms of the T drain can be shortened and several holes or a complete removal of the back wall of the side arms can be performed. Two abdominal drains were placed around the perforated site next to the T tube. Tubes ranged from 3 to 7 mm in diameter. After inserting the arms of the T tube to the bowels lumen, sutures were placed around the insertion site to tighten the opening [Figure 1]. The tube was removed through the abdominal wall and secured to the skin. In some cases the leaking anastomosis and adjacent bowels were approximated to the abdominal wall with interrupted absorbable sutures around the tube's insertion. However, in most cases the bowel was left in situ without elevation or approximation to the abdominal wall. For the postoperative period the T drain was kept open and connected to atmospheric pressure drain to allow for passive draining. It was closed after the patient recuperated and secretions decrease to under approximately 300 ml daily. Additional imaging was not necessary. Early enteral feeding was started as soon as it was tolerated and most patients received parenteral feeding as a bridge. The decision and timing of tube extraction was made on a clinical base, usually in an out-patient clinic setting, with no need for any radiographic imaging before or after the tube removal.

Figure 1. A photograph of the inserted arms of the T-tube into the bowel's lumen. Sutures were placed around the insertion site to tighten the opening

Table 1. Proposed INtra-OPerative LEak Severity Score (INOPLESS), based on the size of staple line disruption, bowel perfusion appearance and abdominal cavity environment

Grade	Severity	Staple line disruption	Bowel perfusion appearance	Abdominal cavity environment
A	Mild	Disruption < 1–2 cm	Normal perfusion, no sign of ischemia	Localized murky fluid around the anastomosis
B	Intermediate	Partial disruption of staple line, > 1–2 cm	Pale color bowel, normal peristalsis	Localized/diffused purulent peritonitis
C	Severe	Complete staple line disruption	Bowel ischemia	Fecal peritonitis

STATEMENT OF INFORMED CONSENT

For this retrospective study, formal consent was not required. An exemption from informed consent for this study was given by the institutional research committee as the data were retrospectively retrieved from an existing prospectively and routinely collected database. The clinical trial number is NCT03974672.

RESULTS

From January 2014 to December 2018, 1684 cases of gastro-intestinal surgery were performed in a single surgical department. There were 1308 cases of colorectal surgery, 289 cases of small bowel surgery, and 87 cases of gastric surgery (excluding bariatric operations) for different indications. Of this cohort, 130 patients underwent re-laparotomy or laparoscopy for various reasons, such as surgical site infections, eventration, bowel obstructions and more. Of the entire cohort, 41 (2.4%) patients were found to have an anastomotic leak.

All 41 patients were treated with an abdominal lavage and a bailout procedure. Eighteen patients underwent a stoma creation with or without anastomotic resection, 12 patients were treated with the T drain approach, 6 had their anastomosis resected and re-done, 4 patients with colorectal anastomosis leak were treated trans-anal with Endo-SPONGE® and one patient had a primary repair and a protecting ileostomy [Table 2]. The index operation of 19 (46%) patients was in an emergent setting. Leaks were identified in 17 (41.5%) ileocolic anastomoses, 13 (31.7%) entero-entero anastomoses, 8 (19.5%) colo-rectal anastomoses, and 3 (7.3%) gastro-entero anastomoses [Figure 2].

Table 2. Description of operative bailout techniques used on 41 (2.4%) patients diagnosed intra-operatively with a gastrointestinal anastomotic leak and T drain approach outcome

Bailout technique	n (%)
Stoma creation	18 (44%)
Ileostomy	16
Colostomy	2
T tube drain insertion through leak site	12 (29%)
Anastomotic resection and re-creation	6 (15%)
Endo-SPONGE® drain insertion	4 (10%)
Primary repair and a protecting ileostomy	1 (2%)
T drain approach outcome	
Recovered completely	11/12 (92%)
Drain taken out in the outpatient clinic	9/11
Delayed operative fistula closure	2/11
Technique failure	1/12 (8%)

STOMA CREATION GROUP

Of 18 stomas created, 11 were ileostomies due to a leaking ileocolic anastomosis, 5 proximal ileostomies were caused by a leaking entero-entero anastomosis, and 2 colostomies were created after a leaking colorectal anastomosis. Six of 18 (33%) patients treated with resection of the anastomosis and stoma creation did not survive the index hospitalization and died within a few days after surgery. Only five (28%) patients had their stoma reversed in another operation to regain continuity of the gastrointestinal tract.

T TUBE DRAIN GROUP

Twelve patients were treated with a T drain approach. A T tube drain was inserted into the anastomotic leak and taken out through the abdominal wall to create a temporary controlled fistula. Mean age of patients was 60 years (range 39–81), 83% were male, ASA score prior to surgery was 1–2 for 11 patients and 3 for one patient. The index operation in three patients was resection of malignancy (gastric, pancreatic, and colonic). Four patients had bowel resection due to Crohn's disease, and five patients had bowel resection due to small bowel obstruction. Leaking sites included eight entero-entero anastomoses, three entero-colonic, and one colorectal. Detailed information on patient background, index operation, and outcome is presented in Table 3. The diagnosis and decision for surgery was based on clinical and imaging studies. Mean time from index surgery to second surgery and T tube insertion was 9 days (range 3–30). Six patients (50%) were re-operated on while in severe sepsis or septic shock. Success rate was 92% with a full recovery in 11 patients. Success was defined by avoiding a stoma creation without taking unnecessary risks such as re-doing the anastomosis in hostile conditions and prolonging the operation.

One of the initial cases in the T drain group continued to leak and his septic condition did not improve sufficiently, thus it was considered as a failure of the technique. He was re-operated one day after the T drain insertion and underwent a re-anastomosis of a leaking roux-en-y anastomosis following a D2 distal gastrectomy for cancer.

One patient with an entero-entero anastomotic leak after a small bowel resection and anastomosis in a revision of a total abdominal procto-colectomy and ileal pouch-anal anastomosis formation, had a 3 mm T drain inserted and continued leaking around the drain and did not improve sufficiently. Two days later, the drain was replaced in another laparotomy with a 7 mm drain. Following the tube diameter replacement the patient recuperated quickly. The new 7 mm tube performed with a high output of 1000 ml/d for the first days and then decreased to approximately 150 ml/d until it was plugged at postoperative day 8.

Mean length of hospital stay was 40 days (range 14–76) and the tube was removed while the patient was hospitalized or later in an outpatient clinic setting at a mean of 46 days (range 20–90) after insertion. In one case the T drain was used

Figure 2. Flowchart of the patient cohorts included in this study, including types of anastomotic leaks and treatment

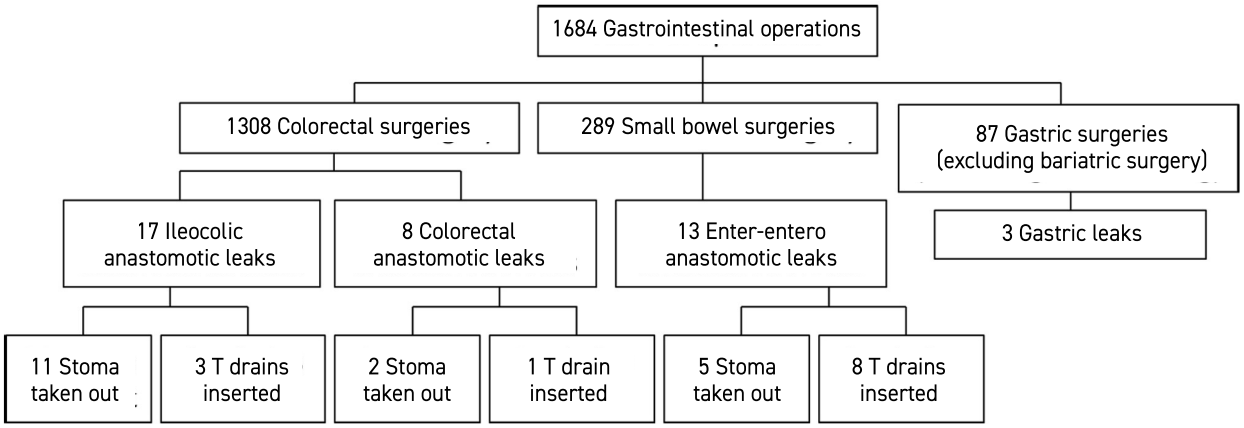

Table 3: Description of T tube drain group: Including patients' background, index operation, leak site and outcome (n = 12)

Case	Age	Gender	ASA	Etiology	Index Operation	Reoperation POD	leaking site	T drain size (mm)	Fixation to abdominal wall	LOS	POD tube removal
1	67	Male	2	Cancer	Pancreaticoduodenectomy	10	Entero-enterostomy (RNY)	4.5	Yes	45	90
2	51	Male	2	Crohn's	Small bowel resection	10	Entero-enterostomy	-	No	50	20
3	52	Male	2	Crohn's	Ileocectomy	3	Entero-colonic anastomosis	-	No	50	25
4	56	Male	2	Cancer	D2 Gastrectomy	9	Entero-enterostomy (RNY)	7	Yes	30	-
5	81	Male	2	Bowel obstruction	Small bowel resection	8	Entero-enterostomy	7	No	27	41
6	67	Male	3	Crohn's	Right colectomy	4	Entero-colonic anastomosis	6	No	34	53
7	67	Male	2	Bowel obstruction	Small bowel resection	7	Entero-enterostomy	7	Yes	77	54
8	39	Female	1	Bowel obstruction	Small bowel resection	30	Entero-enterostomy	7	No	76	61
9	74	Male	2	Hartmann	Hartmann reversal	7	Colorectal anastomosis	6	Yes	31	44
10	47	Male	1	Crohn's	Ileocectomy	4	Entero-colonic anastomosis	7	Yes	26	21
11	62	Male	1	Small bowel obstruction	Small bowel resection	11	Entero-enterostomy	4.5	Yes	14	50
12	53	Female	2	Ulcerative colitis	Proctectomy and ileal pouch-anal anastomosis	7	Entero-enterostomy	3 ⩾ 7	No	23	51

ASA = American Society of Anesthesiologist; POD = postoperative day; LOS = length of stay; RNY= Roux-en-Y anastomosis

subsequently as a feeding jejunostomy tube. Two patients recovered fully but had to undergo another operation, at a later admission, to close the controlled entero-cutaneous fistula. After exhausting the non-operative measures to close the fistula, at day 54 and 100 after the tube was inserted, the patient's fistulas were closed operatively with small bowel resection and anastomoses. The reasons the fistulas did not close can be attributed to one patient undergoing radiation enteritis after treatment for ovarian cancer and the other had a complicated wound infection around a the fistula.

DISCUSSION

Anastomotic leak is associated with high morbidity and potential mortality [12,13]. Although in most cases stoma creation is the safest solution, it is not always the easiest and it has its own inherited morbidity. In selected cases when the leak site is defined and the rest of the anastomosis is intact, the use of a T tube drain insertion to create a temporary controlled entero-cutaneous fistula can be an optimal solution. This shortens the operation, obviates the need for a stoma, and in our experience, helps control the leak in more than 90% of patients.

The basis of this technique stems from the treatment of a duodenal stump leakage. Tube duodenostomy technique is commonly used in preventing or treating a stump leak. The duodenal stump is closed over a rubber tube to create a controlled fistula and prevent bile leakage [14]. There have also been some reports of upper gastrointestinal leaks treated with creation of a controlled fistula, but no reports of using this technique in entero-colonic leaks, and no colorectal leaks in Crohn's disease patients.

We believe that the mechanism by which creating an entero-cutaneous fistula with a tube works is by plugging the hole directly with the elastic tube on one hand and lowering the intra-luminal pressure inside the bowel on the other hand. By doing so, bowel content flows through a large diameter tube with less pressure on the leaking site, allowing for wound healing. Our experience showed that the proper diameter and length of the tube are crucial for the maneuver to succeed. As seen in our last case, using a 3 mm T drain was not sufficient and bowel content kept leaking profusely around the tube. The tube was replaced with a 7 mm T drain 2 days later and the leak subsided. This, most probably, was due to a decrease in intra-luminal pressure with a partial diversion of the bowel content through a larger tube, leading to cessation of the leak and immediate improvement of the patient. As stated in Hagen–Poiseuille equation, the pressure difference between the lumen and the outside has an inverse relation with the fourth power of the radius of the tube ($\Delta P = \frac{8\mu LQ}{\pi R^4}$). The length of most T tube drains ranges from 45 to 48 cm and can be shorten for less resistance.

Regarding the technique of fashioning the T tube fistula, we found that suturing the serosal side of the bowel around the tube to the inner abdominal wall is not necessary. Moreover, trying to suture an edematous and ill bowel is not advised since it may damage the bowel wall and create unwanted tension on the lifted bowel. Thus, in recent cases we have left the bowel in situ. Intra-abdominal drains set around the inserted tube are necessary given that in the immediate days after surgery minimal leakage may persists.

As seen in our cohort, this technique is appropriate for complications of different index operations ranging from gastrointestinal tract reconstruction after gastric, small bowel or large bowel resections for benign or malignant conditions. It is especially relevant for an anastomotic leak following bowel resection in patients with Crohn's disease, when shortening another segment of bowel with a rescue stoma is of great concern.

When dealing with complicated cases, as described in this study, the range of measures to treat the leak vary from primary repair to taking out a stoma, with a T drain insertion in between. In all the cases described, the decision not to treat with a primary repair approach was made by experienced colorectal surgeons who assessed the situation as complicated and in need for bowel diversion, either by stoma or T drain. To reinforce this dogma, it is highly unorthodox to treat a bowel leak with primary repair 9 days after the index operation with peritonitis due to bowel content in the abdominal cavity. Theoretically, even in patients where primary repair is contemplated, the price of primary repair failure could be dreadful. In borderline cases when primary repair is considered we still use the T drain approach as a safety measure.

It is important to emphasize that the T drain approach should be used selectively when there is a defined leakage site, no evidence of bowel ischemia, and the rest of anastomosis and adjacent bowel are intact. We believe that the degree of septicemia or septic shock had little influence on the decision to insert the T tube. In cases with bowel leak or perforation with no surrounding ischemia, we now employ the T drain approach.

Most studies on anastomotic leaks refer to all leaks as if they are the same and the differences are with the type of anastomosis and the level of septicemia of the patient, and thus the treatment of choice is accordingly [15]. However, nothing can really replace the surgeon's experience and intra-operative assessment of severity of the leak regarding the bowel condition and abdominal environment. We suggest that an attempt to standardize this severity might help surgeons in making intra-operative decision.

Our proposed leak severity score [Table 1] is based on three parameters: size of staple line disruption (or suture line), bowel perfusion appearance, and abdominal cavity environment. We believe that grade A leaks may be treated with relative safety with a T drain approach, a primary repair of the disruption, and nearby drains or a redo of the anastomosis. Grade C leaks should be treated with a resection of the damaged bowel and stoma formation. The choice of treatment for a grade B leak is challenging and the surgeon's experience and clinical judgment would play a major role.

LIMITATIONS

The pitfalls and drawbacks of this study centered on it being a retrospective study with a small cohort, single center experience, and mixed types of gastrointestinal anastomoses that may cloud our conclusions. However, we believe that the heterogeneity of cases strengthen the efficacy of the technique and might suggest that they can be used in a variety of non-textbook cases of upper and lower gastrointestinal leaks.

CONCLUSIONS

The purpose of this study was to report different solutions for treating intestinal leaks with an emphasis on the T drain approach as a safe and beneficial approach in selected cases. We believe that this approach, guided by our suggested leak severity score, should be considered as another tool in the armamentarium of the general and colorectal surgeon. Future clinical studies are needed to confirm the safety of the T drain approach and to validate our proposed intra-operative leak severity score.

Correspondence

Dr. Y. Rudnicki
Dept. of Surgery B, Meir Medical Center, Kfar Saba, 4428164, Israel
Fax: (972-9) 747-1305
email: yaron217@gmail.com

References

1. Blumetti J, Chaudhry V, Cintron JR, et al. Management of anastomotic leak: lessons learned from a large colon and rectal surgery training program. *World J Surg* 2014; 38 (4): 985-91.
2. Damen N, Spilsbury K, Levitt M, et al. Anastomotic leaks in colorectal surgery. *ANZ J Surg* 2014; 84 (10): 763-8.
3. Felder SI, Barmparas G, Murrell Z, Fleshner P. Risk factors for failure of percutaneous drainage and need for reoperation following symptomatic gastrointestinal anastomotic leak. *Am J Surg* 2014; 208 (1): 58-64.
4. Hyman N, Manchester TL, Osler T, Burns B, Cataldo PA. Anastomotic leaks after intestinal anastomosis: it's later than you think. *Ann Surg* 2007; 245 (2): 254-8.
5. Krarup PM, Jorgensen LN, Harling H; Danish Colorectal Cancer Group. Management of anastomotic leakage in a nationwide cohort of colonic cancer patients. *J Am Coll Surg* 2014; 218 (5): 940-9.
6. Rudnicki Y, Shpitz B, White I, Wiener Y, Golani G, Avital S. The use of a T drain tube to treat anastomotic leaks. *Tech Coloproctol* 2016; 20 (4): 255-7.
7. amamoto T, Spinelli A, Suzuki Y, et al. Risk factors for complications after ileocolonic resection for Crohn's disease with a major focus on the impact of preoperative immunosuppressive and biologic therapy: a retrospective international multicentre study. *United European Gastroenterol J* 2016; 4 (6): 784-93.
8. Blumetti J, Abcarian H. Management of low colorectal anastomotic leak: Preserving the anastomosis. *World J Gastrointest Surg* 2015; 7 (12): 378-83.
9. Byrn JC, Schlager A, Divino CM, Weber KJ, Baril DT, Aufses AH Jr. The management of 38 anastomotic leaks after 1,684 intestinal resections. *Dis Colon Rectum* 2006; 49 (9): 1346-53.
10. Hedrick TL, Sawyer RG, Foley EF, Friel CM. Anastomotic leak and the loop ileostomy: friend or foe?. *Dis Colon Rectum* 2006; 49 (8): 1167-76.
11. Chun LJ, Haigh PI, Tam MS, Abbas MA. Defunctioning loop ileostomy for pelvic anastomoses: predictors of morbidity and nonclosure. *Dis Colon Rectum* 2012; 55 (2): 167-74.
12. McArdle CS, McMillan DC, Hole DJ. Impact of anastomotic leakage on long-term survival of patients undergoing curative resection for colorectal cancer. *Br J Surg* 2005; 92 (9): 1150-4.
13. Walker KG, Bell SW, Rickard MJ, et al. Anastomotic leakage is predictive of diminished survival after potentially curative resection for colorectal cancer. *Ann Surg* 2004; 240 (2): 255-9.
14. Isik B, Yilmaz S, Kirimlioglu V, Sogutlu G, Yilmaz M, Katz D. A life-saving but inadequately discussed procedure: tube duodenostomy. Known and unknown aspects. *World J Surg* 2007; 31 (8): 1616-26.
15. Goshen-Gottstein E, Shapiro R, Shwartz C, et al. Incidence and risk factors for anastomotic leakage in colorectal surgery: a historical cohort study. *IMAJ* 2019; 21 (11): 732-7.

Capsule

Rapid reconstruction of SARS-CoV-2 using a synthetic genomics platform

Reverse genetics has been an indispensable tool revolutionizing insights into viral pathogenesis and vaccine development. Large RNA virus genomes, such as from Coronaviruses, are cumbersome to clone and manipulate in *E. coli* due to size and occasional instability. Therefore, an alternative rapid and robust reverse genetics platform for RNA viruses would benefit the research community. **Thao** et al. showed the full functionality of a yeast-based synthetic genomics platform to genetically reconstruct diverse RNA viruses, including members of the *Coronaviridae*, *Flaviviridae* and *Paramyxoviridae* families. Viral subgenomic fragments were generated using viral isolates, cloned viral DNA, clinical samples, or synthetic DNA, and reassembled in one step in *Saccharomyces cerevisiae* using transformation associated recombination (TAR) cloning to maintain the genome as a yeast artificial chromosome (YAC). T7-RNA polymerase has been used to generate infectious RNA to rescue viable virus. Based on this platform the authors have been able to engineer and resurrect chemically-synthetized clones of the recent epidemic SARS-CoV-2 in only a week after receipt of the synthetic DNA fragments. The technical advance the authors describe here allows a rapidly response to emerging viruses as it enables the generation and functional characterization of evolving RNA virus variants, in real-time, during an outbreak.

Nature 2020; 10.1038/s41586-020-2294-9

Eitan Israeli