

Cardiac Murmur Detected by the Patient or a Person Nearby: An Auditory Finding Indicating the Need for Surgical Intervention

Yoav Turgeman MD, Lev Bloch MD, Alexander Feldman MD and Tiberio Rosenfeld MD

Department of Cardiology, HaEmek Medical Center, Afula, Israel

Key words: musical murmur, aortic regurgitation, rupture sinus of Valsalva

IMAJ 2006;8:357-358

Cardiac murmur is defined as an auditory vibration that is more prolonged than heart sounds and is characterized by intensity (loudness), frequency (pitch), configuration (shape), as well as the quality, duration and direction of radiation, and timing related to the cardiac cycle [1]. In daily practice these auscultatory findings can be detected either by stethoscope or documented by echocardiographic Doppler flow signals.

Based on S. Levine's classification, a grade 1/6 murmur is so faint that it is hardly heard even with special efforts, whereas a grade 6/6 murmur is loud enough to be heard with the stethoscope just removed from the chest [2]. Cardiac murmurs detected by the human ear alone without the use of a stethoscope are very rare. The clinical conclusions that can be based on such auditory findings have not been well defined.

We describe two patients who presented with sudden shortness of breath

associated with "sounds" originating from the chest that were detected either by themselves or by their close family members. In these cases urgent cardiac surgery was indicated.

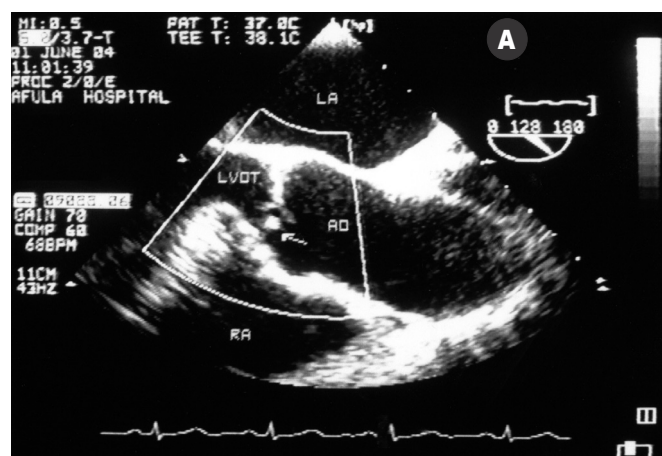
Patient Descriptions

Patient 1

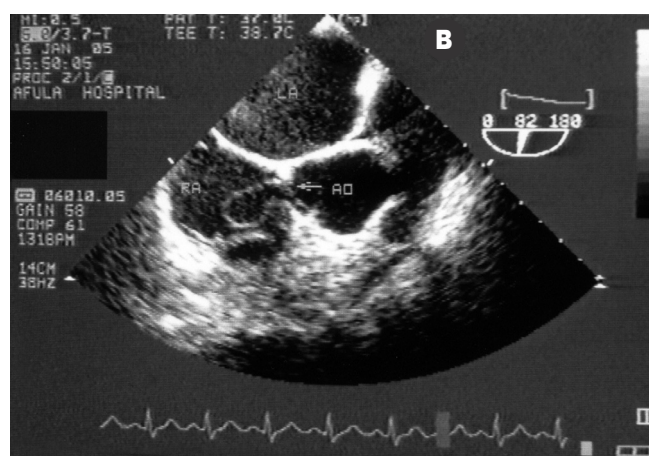
A 68 year old previously healthy man complained of shortness of breath during routine daily activity. For several nights before seeking medical aid, his wife noticed "musical sounds" coming from his chest. He reported no history of anginal pain, febrile illness or chest trauma.

Physical examination revealed a body temperature of 36.5°C, bounding arterial pulses, blood pressure of 130/70 mmHg and a regular heart rate of 96 beats/minute. Cardiac palpation indicated a hyperdynamic left ventricle in the absence of cardiomegaly. When turning the patient onto the left lateral position, a musical sound originating from his chest was no-

ticed without the use of a stethoscope. Cardiac auscultation revealed a faint first heart sound, apical S3, a left parasternal short 2/6 systolic murmur and a 6/6 early musical diastolic murmur followed by a relatively short diastolic decrescendo component. Trans-thoracic two-dimensional echocardiography showed preserved left ventricular size and function associated with both systolic and diastolic fluttering of the right coronary aortic cusp. Color Doppler study demonstrated significant aortic regurgitation. Trans-esophageal echocardiography revealed tearing of the free edge of the right coronary aortic cusp, resulting in miscoaptation between aortic leaflets [Figure A]. Macroscopic evaluation of the diseased valve during surgery indicated thin and very delicate cusps on three leaflet aortic valves, with tearing of the edge of the right coronary cusp. Microscopic examination failed to show any inflammatory cellular components. After establishing a normal



[A] Trans-esophageal echocardiography revealed tearing of the free edge of the right coronary aortic cusp (arrow) causing severe aortic regurgitation. AO = aorta, LA = left atrium, LVOT = left ventricular outflow tract, RA = right atrium.



[B] Trans-esophageal echocardiography showing aneurysmatic dilatation of the non-coronary sinus of Valsalva ruptured (arrow) into the right atrium.

coronary angiogram, a successful aortic valve replacement using a 25 mm Mosaic Biological valve was undertaken.

Patient 2

A 20 year old previously asymptomatic male was admitted with pulmonary edema. Two days before admission he began complaining of shortness of breath after repeated episodes of chest pain. At night, he noticed the sudden appearance of cyclic musical sounds originating from his chest.

Physical examination revealed a young, restless, dyspneic male, with 24 breaths/min, body temperature 37°C, collapsing arterial pulses, regular heart rate of 110 beats/min and blood pressure 130/60 mmHg. Both internal jugular veins were engorged, and coarse rales were detected over two-thirds of the lungs. Cardiac palpation revealed right ventricular uplift, and a continuous murmur with a musical diastolic component over the right parasternal area was detected by auscultation. Trans-thoracic echocardiography showed normal left ventricular size and function in the absence of valvular structural abnormalities. Doppler echocardiography demonstrated aortic regurgitation in the presence of a significant aortic to right atrial shunt. Trans-esophageal color study established a diagnosis of rupture of the sinus of Valsalva into the right atrium [Figure B]. The surgical report confirmed this diagnosis. In the absence of aortic

regurgitation, this defect was successfully repaired by a Teflon patch through a right atrial approach.

Comment

Different structures can be involved in chest-originated sounds. However, periodic noisy auscultatory findings are generally attributed either to respiratory or cardiovascular systems. Multiple causes have been proposed for the origin of cardiac murmurs: vibration of cardiac structures, turbulence, cavitation, and periodic wake fluctuation [3].

Musical murmurs are characterized by pure tone, high intensity and periodicity that may be detected in normal subjects but more often is found in various heart pathologies. The audiofrequency of these murmurs is dependent on the period of vibration of the abnormal structure involved [4]. These murmurs may be detected at different phases of the cardiac cycle, and can be transient in nature and innocent when they appear during the systole [5]. However, diastolic musical murmurs are generally associated with cardiac structural abnormalities. Using phonocardiography, these murmurs have been designated as honk, whoop, seagull cry, cooing, etc. Our cases demonstrated that musical murmurs can be extremely loud, and may be audible to the patient as well as to a person nearby. These auditory findings most probably originate from vibrations of abnormal cardiac

structures: torn leaflet and flap of aortic sinus exposed to a high blood velocity jets. The sudden appearance of symptoms associated with these auditory findings should alert the physician to the importance of early medical evaluation due to the possible need for urgent surgical intervention.

References

1. Perloff JK, Braunwald E. Physical examination of the heart and circulation. In: Braunwald E, ed. *Heart Disease. A Textbook of Cardiovascular Medicine*. 5th edn. Philadelphia: WB Saunders, 1997:15–52.
2. Freeman AR, Levine SA. The clinical significance of the systolic murmur. A study of 1000 consecutive “non-cardiac” cases. *Ann Intern Med* 1933 ;6:1371–4.
3. Rushmer RF, Morgan C. Meaning of murmurs. *Am J Cardiol* 1968;21:722–30.
4. Alan M, Garcia R, Goldstein S. Echophonocardiographic feature of regurgitant porcine mitral and tricuspid valves presented with musical murmurs. *Am Heart J* 1983;105:450–6.
5. Barlow JB, Pocock WA. Mitral leaflet billowing and prolapse. In Barlow JB, ed. *Perspectives on the Mitral Valve*. FA Davis Company, 1987:49–112.

Correspondence: Dr. Y. Turgeman, Director of Invasive Cardiology, Dept. of Cardiology, HaEmek Medical Center, Afula 18101, Israel.

Phone: (972-4) 649-4016

Fax: (972-4) 649-4387

email: yoav_t@clalit.org.il