IMAJ • VOL 22 • SEPTEMBER 2020

Midline Approach for Surgical Stabilization of High Anterior Chest Wall Fractures

Ory Wiesel MD[1], Heath Walden MD[2], Alexa Nasti FNP[1] and Krishan Patel MD[2]

Department of Surgery, Divisions of [1]Thoracic Surgery and [2]Trauma and Critical Care, Maimonides Medical Center, Brooklyn, NY, USA

KEY WORDS: chest wall stabilization, rib fractures, surgical stabilizing rib fractures systems (SSRF)

IMAJ 2020; 22: 518–520

High anterior rib fractures are often associated with significant morbidity. The choice of fixing such fractures is not always straight forward, and when indicated, the common approaches for surgical stabilization are often associated with significant tissue injury and limited exposure. A case of surgical stabilization of anterior fractures via midline exposure is presented demonstrating its superiority over conventional approaches.

Rib fractures are among the most common injuries associated with blunt chest trauma. Despite many advancements in the care of rib fractures, outcomes remain poor and have not changed substantially over the years.

With advanced technology, surgical stabilizing rib fractures (SSRF) systems are being utilized more frequently. Still, fewer than 1% of patients with flail chest undergo surgical stabilization, mainly due to the lack of familiarity with SSRF systems, lack of evidence-based data on long-term effectiveness, and in some centers, the lack of ownership among multiple teams involved in the care of patients with complex rib fractures [1].

Based on international guidelines, SSRF should be considered for all patients with flail chest or patients with multiple, severe (bicortical) displaced fractures. Patients with intractable refractory pain or respiratory compromise might benefit from SSRF as well [1,2].

Anterior rib fractures, especially high fractures and those involving the costal cartilage, represent a unique challenge. Although not affecting the breathing mechanics much, these fractures are painful, and might cause displacement, with difficulties approaching them through common surgical approaches.

We describe a case of severe displacement of second and third ribs and cartilage. SSRF were fixed to the sternum following midline exposure raising pectoral flaps.

To the best of our knowledge, this is the first description utilizing midline approach for stabilization of high anterior chest wall fractures.

PATIENT DESCRIPTION

A 41-years-old bicyclist presented to the emergency department after being struck by a car. On arrival he had a Glasgow Coma Scale rating of 15 and stable hemodynamics. On secondary survey he was noted to have deformity of the left clavicle with a hematoma on his anterior upper chest wall, multiple abrasions, and open wounds on the right tibia. A chest X-ray showed comminuted left clavicle fracture with multiple left rib fractures. Computed tomography was significant for severe anterior displacement of the second and third left ribs with additional non-displaced fractures of the second rib posteriorly and fourth and fifth ribs anteriorly, adjacent lung contusion, and apical pneumothorax. Left chest tube was placed, and the patient was admitted for observation. Because of his persistent pain and chest wall deformity that was affecting his breathing mechanism, we elected to proceed with surgery to obtain anterior chest wall stabilization and rib fixation.

In the operating room the patient was placed supine with shoulder roll behind his bilateral scapula. The displaced chest wall segment was identified with palpation and noted to be at the high left parasternal area as was demonstrated in the three-dimensional (3-D) image [Figure 1A]. Direct incision above the displaced segments was considered; however, although it was less likely that additional plates would be needed for the lower anterior rib fractures based on the pre-operative scans, we preferred to preserve the option to extend the incision by performing a vertical incision. A median sternotomy-like vertical skin incision was performed at the center of the sternum extending from the angle of Louis to the mid-sternum. We raised skin and a subcutaneous flap and exposed the fenestrations of the pectoralis major muscle on the sternum. We detached these fenestrations and elevated both pectoral muscles to expose the chest wall and the displaced fractures. These fractures involved complete displacement with multiple fragments of the proximal second and third ribs with disarticulation of the adjacent costochondral junction. The fourth and fifth rib fractures were not displaced with preserved costochondral junctions. Given the severe displacement, we elected to reduce the second and third ribs and approximate the displaced costochondral junction. Using the RibFix Blue© (Zimmer Biomet, USA), we placed 14-cm long plates to bridge the costochondral junction as well the displaced fractured ribs and fixed them to the cortex of the second and third ribs and the sternum using multiple locking 8-mm bicortical screws. We made sure not to drill into the cartilage. The plates were then covered with the pectoral muscles, which were

Figure 1. Surgical stabilizing rib fractures system use to treat high anterior rib fracture

[A] Three-dimensional image demonstrating fractures of the left second and third ribs, left clavicle, **[B]** postoperative radiograph demonstrating anteriorly placed plates with proper alignment of the second and third ribs, **[C]** intra-operative image demonstrating the excellent exposure, **[D]** schematic illustration of anterior rib plating, the pectoral muscles flap are retracted laterally

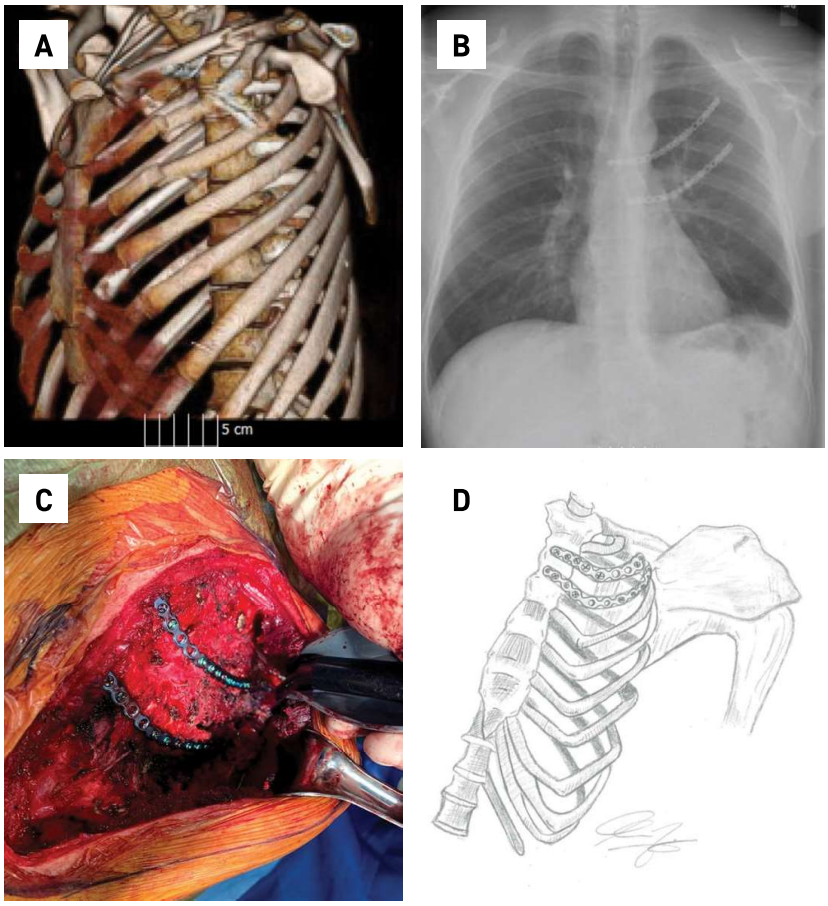

sutured to the chest wall and the sternum medially. The rest of the chest wall was closed in layers with special emphasis to eliminated possible seroma filling spaces. Postoperative chest X-ray showed well reduced ribs [Figure 1B]. The patient did well and was discharged on postoperative day 5. He was seen one month later in the clinic doing well with a healed incision and appropriate expansion of his chest wall.

COMMENT

Thoracic trauma is the main source for morbidity and mortality in trauma patients. Rib fractures are the most common thoracic trauma with more than 350,000 newly diagnosed fractures in the United States in 2017, which accounted for up to 10% of trauma hospitalizations [3]. Historically, rib fractures and chest wall instability have been managed conservatively with analgesia, oxygen supplementation, and pulmonary toilet. Surgical stabilization of rib fractures has not been historically in the toolbox of the trauma and thoracic surgeons; however, with the development of rib fixation technology, SSRF for severe rib fracture is becoming an accepted modality. Randomized controlled trials and cohort studies showed that patients undergoing SSRF for flail chest have decreased pain, shorter duration of mechanical ventilation, decreased incidence of pneumonia, and shorter stay in the intensive care unit [4]. Improved outcomes were also reported in patients with three or more severely displaced non-flail chest fractures or in patients with fewer than three displaced fractures with intractable pain [2].

Anterior chest wall disassociation is associated with serious underlying injury. The choice of fixing high anterior ribs is not straight forward. On one hand, the first two ribs contribute minimally to respiratory mechanism and exposure via sub-mammary or anterior thoracotomy incisions is often challenging and results in significant morbidity. On the other hand, anterior fractures are quite painful and anterior flail chest may result from concomitant rib and costal cartilage fractures or bilateral rib fracture. As a result, fixing high anterior rib fractures are not being done routinely but should be considered in selected cases of severe displacement, refractory pain, vascular impingement, or fractures within 2.5 cm of the costal cartilage [1].

Our patient presented with significant blunt anterior chest wall trauma with severe displacement, including part of the costochondral junction of the most proximal part of ribs two and three with additional non-displaced fractures of other ribs. Performing a submammary incision would have necessitated the need to raise large pectoral flaps with significant tissue damage; hence, we elected to perform a vertical midsternal incision [Figure 1C]. This procedure was found to give excellent exposure to the high anterior proximal fractures. Plates can be fixed to the ribs anteriorly or to the sternum and may even bridge cartilage fractures, which are often associated with proximal anterior rib fractures [Figure 1D]. The advantage of this exposure is ease of performance, excellent exposure to the anterior chest wall, and ability to extend the incision as needed to the inframammary fold or high supraclavicular region. Avoiding direct incision over the pectoral muscles with anterior thoracotomy incision or the latissimus dorsi, and serratus anterior muscles with posterior thoracotomy incision pre-

vents the need for muscle spearing surgery or injury to neurovascular bundles that are associated with these incisions. Finally, multiple ribs can be easily fixed with this exposure.

The disadvantage of this approach is the need to extend it to anterior thoracotomy if more lateral fractures should be fixed, which might cause unnecessary tissue damage. This limitation can be overcome by meticulous planning with 3-D imaging and models or real-time intra-operative ultrasound localization prior to incision [5]. Caution should be practiced not to injure the mammary vessels or the costal cartilage with the bicortical screws.

CONCLUSION

Based on the ease of its performance and the added value for fixing high anterior rib fractures, midline exposure should be considered in selected cases where there is a need for surgical stabilization of such fractures.

ACKNOWLEDGEMENTS

The authors thank Mr. Andrew Nasti for his Illustrations.

Correspondence

Dr. O. Wiesel
Department of Surgery, Division of Thoracic Surgery, Maimonides Medical Center, Brooklyn, NY 11219, USA
Phone: (1-718) 283-7686
Fax: (1-718) 635-7421
email: orywiesel@gmail.com

References

1. Pieracci FM, Majercik S, Doben A, et al. Consensus statement: surgical stabilization of rib fractures rib fracture colloquium clinical practice guidelines. *Injury* 2017; 48 (2): 307-21.
2. Majercik S, Cannon Q, White TW, et al. Long-term patient outcomes after surgical stabilization of rib fractures. *Am J Surg* 2014; 208 (1): 88-92.
3. He Z, Zhang D, Xiao H, et al. The ideal methods for the management of rib fractures. *J Thorac Dis.* 2019; 11 (Suppl 8): S1078-S1089.
4. Marasco SF, Davies AR, Cooper J, et al. Prospective randomized controlled trial of operative rib fixation in traumatic flail chest. *J Am Coll Surg* 2013; 216 (5): 924-32.
5. Wiesel O, Jaklitsch MT, Fisichella PM. Three-dimensional printing models in surgery. *Surgery* 2016; 160 (3): 815-7.

Out of the quarrel with others we make rhetoric; out of the quarrel with ourselves we make poetry.
William Butler Yeats (1865–1939), writer, Nobel laureate

Capsule

The spread of SARS-CoV-2 in Brazil

Brazil has been hard-hit by the severe acute respiratory syndrome-2 (SARS-CoV-2) pandemic. **Candido** and colleagues combined genomic and epidemiological analyses to investigate the impact of nonpharmaceutical interventions (NPIs) in the country. By setting up a network of genomic laboratories using harmonized protocols, the researchers found a 29% positive rate for SARS-CoV-2 among collected samples. More than 100 international introductions of SARS-CoV-2 into Brazil were identified, including three clades introduced from Europe that were already well established before the implementation of NPIs and travel bans. The virus spread from urban centers to the rest of the country, along with a 25% increase in the average distance traveled by air passengers before travel bans, despite an overall drop in short-haul travel. Unfortunately, the evidence confirms that current interventions remain insufficient to keep virus transmission under control in Brazil.

Science 2020; 369: 1255

Eitan Israeli

Capsule

A decoy receptor for SARS-CoV-2

For severe acute respiratory syndrome coronavirus-2 (SARS-CoV-2) to enter human cells, the spike protein on the surface of the virus must bind to the host receptor protein, angiotensin-converting enzyme 2 (ACE2). A soluble version of the receptor is being explored as a therapeutic. **Chan** et al. used deep mutagenesis to identify ACE2 mutants that bind more tightly to the spike protein and combined mutations to further increase binding affinity. A promising variant was engineered to be a stable dimer that has a binding affinity for the spike protein; it is comparable with neutralizing antibodies and neutralized both SARS-CoV-2 and SARS-CoV-1 in a cell-based assay. In addition, the similarity to the natural receptor may limit the possibility for viral escape.

Science 2020; 369: 1261

Eitan Israeli