

## Acute Focal Nephritis: Its True Sonographic Face

Valeria Rathaus MD MSc and Myriam Werner MD

Department of Diagnostic Imaging, Meir Medical Center, Kfar Saba, Israel  
Affiliated with Sackler Faculty of Medicine, Tel Aviv University, Ramat Aviv, Israel

**Key words:** genitourinary tract, ultrasound, Doppler, renal infection, hyperechoic focal lesion

### Abstract

**Background:** Acute focal nephritis is an inflammatory process of the renal parenchyma affecting principally the cortex of the kidney. It is considered a midpoint in the spectrum of upper urinary tract infections, ranging from uncomplicated pyelonephritis to intrarenal abscesses. Until recently the hyperechoic sonographic appearance of this lesion was considered uncommon.

**Objectives:** To determine the relative prevalence of hyperechoic and hypoechoic sonographic appearance of focal renal lesions in patients with the clinical diagnosis of acute pyelonephritis and to correlate the findings with those of the color Doppler examinations.

**Methods:** We reviewed the sonograms of 367 patients hospitalized with the clinical diagnosis of acute pyelonephritis. The sonograms were reviewed for acute renal inflammatory changes. When a focal lesion was detected, we noted the echogenicity, side, form, location and color Doppler characteristics.

**Results:** Abnormal sonographic findings related to the infection were found in 78 cases. In 52 patients a focal lesion was diagnosed. Forty-seven focal lesions appeared hyperechoic related to the adjacent parenchyma. These lesions were more frequently located at the upper pole and were wedge-shaped in most of the cases. The areas appeared hypo/avascular on the color Doppler examination.

**Conclusions:** Our data suggest that the most common appearance of acute focal nephritis is an area of increased echogenicity in the parenchyma of the affected kidney.

*IMAJ 2007;9:729-731*

Acute focal nephritis is an inflammatory process of the renal parenchyma affecting principally the cortex of the kidney [1,2]. Focal areas of decreased echogenicity are described in the literature as representing the typical sonographic appearance of AFN [2,3]. Few reports have described AFN as a hyperechoic mass [2-5] and it is considered an unusual finding [4,5]. Recently, however, Farmer et al. [6] claimed that the hyperechoic appearance may in fact represent the more common form of AFN.

We reviewed the records of all patients admitted to our hospital with the clinical diagnosis of acute pyelonephritis, differentiating those patients who underwent a renal sonographic examination, and report here the prevalence of the various appearances of the sonographic findings consistent with a focal lesion.

### Patients and Methods

We reviewed the medical records of patients documented with acute pyelonephritis at Meir Hospital, Kfar Saba, Israel, between

the years 1997 and 2004. Only patients who had undergone renal ultrasonography within 24-48 hours from their admission were included in the study.

The renal sonogram was performed by qualified experienced sonographers and recorded as standard images on films. The equipment used was an Acuson XP10 128 or an HID 5000 sonoCT ATL using a 3.5 or 5 MHz transducer, depending on the patient's age and body habitus. Color Doppler flow examination was performed and recorded. The sonograms were reviewed by two senior radiologists qualified in ultrasonography (V.R and M.W.). When a focal lesion was detected, the following characteristics were also studied: a) the echogenicity of the lesion related to the adjacent renal parenchyma and its contour, b) the size of the lesion, c) the form of the lesion (wedge or mass type), d) the appearance of the corticomedullary junction, and e) the color/power Doppler characteristics.

Altogether, 629 patients were hospitalized with the diagnosis of acute pyelonephritis between the years 1997 and 2004. Of these, 367 patients (58.3%) had an ultrasound examination during the first 2 days of hospitalization. These patients comprised 47 males and 320 females, ranging in age from 1 month to 93 years (mean SD 33.1 ± 21.4). All patients presented with fever and pyuria (> 5 white blood cells/high power field). Urine cultures were positive in 286 cases (77.9%), the common pathogens being *Escherichia coli* (56%), *Pseudomonas aeruginosa* (20.6%) and *Klebsiella* spp. (13.8%). In 81 patients, urine cultures were negative.

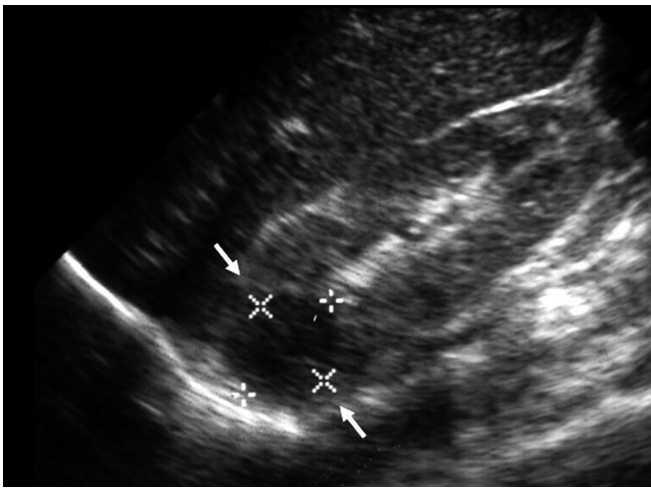
### Results

Of the 367 who underwent ultrasound examination 78 showed abnormalities related to an acute renal infection. Abnormal findings included focal lesion, perinephric fluid, enlarged kidneys and increased cortical echogenicity. A focal lesion was the most frequent abnormality and was diagnosed in 52 of the 367 patients who underwent renal sonography. In only five cases of focal lesions was the appearance that of a hypoechoic area [Figure 1]. These hypoechoic lesions were in the right kidneys in three cases and on the left side in two. They were located in the upper pole in four patients, and in the middle region in one. All the hypoechoic lesions had a "mass-like" shape. Their size ranged from 1.5 to 3 cm and their contour appeared quite defined. In these kidneys, the CMJ was blurred.

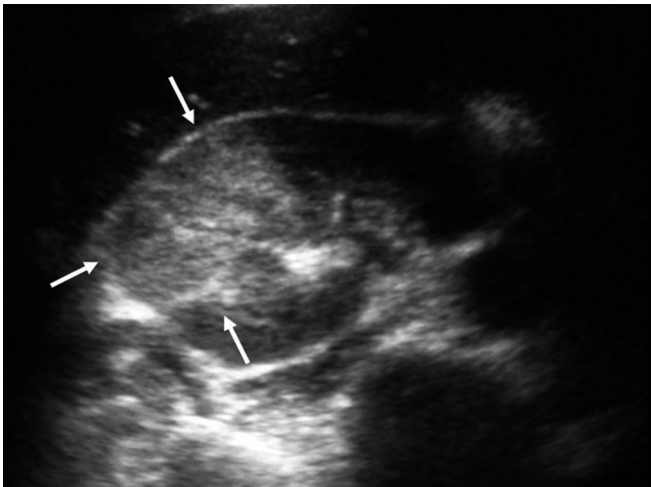
In 47 patients we observed a hyperechoic region as compared

AFN = acute focal nephritis

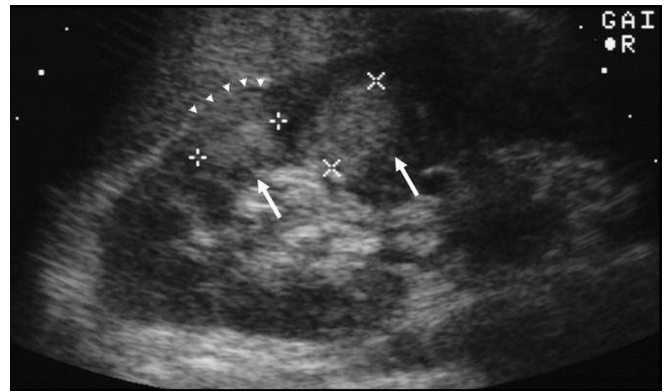CMJ = corticomedullary junction



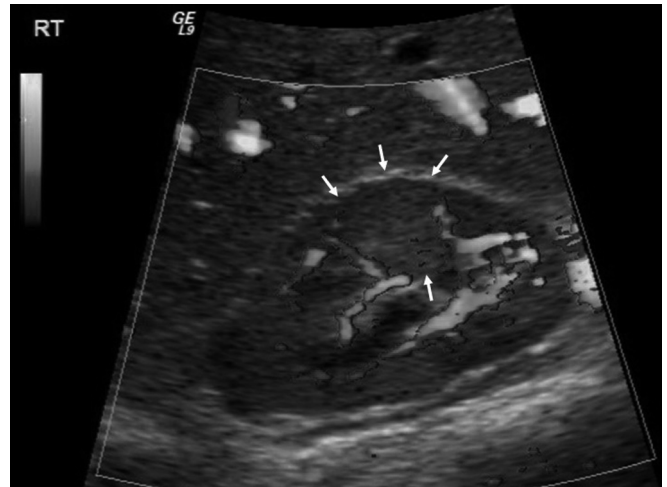**Figure 1.** Longitudinal scan of the right kidney in a 16 year old female. A round lesion of decreased echogenicity with a relative defined contour (between the arrows) is seen in the upper pole.



**Figure 2.** Longitudinal scan of the right kidney in a 22 year old female. Two round areas of increased echogenicity (arrows) are seen in the proximity of the cortex of the upper pole. Some outward bulging of the cephalic lesion is seen (arrowheads).



**Figure 3.** Transverse scan of the right kidney in a 33 year old female. A wedge-shaped area of increased echogenicity (arrows) is identified in the middle part of the kidney. The lesion presents no defined borders and complete blurring of the CMJ.



**Figure 4.** Power Doppler examination of the right kidney in a 27 year old female shows an area of decreased blood flow in the region of the hyperechoic lesion (arrows).

to the adjacent renal parenchyma. All these lesions appeared quite homogeneous in echogenicity, without the presence of a capsule. Twenty-six of these hyperechoic focal areas were in the right kidney and 19 in the left. In one patient a hyperechoic area was seen in each kidney, and in another patient two masses were identified in the same kidney [Figure 2]. Twenty-seven hyperechoic areas were located in the upper pole or in its proximity. The contours of all these lesions were not well defined. The size of the hyperechoic areas ranged from 1.6 to 4 cm. The CMJ appeared blurred in the majority of cases. The lesions were wedge-shaped in 34 patients [Figure 3] and appeared as an irregular mass in 13 [Figure 2]. In five cases, a small amount of perirenal fluid was also seen. Color/power Doppler examination was performed in 38 of the 47 cases. The focal area appeared avascular or hypovascular in all cases [Figure 4], with no hypervascularity seen in their periphery.

### Discussion

Since its first description by Rosenfield and colleagues in 1979 [1], AFN has been reported in several studies [2-6]. It is considered a midpoint in the spectrum of upper urinary tract infections, ranging from uncomplicated pyelonephritis to intrarenal abscesses [1,4]. No specific signs or symptoms differentiate acute focal pyelonephritis from uncomplicated pyelonephritis. The clinical presentation includes fever, flank pain, chills and pyuria, sometimes accompanied by abdominal pain, nausea, vomiting or tenderness of the costovertebral angle on the affected side [6]. Persistence of fever, despite antibiotic therapy, may be a clue to the presence of acute focal pyelonephritis or a renal abscess. Imaging studies are indicated when a patient with acute pyelonephritis fails to respond promptly to the appropriate antibiotic therapy. Usually, AFN is related to Gram-negative bacteria, usually *E. coli* [1,3]. In the majority of cases, the infection is of

the ascending type and only rarely is it due to hematogeneous spread [1].

The sonographic appearance of AFN is variable. Several authors consider the appearance of a focal wedge-shaped area [1,3] or an irregular mass [2] with decreased echogenicity to be typical forms of this entity. Characteristically, the lesion appears avascular on the color Doppler or power Doppler examination [7,8]. The hypo/avascularity of these masses is due to the compression and the narrowing of the small and large veins by the inflammatory infiltrate within the interstitium of the kidney [1], and the result is a reduced parenchymal blood flow in the involved segments identified also by the DMSA scan and computed tomography [9].

Until recently, a hyperechoic ultrasonographic appearance of AFN was considered uncommon or rare [2-4]. Rigsby et al. [4] suggested that increased echogenicity reflects an acute hemorrhage resulting from the venous abnormalities and obstruction. In contrast, Esteban and team [5] reported a case of hyperechoic AFN that appeared avascular on the color Doppler examination before and after administration of a contrast-enhancement sonographic agent. Recently, Farmer et al. [6] reported the hyperechoic sonographic appearance of AFN as the most common lesion (in 12 of 17 cases). In their study, they did not attempt to find a correlation with the appearance on color Doppler. The color Doppler examination seems to be significantly more sensitive than conventional sonography for the detection of AFN [9-11].

In our series, sonographic abnormalities were present in a minority of the whole cohort of the patients hospitalized for acute pyelonephritis who underwent ultrasound examination. A focal lesion was diagnosed in most cases and the hyperechoic appearance was the most frequent. These hyperechoic regions appeared more frequently as a "wedge" shape [Figure 3] rather than a "mass lesion" [Figure 2]. In all cases, the color Doppler examination demonstrated the area to be hypo/avascular [Figure 4].

We conclude that the hyperechoic appearance represents the most common manifestation of AFN. If the sonogram demonstrates a hyperechoic renal finding, the differential diagnosis must include a renal tumor (renal cell carcinoma, renal angiomyolipoma, etc). However, if a renal infection is present, the clinical and laboratory data usually allow one to diagnose AFN with confidence, especially when a post-treatment ultrasound follow-up is performed. Moreover, the lack of vessels within the

lesion and its periphery on the color Doppler examination or after administration of a contrast-enhancing ultrasonographic agent, as described in the literature [5,12], helps to establish the correct diagnosis and obviates further examinations.

**Acknowledgments.** We gratefully acknowledge Prof. Michael Grunebaum for his assistance in the preparation of this manuscript.

## References

1. Rosenfield AT, Glickman MG, Taylor KJ, Crade M, Hodson J. Acute focal bacterial nephritis (acute lobar nephronia). *Radiology* 1979;132:553-61.
2. Lee JKT, McClellan BL, Stanley RJ. Acute focal bacterial nephritis: emphasis on gray scale sonography and computed tomography. *Am J Roentgenol* AJR 1980;135:87-92.
3. Siegel ML, Glasier CM. Acute focal bacterial nephritis in children: significance of the ureteral reflux. *Am J Roentgenol* AJR 1981;137:257-60.
4. Rigsby CM, Rosenfield AT, Glickman MG, Hodson J. Hemorrhagic focal lobar nephritis: findings on gray-scale sonography and CT. *Am J Roentgenol* AJR 1985;146:1173-7.
5. Esteban JM, Gomes E, Santamaria JF. Hyperechoic focal bacterial nephritis: findings on contrast-enhancement colour Doppler ultrasound. *Eur J Ultrasound* 2001;13:201-4.
6. Farmer KD, Gelleff LR, Dubbins PA. The sonographic appearance of acute focal pyelonephritis: 8 years experience. *Clin Radiol* 2002;57:483-7.
7. Eggl KD, Eggl D. Color Doppler sonography in pyelonephritis. *Pediatr Radiol* 1992;22:422-5.
8. Sakarya ME, Arslan RE, Bozkurt M, Atilla MK. The role of power Doppler ultrasonography in the diagnosis of acute pyelonephritis. *Br J Urol* 1998;81:360-3.
9. Halevy R, Smolkin V, Bykov S, Chervinsky L, Sakran W, Koren A. Power Doppler ultrasonography in the diagnosis of acute childhood pyelonephritis. *Pediatr Nephrol* 2004;19:987-91.
10. Dacher JN, Pfister C, Monroc M, Eurin D, LeDosseur P. Power Doppler sonographic pattern of acute pyelonephritis in children: comparison with CT. *Am J Roentgenol* AJR 1996;166:1451-5.
11. Majd M, Nussbaum Blask AR, Markle BM, et al. Acute pyelonephritis: comparison of diagnosis with 99m Tc-DMSA SPECT, spiral CT, MR imaging and Power Doppler US in an experimental pig model. *Radiology* 2001;218:101-8.
12. Ascenti G, Zimbaro G, Mazziotti S, Gaeta M, Lamberto S, Scribano E. Contrast-enhanced power Doppler US in the diagnosis of renal pseudotumors. *Eur Radiol* 2001;11:2496-9.

**Correspondence:** Dr. V. Rathaus, Dept. of Diagnostic Imaging, Meir Medical Center, Kfar Saba 44281, Israel.

Phone: (972-9) 747-1512, Fax: (972-9) 746-1465  
email: rathaus@bezeqint.net