External Fixation for the Treatment of Intra-articular Fractures of the Distal Radius: Short-Term Results

Maruan Haddad MD[1], Guy Rubin MD[2], Michael Soudry MD[1,3] and Nimrod Rozen MD PhD[2,3]

[1]Department of Orthopedic Surgery A, Rambam Health Care Campus, Haifa, Israel
[2]Department of Orthopedics, HaEmek Medical Center, Afula, Israel
[3]Faculty of Medicine, Technion-Israel Institute of Technology, Haifa, Israel

ABSTRACT: **Background:** There is controversy as to which is the preferred treatment for distal radius intra-articular fractures – anatomic reduction or external fixation.

Objectives: To evaluate the radiologic and functional outcome following external fixation of these fractures.

Methods: Between January 2003 and March 2005, 43 patients with distal radius intra-articular fractures were treated using a mini-external AO device. Follow-up of 38 of the patients included X-rays at 1 week, 6 weeks and 6 months postoperatively. The Visual Analogue Scale was used to assess pain levels, and the Lidstrom criteria scale to evaluate functional outcome and wrist motion. Clinical and radiographic results were correlated.

Results: According to the Lidstrom criteria, the results were excellent in 31%, good in 61% and fair in 5.5%; 2.5% had a poor outcome. The results of the VAS were good. Thirty-five patients gained a good range of wrist movement, but 3 had a markedly reduced range. We found statistical correlation between the radiographic and clinical results, emphasizing the value of good reduction. There was no correlation between fracture type (Frykman score) and radiologic results or clinical results.

Conclusions: External fixation seems to be the preferred method of treatment for distal radius intra-articular fractures, assuming that good reduction can be achieved. The procedure is also quick, the risk of infection is small, and there is little damage to the surrounding tissues.

IMAJ 2010; 12: 406–409

KEY WORDS: distal radius fracture, Frykman classification, intra-articular fracture, K-wire

Fractures of the distal radius remain the most common fractures seen in the emergency room, with the majority being treated with plaster of paris cast following closed reduction with local anesthesia. However, other distal radial fractures require surgical management and many treatment methods are available. These can be divided into minimally invasive and invasive. The minimally invasive procedure is closed reduction with Kirschner wire and plaster cast or a mini-external fixator device; the invasive method is open reduction with internal fixation using plates. Despite the frequency of distal radius fractures, only a few studies have assessed the optimal surgical strategies for different fractures [1]. In the last decade many publications have supported the use of external fixation methods [2-4], and in view of the current trend of minimally invasive surgery, we set out to evaluate the radiologic and functional outcome of this method to treat distal radial intra-articular fractures.

VAS = Visual Analogue Scale

PATIENTS AND METHODS

Between January 2003 and March 2005, we used the following protocol for patients presenting at the ER with distal radius intra-articular fractures: a) closed reduction with local anesthesia for all adult patients (over 18 years old); b) once the fracture had stabilized, with X-ray confirmation, the patients were discharged; c) if stabilization could not be obtained, the patients were admitted for surgical treatment.

Surgery was performed on the same day or one day later and consisted of closed reduction and fixation with a mini-external AO device (Synthes, USA), using two threaded rods in the second metacarpal and another two radial rods [Figure 1]. In 20 cases, one or two K-wires were also inserted from the radial styloid to stabilize the fracture. All the rods were 2.7 mm, and the K-wires 1.6 mm. The mini-external device was removed 6 weeks later. A regimen of intensive physiotherapy was implemented immediately after discharge.

We performed surgery in 43 patients with distal radius intra-articular fractures; follow-up was conducted in 38 (22 women and 16 men) whose ages ranged from 23 to 81 years (mean 52.4 ± 18.6 years). All cases were unilateral. The fractures were graded according to the Frykman classification. Five patients were lost to follow-up: four patients had multiple injuries and died, and one patient, a tourist, returned to his country of origin.

ER = emergency room
K-wires = Kirschner wires

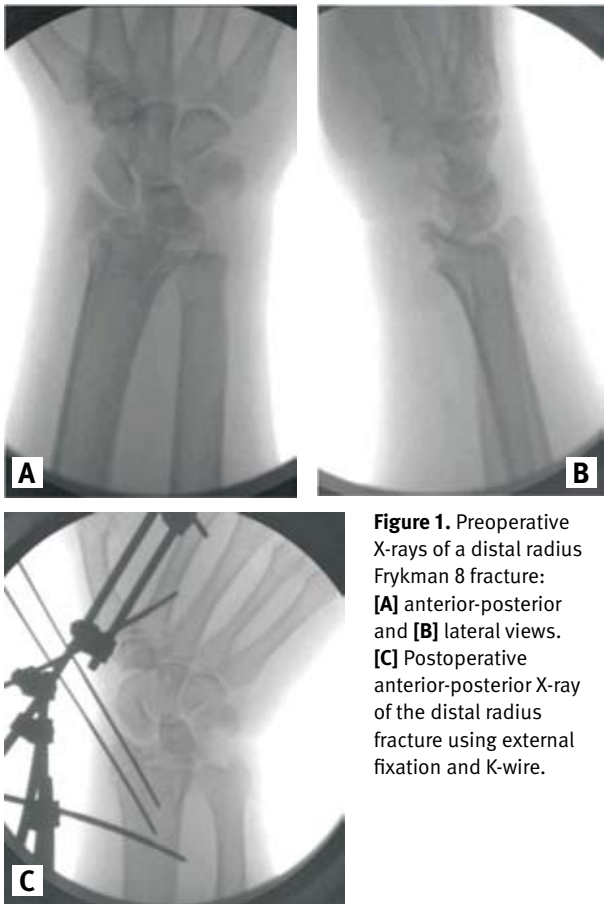

Figure 1. Preoperative X-rays of a distal radius Frykman 8 fracture: **[A]** anterior-posterior and **[B]** lateral views. **[C]** Postoperative anterior-posterior X-ray of the distal radius fracture using external fixation and K-wire.

The follow-up protocol was conducted 1 week, 6 weeks and 6 months postoperatively. The aims of the first two follow-ups were to identify infection and to verify the fracture position with X-ray to dispel the possibility of secondary displacement. The final follow-up, 6 months after surgery, included lateral and anterior-posterior X-rays, assessing the range of wrist movement, quantifying pain by the VAS, and evaluating functional outcome by the Lidstorm criteria [5].

STATISTICAL ANALYSIS

Independent *t*-tests or the Mann-Whitney non-parametric test was used to evaluate differences in continuous demographic and clinical variables between acceptable and non-acceptable volar tilt and radial shortening. Chi-square tests or Fisher exact tests were used to evaluate differences in categorical demographic and clinical variables between acceptable and non-acceptable volar tilt and radial shortening. To evaluate the connection between radial inclination or Lidstrom test and other variables, the Cochran-Armitage test for trend was used for the categorical independent variables and linear regression for continuous independent variables.

RESULTS

We documented pain and functional outcome; alignment was assessed on X-rays. The patients were asked to quantify pain following removal of the mini-external device in order to have a baseline value, and 6 months later. After 6 months, 33 patients (87%) had a VAS > 3. In four patients (11%) the VAS was > 5, and in one patient (2%) with extreme pain it was 9. Regarding functional outcome, 35 patients (92%) had an excellent or good outcome, and 3 (8%) had a fair or poor outcome.

X-RAY EVALUATION

The radial inclination, the volar tilt, and radio-ulna distance were measured on X-ray.

- **Radial inclination:** normal values are between 20° and 22°. In our study 16 (43%) were in the normal range, 15 (39%) were 15–19° and 7 (19%) were 23–25°. Age decreased with increasing radial inclination [Table 1] (from 15–19° to normal to 23–25°, $P < 0.004$). In addition, the Frykman score tended to decrease ($P < 0.10$). The percentage of males, dorsal flexion and ulnar deviation increased with increasing radial inclination ($P < 0.05$, $P < 0.02$ and $P < 0.005$, respectively).
- **Volar tilt:** acceptable values are 0–22° with a mean of 11. In our study 36 (95%) had a volar tilt of 0–22°. Two

Table 1. Demographic and clinical variables by radial inclination

	Radial inclination			
	15–19° (N=15)	Normal (N=16)	23–25° (N=7)	*P* trend
Age (yrs)	62.6 ± 17.9 (median 71)	47.7 ± 19.0 (median 42)	41.1 ± 5.3 (median 44)	0.004
Gender (% males)	26.7%	43.8%	71.4%	0.05
Frykman score	6.0 ± 1.5	5.4 ± 2.0	5.3 ± 1.4	0.10
VAS at 6 wks	5.7 ± 2.3	5.9 ± 1.6	5.1 ± 0.9	NS
VAS at 6 mos	2.3 ± 2.2	2.0 ± 1.5	2.4 ± 0.5	NS
Lindstrom scale				NS
Excellent	5 (33.3%)	6 (37.5%)	1 (14.3%)	
Good	8 (53.3%)	9 (56.2%)	6 (85.7%)	
Poor+fair	2 (13.3%)	1 (6.2%)	0 (0.0%)	
Volar tilt distribution				NS
Acceptable (0–22)	13 (86.7%)	16 (100%)	7 (100%)	
Radial length distribution				NS
2–4 mm shortening	4 (26.7%)	4 (25.0%)	0 (0.0%)	
Dorsal flexion	68.5 ± 12.3	77.6 ± 12.8	80.3 ± 5.9	0.02
Volar flexion	65.4 ± 20.3	70.9 ± 10.2	77.4 ± 4.7	0.07
Ulnar deviation	24.7 ± 13.3	28.9 ± 10.5	41.3 ± 7.5	0.005

Cochran-Armitage test for trend was used for categorical variables and linear regression for continuous variables

(5%) had a dorsal tilt of 2°. Volar tilt tended to increase with increasing radial inclination ($P < 0.07$). Patients with an unacceptable volar tilt [Table 2] were younger ($P < 0.004$) and had a higher Frykman score ($P < 0.0001$) than those with acceptable tilt. In addition, they had lower dorsal flexion ($P < 0.001$) and lower volar flexion ($P < 0.0001$). All patients with unacceptable volar tilt had 2–4 mm shortening of radial length and poor-fair Lindstrom scores, whereas only 16.7% with acceptable volar tilt had 2–4 mm shortening, and 2.8% with acceptable volar tilt had poor-fair Lidstrom scores.

- **Radial length:** normal length is 11 mm, and 2 mm of shortening is acceptable. In our study 29 patients (77%) had less than 2 mm of shortening. In the other 9 patients (23%) the shortening was 2–4 mm. Patients with 2–4 mm radial shortening [Table 3] had a higher Frykman score ($P < 0.02$) and lower volar flexion ($P < 0.04$) than patients with < 2 mm shortening. They tended to have a lower dorsal flexion ($P < 0.08$) and higher VAS at 6 months ($P < 0.07$) than patients with < 2 mm shortening. Patients with 2–4 mm radial shortening had a poorer outcome (Lidstrom) than patients with < 2 mm shortening ($P < 0.001$).

THE LIDSTROM EVALUATION

The percentage of males, the Frykman score and both VAS measures were prognostic factors for the clinical results ($P < 0.003$, $P < 0.0001$ and $P < 0.004$, $P < 0.001$, respectively). Volar tilt and radial length were also prognostic factors for the clinical results ($P < 0.002$ and 0.001, respectively). There was a correlation between the Lidstrom score and the final range of motion of the wrist ($P < 0.001$).

THE FRYKMAN CLASSIFICATION

Ordinal logistic regression was performed to predict the Lidstrom score using the Frykman classification as the main effect and gender as a covariate. For female patients a Frykman score of 3, 4 or 5 predicted excellent results; scores > 5 predicted good results. For male patients a Frykman score of 3 predicted excellent results; scores > 3 predicted good results. Fair and poor results could not be predicted. Ordinal logistic regression was performed to predict radial inclination using the Frykman score as the main effect and gender and age as covariates. Gender was not a significant predictor so it was removed from the model. The Frykman score did not predict radial inclination. Logistic regression was used to predict radial length shortening using the Frykman score as the dependent variable. A Frykman score of 8 predicted > 2 mm shortening. This model could only correctly predict 50% of the patients who had > 2 mm shortening and thus its validity is questionable. With regard to volar tilt, only two patients had an unacceptable tilt; both of these patients had a Frykman score of 8. An additional five patients with a Frykman score of 8 had an acceptable tilt.

Table 2. Demographic and clinical variables by volar tilt

	Volar tilt		
	Acceptable (N=36)	Tilt (N=2)	*P* value
Age (yrs)	53.4 ± 18.6 (median 46)	33.4 ± 3.8 (median 33.5)	0.004*
Gender (% males)	38.9%	100.0%	NS
Frykman score	5.5 ± 1.6	8.0 ± 0.0	0.0001
VAS at 6 wks	5.5 ± 1.6	9.0 ± 1.4	0.005
VAS at 6 mos	1.9 ± 1.2	6.5 ± 3.5	NS**
Lindstrom scale			0.004
Excellent	12 (33.3%)	0 (0.0%)	
Good	23 (63.9%)	0 (0.0%)	
Poor+fair	1 (2.8%)	2 (100.0%)	
Radial inclination			NS
% normal	16 (44.4%)	0 (0.0%)	
Radial length distribution			0.04
2–4 mm shortening	6 (16.7%)	2 (100.0%)	
Dorsal flexion	76.0 ± 10.9	47.5 ± 3.5	0.001
Volar flexion	72.4 ± 10.7	26.0 ± 8.5	0.0001
Ulnar deviation	30.0 ± 11.9	22.0 ± 26.9	NS

Table 3. Demographic and clinical variables by radial length

	Radial length shortening		
	< 2 mm (N=30)	2–4 mm (N=8)	*P* value
Age (yrs)	53.8 ± 17.7 (median 46)	46.9 ± 22.2 (median 39)	NS
Gender (% males)	36.7%	62.5%	NS
Frykman score	5.3 ± 1.6	6.9 ± 1.4	0.02
VAS at 6 wks	5.5 ± 1.7	6.2 ± 2.0	NS
VAS at 6 mos	1.9 ± 1.2	3.1 ± 2.6	0.07*
Lindstrom scale			0.001
Excellent	12 (40.0%)	0 (0.0%)	
Good	18 (60.0%)	5 (62.5%)	
Poor+fair	0 (0.0%)	3 (37.5%)	
Radial inclination			NS
% Normal	12 (40.0%)	4 (50.0%)	
Volvar tilt			0.04
Acceptable	30 (100%)	6 (750.0%)	
Dorsal flexion	77.3 ± 9.1	64.1 ± 17.9	0.08**
Volar flexion	74.0 ± 9.6	54.9 ± 21.4	0.04
Ulnar deviation	31.5 ± 10.9	22.2 ± 16.0	NS*

COMPLICATIONS

There were several complications during our study; 4 patients (10%) had a local superficial pin tract infection treated by oral antibiotics (amoxicillin/clavulanate potassium) for 5 days. One patient (2%) still had pain 6 months later and began treatment for complex regional pain syndrome in the Pain Clinic.

THE ADDITION OF KIRSCHNER WIRE

We compared patients treated with external fixation alone and those who had the addition of K-wire fixation. There were no demographic or X-ray evaluation differences (although there tended to be a difference in volar flexion, $P < 0.07$)). The group that received the addition of K-wire fixation differed in the Frykman score ($P < 0.003$) and VAS at 6 weeks ($P < 0.05$). The VAS was the same at 6 months.

DISCUSSION

The treatment of distal radial fractures is constantly changing. At the end of the 1990s, open reduction and internal fixation by plating was the favored approach, with orthopedic surgeons returning to the principle of ligamentotaxis for fracture reduction [6-8]. This technique for treating unstable distal radius fractures has gained wide acceptance. A number of studies have shown favorable results following external fixation of distal radial fractures [6,8-10]. The addition of K-wire when treating highly unstable fractures was shown to improve the results [7,11-14].

We demonstrated that the addition of K-wire in the less stable fractures elicited an improvement only in VAS score after 6 weeks. In our series, 92% had excellent or good outcomes 6 months postoperatively with 33 patients (86%) having minimal pain (< 3 in the VAS).

On X-ray, the volar tilt was successfully achieved. All but two of the patients (5%) had a volar tilt of up to 16°. The radial length was restored in 77% and excessively shortened by 3–4 mm in 9 patients (23%). We found statistical correlation between the radiographic and the clinical results, emphasizing the importance of achieving good reduction, but there was no correlation between the fracture type (Frykman) and the radiologic or the clinical results.

External fixation seems to be the preferred procedure for treating distal radius intra-articular fractures. The procedure is quick, and the technical learning curve is shorter. The chance of infection is small and less damage occurs in the surrounding tissue compared to open reduction with internal fixation.

Corresponding author:
Dr. G. Rubin
Dept. of Orthopedics, HaEmek Medical Center, Afula 18101, Israel
email: guytalr@bezeqint.net

References

1. Henry MH. Distal radius fractures: current concepts. *J Hand Surg [Am]* 2008; 33(7): 1215-27.
2. Margaliot Z, Haase SC, Kotsis SV, Kim HM, Chung KC. A meta-analysis of outcomes of external fixation versus plate osteosynthesis for unstable distal radius fractures. *J Hand Surg [Am]* 2005; 30: 1185-99.
3. Westphal T, Piatek S, Schubert S, Winckler S. Outcome after surgery of distal radius fractures: no differences between external fixation and ORIF. *Arch Orthop Trauma Surg* 2005; 125: 507-14.
4. Zamzuri Z, Yusof M, Hyzan MY. External fixation versus internal fixation for closed unstable intra-articular fracture of the distal radius. Early results from a prospective study. *Med J Malaysia* 2004; 59: 15-19.
5. Lidstrom A. Fractures of the distal end of the radius – a clinical and statistical study of end results. *Acta Orthop Scand* 1959; Suppl 41.
6. Egol KA, Paksima N, Puopolo S, Klugman J, Hiebert R, Koval KJ. Treatment of external fixation pins about the wrist: a prospective, randomized trial. *J Bone Joint Surg Am* 2006; 88: 349-54.
7. Fu YC, Chien SH, Huang PJ, et al. Use of an external fixation combined with the buttress-maintain pinning method in treating comminuted distal radius fractures in osteoporotic patients. *J Trauma* 2006; 60: 330-3.
8. Huang TL, Huang CK, Yu JK, et al. Operative treatment of intra-articular distal radius fractures using the small AO external fixation device. *J Chin Med Assoc* 2005; 68: 474-8.
9. Cooney WP, Linschied RL, Dobyns J. External pin fixation for unstable Colles' fractures. *J Bone Joint Surg* 1979; 61A: 840-5.
10. Hegeman JH, Oskam J, Vierhout PA, Ten Duis HJ. External fixation for unstable intra-articular distal radial fractures in women older than 55 years. Acceptable functional end results in the majority of the patients despite significant secondary displacement. *Injury* 2005; 36: 339-44.
11. Gradl G, Jupiter JB, Gierer P, Mittlmeier T. Fractures of the distal radius treated with a nonbridging external fixation technique using multiplanar k-wires. *J Hand Surg [Am]* 2005; 30: 960-8.
12. Lin C, Sun JS, Hou SM. External fixation with or without supplementary intramedullary Kirschner wires in the treatment of distal radial fractures. *Can J Surg* 2004; 47: 431-7.
13. Weil WM, Trumble TE. Treatment of distal radius fractures with intrafocal (kapandji) pinning and supplemental skeletal stabilization. *Hand Clin* 2005; 2: 317-28.
14. Werber KD, Raeder F, Brauer RB, Weiss S. External fixation of distal radial fractures: four compared with five pins: a randomized prospective study. *J Bone Joint Surg Am* 2003; 85-A: 660-6.

"When you aim for perfection, you discover it's a moving target"

Anonymous

"Thieves respect property. They merely wish the property to become their property that they may more perfectly respect it"

G.K. Chesterton (1874-1936), English writer, whose prolific and diverse output included philosophy, poetry, playwriting, journalism, public lecturing and debating, fantasy and detective fiction