

Chest Wall Actinomycosis

Anna Chernihovski MD¹, Norman Loberant MD¹, Isaac Cohen MD², Faris Nassar MD³, Joseph Lemer FRCS Ed⁴ and Edward Altman MD⁴

Departments of ¹Radiology, ²Pathology, ³Internal Medicine and ⁴Thoracic Surgery, Western Galilee Hospital, Nahariya, Israel
Affiliated to Rappaport Faculty of Medicine, Technion-Israel Institute of Technology, Haifa, Israel

Key words: actinomycosis, chest wall, computed tomography, surgical biopsy.

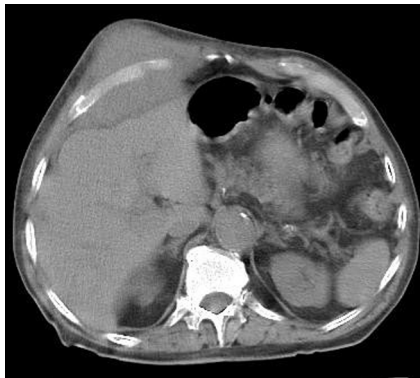
IMAJ 2007;9:686-687

Thoracic actinomycosis is a relatively uncommon anaerobic infection. Thoracic actinomycosis limited to the chest wall is very rare, and may be confused with a soft tissue malignancy [1,2], especially in the absence of typical cutaneous sinus with purulent discharge, and without pulmonary involvement on chest computed tomography. A correct diagnosis is required to prevent unnecessary major surgery. We present a rare case of thoracic actinomycosis localized in the anterior chest wall.

Patient Description

An 81 year old male smoker was admitted to the thoracic surgery department because of a rapidly increasing swelling of the right anterior chest wall of 3 weeks duration. There was no history of fever or cough. The patient had lost about 4 kg in weight over the previous 2 months. Medical history included coronary artery bypass graft surgery 12 years previously. On physical examination a 6.5 x 7 cm subcutaneous mass was palpated in the right anterior chest wall at the level of the sixth to ninth ribs between the midclavicular and anterior axillary lines. The mass was non-tender, firm to hard, immobile and cool to the touch, accompanied by minimal skin erythema. Physical examination was otherwise unremarkable. Laboratory examination showed a white blood cell count of 9.3 x 10⁹/L and hemoglobin of 10.8 g/dl.

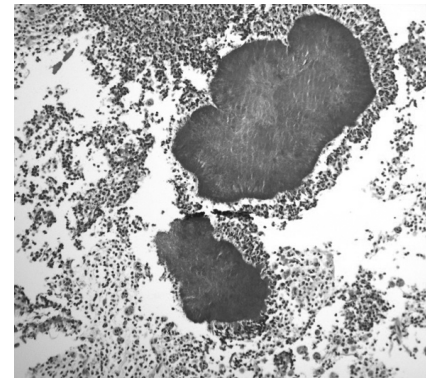
Chest CT showed a soft tissue mass in the lower right anterior chest wall [Figure A]. There was moderate pleural effusion on the right side and minimal pleural thickening on the left side. Both the ribs and lung parenchyma appeared normal.



[A] Non-enhanced CT scan at the level of the lower ribs demonstrates a large soft tissue mass in the right chest wall, extending through the intercostal spaces and applying external pressure on the liver.

Fine needle aspiration was performed and cytology smear showed heavy cellularity consisting of polymorphonuclear leukocytes, histiocytes and degenerative cells. Since the FNA was inconclusive, core biopsy was performed and histological examination showed fibrotic tissue with areas of intensive inflammation. Owing to inconclusive results of the biopsies, the patient underwent an incisional biopsy under general anesthesia. At operation the mass was firm and adherent to the ribs. The cut surface was homogeneous in appearance, gray in color, and was infiltrative in form with no visible capsule. There were no postoperative complications. Histology of the surgical biopsy revealed sulfur granules of actinomyces colonies, surrounded by a purulent inflammatory infiltrate consisting of polymorphonuclear leukocytes [Figure B]; the actinomyces colonies showed typical peripheral eo-

FNA = fine needle aspiration



[B] Histological specimen from chest wall biopsy shows colonies of actinomyces, surrounded by neutrophils (low power hematoxylin-eosin stain).

sinophilic material (Splendore-Hoeppli reaction).

Based on the biopsy results, a course of intravenous penicillin G, 20 million units daily for 28 days, was started. After the first 2 weeks of treatment the chest wall mass decreased notably in size and after a month was no longer palpable. At that time, follow-up CT showed a considerable decrease in the size of the soft tissue mass in the right chest wall; the right pleural effusion had resolved completely, and there was still mild pleural thickening on the left side.

The patient was discharged in good condition, and was prescribed oral erythromycin for an additional 6 months. At 1 year follow-up he was asymptomatic with no evidence of recurrence.

Comment

Actinomycosis is an uncommon disease caused by Gram-positive anaerobic bacteria from the group of Actinomyces, which

is a common saprophyte of the oral cavity, gastrointestinal tract and bronchial secretions [1]. *Actinomyces israelii* is the most common pathogen, though other species (especially *Actinomyces meyeri*) may also cause disease [2]. There are few accurate data on the incidence of actinomycosis, but it appears to have declined markedly in the last three to four decades. The presentation of thoracic actinomycosis has also changed [2].

There are three major forms of actinomycosis: cervicofacial (65%), abdominal (20%), and thoracic (15%). Thoracic actinomycosis usually involves the lungs, pleura, mediastinum and chest wall. Men are affected three to four times more frequently than women [3]. Thoracic infection most often follows aspiration of endogenous organisms of the mouth and oropharynx in patients with a predisposing factor of poor oral hygiene [4]. Infection usually originates in the pulmonary parenchyma and may progress to the chest wall via direct extension through the pleura [3]. Infection in the chest wall may lead to the classic cutaneous finding of a skin sinus with purulent discharge.

Thoracic actinomycosis limited to the chest wall, with no evidence of pulmonary

involvement and without evidence of other infectious sites, is very rare. Various etiologies may be proposed. First, hematogenous dissemination may result in soft tissue lesions in any location, including the chest wall. Second, extension from cervical and abdominal actinomycosis may result in chest wall involvement. Third, a chest wall infection may result from a pulmonary primary lesion that has resolved either spontaneously or from antibiotic treatment in the interim [1]. In such cases, a chest wall mass can be easily confused with a malignant tumor – namely, primary carcinoma with chest wall involvement, lymphoma, or primary sarcoma. Thoracic actinomycosis may also be associated with malignancy [1,2]. Other infections, such as tuberculosis, aspergillosis, pyogenic abscess due to *Staphylococcus* or *Klebsiella* infection, may also occur as an isolated chest wall process, and must be included in the differential diagnosis [5].

Diagnosis must be based on histopathological findings. Fine needle aspiration biopsy or even core needle biopsy may, as in our case, show only inflammatory or fibrous cells without revealing the infectious organism. Thus, appropriate surgical biopsy remains the mainstay of diagnosis.

A chest wall mass, even in the absence of pulmonary findings and cutaneous sinus, may be a presentation of actinomycosis; a combination of appropriate histological, microbiological and molecular studies will maximize chances of successful diagnosis.

References

1. Kapotsis GE, Daniil Z, Klimopoulos S, et al. A painful and swollen right breast in a young male. *Eur Respir J* 2004;24:1066–8.
2. Mabeza GF, Macfarlane J. Pulmonary actinomycosis. *Eur Respir J* 2003;21:545–51.
3. Kwong JS, Muller NL, Godwin JD, Aberle D, Grymaloski MR. Thoracic actinomycosis: CT findings in eight patients. *Radiology* 1992;183:189–92.
4. Webb WR, Sagel S. Actinomycosis involving the chest wall: CT findings. *AJR Am J Roentgenol* 1982;139:1007–9.
5. Watt AJB. Chest wall lesions. *Paediatr Respir Rev* 2002;3:328–38.

Correspondence: Dr. A. Chernihovski, Dept. of Radiology, Western Galilee Hospital, Nahariya 22100, Israel
 Phone: (972-4) 910-7756
 Fax: (972-4) 910-7683
 email: achernihovsky@yahoo.com