

## Amyopathic Dermatomyositis – An Uncommon Presentation of Dermatomyositis

Yoav Arnson MD, Zamir Dovrish MD, Ruth Hadari MD and Howard Amital MD MHA

Department of Medicine D, Meir Medical Center, Kfar Saba, Israel  
Affiliated to Sackler Faculty of Medicine, Tel Aviv University, Ramat Aviv, Israel

**Key words:** dermatomyositis, rash, arthralgia, hydroxychloroquine, amyopathic dermatomyositis

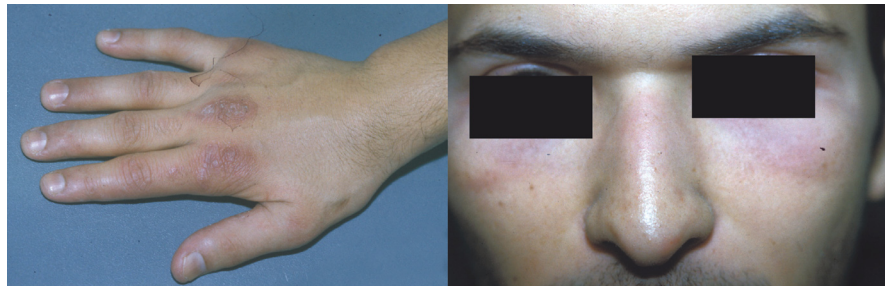
*IMAJ 2007;9:492–493*

Dermatomyositis is a progressive autoimmune condition characterized by inflammatory skin lesions with concomitant muscle weakness. Amyopathic dermatomyositis, a term first coined by Pearson in 1963, is a rare but well-recognized clinical subtype of dermatomyositis, constituting 2–18% of patients with this disease. The condition is also known as dermatomyositis sine myositis and is occasionally referred to as cutaneous dermatomyositis. Amyopathic dermatomyositis patients generally have pathognomonic skin findings but no clinical or laboratory evidence of muscle disease. Although cutaneous lesions were found to precede muscle weakness in 56% of patients with classical dermatomyositis, muscle involvement appears within 3–6 months in most patients.

In 1993, Euwer and Sontheimer published four diagnostic criteria for amyopathic dermatomyositis: a) cutaneous changes pathognomonic of dermatomyositis, b) skin biopsy specimen findings compatible with dermatomyositis, c) absence of clinical evidence of proximal motor weakness within 2 years of skin disease, and d) normal skeletal enzyme levels for 2 years following the appearance of skin lesions [1].

### Patient Description

A 24 year old healthy male presented after 4 months of arthralgia, mainly in the elbow and wrist joints accompanied by arthritis of almost all the metacarpal phalangeal joints, and swelling with erythema that extended to the knees and ankles. No muscle weakness was noted. In addition, he reported general weakness, prolonged subfebrile fever, dryness and swelling of the eyes, rest tachycardia,



CT images of bypass grafts from different angles.

apthae and 7 kg weight loss during the previous 4 months. His symptoms first appeared when he was in the United States, where he had been working with synthetic polymers.

Upon the appearance of the complaints, he was assumed to be suffering from a spondyloarthropathy, and indomethacin treatment was initiated. The arthralgia abated, but a rash later appeared on the cheeks and the knuckles [Figure]. Laboratory tests showed mild normochromic normocytic anemia (hemoglobin 11.6 g/dl) and erythrocyte sedimentation rate of 30 mm/hour. Findings from muscle enzyme assays were as follows: lactate dehydrogenase 580 IU/L (normal 230–460 IU/L) and creatine phosphokinase 71 IU/L (normal 15–195 IU/L). Tests were negative for antinuclear, anti-endomysial and anti-Jo1 antibodies. Complement levels were within the normal range. There were no electrocardiographic abnormalities. A chest and abdomen computed tomography scan demonstrated enlarged mediastinal and axilar lymph nodes reaching a diameter of up to 2 cm. A biopsy taken from an axilar lymph node showed no signs of malignancy. The patient had no respiratory complaints and his chest X-ray was normal. Muscle ultrasonography showed mild

atrophy in the left hip muscles compared to the right side. An electromyogram did not reveal any pathology.

Systemic glucocorticoid therapy was instituted (30 mg prednisone once daily) accompanied by hydroxychloroquine 200 mg twice a day. The articular pain diminished quickly followed by the gradual resolution of the cutaneous manifestations. The steroid therapy was tapered down but his arthritis flared. Therefore, weekly methotrexate was added with no significant improvement and was replaced by cyclosporine therapy.

### Comment

Amyopathic dermatomyositis is a rare but distinct subtype of dermatomyositis. It presents clinically with the pathognomonic cutaneous manifestations of dermatomyositis (consisting of heliotrope rash, facial erythema and edema, Gottron's papules and periungual telangiectasia) but without associated skeletal muscle involvement. ADM cannot be diagnosed in patients taking immunosuppressive therapy, which may suppress muscle manifestations, or medications known to induce dermatomyositis-like skin lesions (e.g., hydroxyurea).

ADM = amyopathic dermatomyositis

Women are affected more often than men in a 3:1 ratio. Onset usually occurs in early adulthood, although juvenile forms have been reported. Heliotrope rash and Gottron's papules are the most common skin changes (50–80% of patients). Their clinical and histological features are identical to those seen in classic dermatomyositis [2,3]. The three main factors predicting prognosis in ADM patients are the following: development of lung disease, development of malignancy, and development of clinical muscle weakness.

In the case presented, the reported symptoms were arthralgia accompanied by redness and swelling of the hand, elbow and knee joints, as well as dryness in the eyes, aphthae and weight loss. Our patient had documented skin changes pathognomonic of dermatomyositis. He reported mild muscle weakness, although clinical tests and electromyogram noted no objective findings.

Pulmonary involvement has been described in patients with ADM, mainly rapidly progressive interstitial pneumonia, pneumomediastinum, and pulmonary fibrosis [4]. Our patient had no respiratory symptoms; a chest X-ray had been performed but showed no pulmonary involvement. Nonetheless, it is essential that a routine follow-up be performed for all ADM patients since the changes can appear years after the disease onset. Investigations for a malignancy should be done in all patients with dermatomyositis, including those with the amyopathic form. Between 6% and 60% of dermatomyositis patients have been reported to have

internal malignancies: Ovarian and breast carcinoma in women, lung and prostate carcinoma in men, and lymphoma in both genders are highly associated with dermatomyositis. The percentage of patients with malignancies was similar in patients with classic dermatomyositis and in those with ADM. Older age at onset and male gender has been reported to indicate a greater risk for developing cancers [5].

ADM should be aggressively treated even in the absence of muscle involvement since intense and prolonged skin inflammation can result in cutaneous ulceration/scarring, poikiloderma and cutaneous calcinosis. Also, significant psychosocial and occupational morbidity/disability can result from chronic recurrent dermatomyositis skin inflammation. The treatment of dermatomyositis and ADM is based on systemic immunosuppressive therapy (high dose corticosteroids and steroid-sparing drugs such as methotrexate, azathioprine, cyclosporin, mycophenolate) or immunomodulatory therapy (high dose intravenous immunoglobulins). Potent, long-acting sedating antihistamines given at bedtime can be quite helpful for the nocturnal pruritus/dysesthesia caused by dermatomyositis skin inflammation. Local therapy can serve as adjunctive treatment in all cutaneous dermatomyositis patients, sometimes decreasing the dosage or shortening the time required for systemic treatment. Muscle weakness can develop even 6–8 years after the first symptoms or skin changes. Elevation of the creatine kinase level can predict the onset of clinically appreciable muscle disease.

In summary, ADM is a rare variant of dermatomyositis but should be borne in mind. The skin changes are identical to those seen in classic dermatomyositis, and may remain isolated for many months or years. The absence of muscle involvement may explain the fairly favorable outcome, but aggressive treatment must be initiated to prevent chronic skin changes and pulmonary involvement. Observation for associated malignancy is as important as with classic dermatomyositis, particularly in adults.

---

## References

1. Sontheimer RD. Cutaneous features of classic dermatomyositis and amyopathic dermatomyositis. *Curr Opin Rheumatol* 1999;11:475–82.
2. Caproni M, Cardinali C, Parodi A, et al. Amyopathic dermatomyositis: a review by the Italian Group of Immunodermatology. *Arch Dermatol* 2002;138:23–7.
3. Euwer RL, Sontheimer RD. Amyopathic dermatomyositis: a review. *J Invest Dermatol* 1993;100:124–7S.
4. Sontheimer RD. The management of dermatomyositis: current treatment options. *Expert Opin Pharmacother* 2004;5:1083–99.
5. Gerami P, Schope JM, McDonald L, Walling HW, Sontheimer RD. A systematic review of adult-onset clinically amyopathic dermatomyositis (dermatomyositis sine myositis): a missing link within the spectrum of the idiopathic inflammatory myopathies. *J Am Acad Dermatol* 2006;54:597–613.

---

**Correspondence:** Dr. H. Amital, Head, Dept. of Medicine D, Meir Medical Center, Kfar Saba 44281, Israel.  
Phone: (972-9) 747-2598 ; Fax: (972-9) 747-1313  
email: howard.amital@clalit.org.il