

Open Zenker's Diverticulectomy as the Definite Procedure in Acute Dysphagia

Inon Buda MD¹, Alon Yellin MD² and Yoav P. Talmi MD FACS²

Departments of ¹Otorhinolaryngology-Head and Neck Surgery, and ²Thoracic Surgery, Sheba Medical Center, Tel Hashomer, Israel
Affiliated to Sackler Faculty of Medicine, Tel Aviv University, Ramat Aviv, Israel

Key words: Zenker's diverticulum, hypopharyngeal diverticulum, nutrition, feeding tube, surgery

IMAJ 2007;9:410-411

Zenker's diverticulum (pharyngeal pouch) is a well-recognized problem occurring mainly in the elderly patient. Reduced cricopharyngeal compliance may be the underlying pathophysiological mechanism. Symptoms are derived both from the presence of the sac and from the cricopharyngeal abnormality [1] and usually include food regurgitation and dysphagia. Recurrent aspiration pneumonia is another potentially life-threatening complication. The onset of symptoms is usually insidious and patients may be symptomatic for many years before undergoing surgery. Surgical technique varies and includes myotomy, myotomy with sac diverticulectomy, open diverticulectomy, possibly with stapler use, and endoscopic approach with carbon dioxide laser or a stapling device [2]. The surgical approach selected varies according to the patient's general condition and the surgeon's experience and is usually an elective procedure. We describe two cases in which a semi-emergency open diverticulectomy was performed for treating Zenker's diverticulum

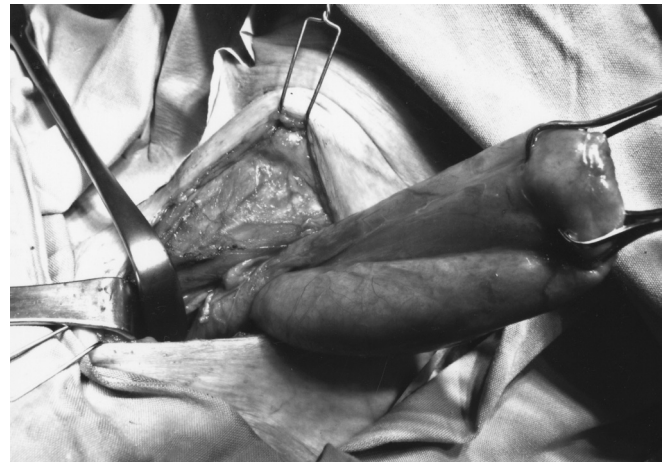Patient Descriptions

Patient 1

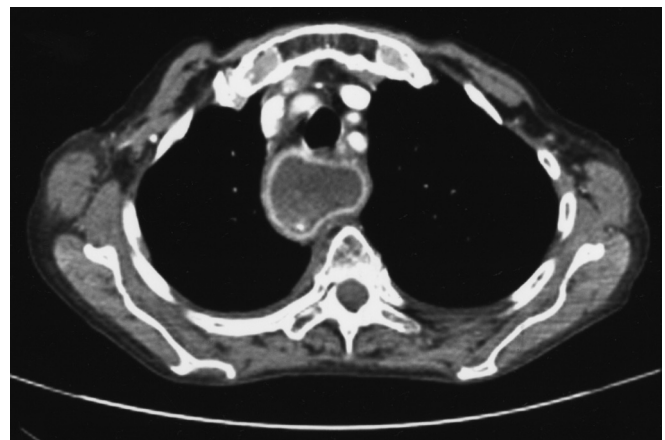
A frail 90 year old woman suffering from hypothyroidism, vitamin B12 deficiency, Zenker's diverticulum of 3 years duration and recurrent aspiration pneumonia was admitted to the department of internal medicine because of benzodiazepine overdose and was treated with flumazenil. During hospitalization, she developed aspiration pneumonia. She could not eat due to food regurgitation and repeated aspirations. Bedside attempts to carefully introduce a feeding tube failed and the patient was taken for fluoroscopy.

Repeated attempts to insert a feeding tube failed despite maneuvers and position changes. The hypopharynx could not be visualized by endoscopy despite repeated attempts. Only a small intravenous line could be inserted and while fluid intake was possible, parenteral feeding was not an option nor was percutaneous endoscopic gastrostomy. At this point the possibility of open gastrostomy was considered but since the patient was about to undergo surgery under general anesthesia, we decided to perform diverticulectomy as the definite procedure.

An open procedure was performed via a transcervical excision, and the sac, found to contain contrast media and other remains, was excised and a nasogastric tube introduced [Figure A]. Due to esophageal friability, hand suturing was applied. Following the procedure a small fistula developed but spontaneously healed after 6 days and oral intake was resumed one week later. Today, 3 months



[A] Large exposed diverticular sac



[B] Axial CT scan demonstrating a large diverticular sac in the upper mediastinum

after surgery, the patient is eating a normal diet without any sequelae.

Patient 2

An 83 year old woman with ischemic heart disease, sub-aortic stenosis, hypothyroidism, recurrent aspiration pneumonia and

recently diagnosed Zenker's diverticulum was admitted for severe dysphagia. Computerized tomography imaging demonstrated a large retropharyngeal sac [Figure B]. Attempts to perform PEG or even introduce a nasogastric tube failed. The endoscopist could not visualize the esophageal opening, and despite a team effort the esophagus could not be entered. Parenteral nutrition was initiated.

Open gastrostomy was originally suggested but diverticulectomy as the definite procedure was performed. An open procedure was performed via a trans-cervical excision. The postoperative course was uneventful and the patient was discharged on a semi-solid diet.

Comment

There is hardly disagreement about the need to resolve the problem of Zenker's diverticulum in the elderly symptomatic patient with life-threatening manifestations such as recurrent aspiration pneumonia [3]. We report two cases of elderly patients with recurrent aspiration pneumonia and severe dysphagia due to Zenker's diverticulum. Both had symp-

PEG = percutaneous endoscopic gastrostomy

toms of pulmonary aspiration requiring multiple hospitalizations for life-threatening pneumonia and major weight loss. No reasonable optional routes for nutrition were available and we were faced with the dilemma of whether to perform an immediate definite procedure, and if so, which one. Van Overbeek [4] recommended the endoscopic method with a stapling device in the elderly patient. While we regularly perform this procedure at our institution, this option was ruled out because adequate visualization was not possible. Louie and Zuckerbraun [5] proposed a two-stage open procedure. In the first stage, myotomy, diverticulectomy and cervical esophagostomy are performed and a gastric feeding tube is introduced. After the patient has recovered from pulmonary complications and there is nutritional improvement, the feeding tube is removed and the esophagostomy is closed. While this seems a viable option, a single-stage procedure was adopted in our patients and both have resumed oral intake without recurrence of aspirations.

Although we presented only two cases of semi-emergency Zenker's diverticulectomy, we have shown that if no alternative

temporary means of feeding are possible and endoscopic stapling is not an option, a single-stage definite open procedure is a logical alternative.

References

1. Aly A, Devitt PG, Jamieson GG. Evolution of surgical treatment for pharyngeal pouch. *Br J Surg* 2004;91:657-64.
2. Talmi YP, Finkelstein Y, Sadov R, Shvili RY, Zohar Y. Use of a linear stapler in excision of Zenker's diverticulum. *Head Neck* 1989;11:150-2.
3. Crescenzo DG, Trastek VF, Allen MS, Deschamps C, Pairolero PC. Zenker's diverticulum in the elderly: is operation justified? *Ann Thorac Surg* 1998;66:347-50.
4. van Overbeek JJM. Meditation on the pathogenesis of hypopharyngeal (Zenker's) diverticulum and a report of endoscopic treatment in 545 patients. *Ann Otol Rhinol Laryngol* 1994;103:178-85.
5. Louie HW, Zuckerbraun L. Staged Zenker's diverticulectomy with cervical esophagostomy and secondary esophagostomy closure for treatment of massive diverticulum in severely debilitated patients. *Am Surg* 1993;12:842-5.

Correspondence: Dr. Y. Talmi, Dept. of Thoracic Surgery, Sheba Medical Center, Tel Hashomer 52621, Israel.

Fax: (972-3) 530-5387

email: yoav.talmi@sheba.health.gov.il

Capsule

The macaque genome

In its 13 April 2007 issue, *Science* unveiled the genome sequence of one of biology's most important model organisms – the rhesus macaque monkey (*Macaca mulatta*). In the same issue, a research article and four reports, as well as two news stories, detail the biomedical and evolutionary insights gained from the macaque genome, only the third primate genome to be completed after the human and the chimpanzee. Online, an interactive poster enhanced with images, discussions and videos, explores the significance of the rhesus macaque and its draft genome sequence to studies of primate biology and evolution. Accompanying the online feature is an educational resource for high school biology teachers, which includes teacher background information, a lesson plan, and student worksheet. All articles in the *Science* rhesus macaque special section, as well as the interactive poster and teaching resource, are free to all site

visitors. The Rhesus diverged from the human evolution tree 25 million years ago, while the chimpanzee diverged about 6 million years ago. This is a powerful tool for researchers to determine whether difference between human and chimp genome can be attributed to deletion or insertion, for example. The Rhesus monkey share around 95–96% of the genome with humans (the chimp around 98–99%) and its physiology is very similar to that of humans. The macaques are the most successful genera after humans in survival all over the world (an interesting fact: no Macaque perished during Katrina in Louisiana, although all the kennels were destroyed). It has been used for biomedical research in many areas, such as HIV/AIDS, neurobiology, behavior, aging, vaccine development, and disease-related alleles.

Eitan Israeli

