

Lengthening Temporalis Myoplasty for Facial Palsy Reanimation

Yaron Har-Shai MD¹, Issa Metanes MD¹, Samih Badarny MD², Pnina Cuzin BA³, Tamir Gil MD¹, Shraga Mayblum MD¹, Boaz Aman MD¹ and Daniel Labbé MD⁴

¹Unit of Plastic Surgery and ²Department of Neurology, Carmel Medical Center, Haifa, Israel

³Department of Speech Therapy, Linn Medical Center, Haifa, Israel

Affiliated to Rappaport Faculty of Medicine, Technion-Israel Institute of Technology, Haifa, Israel

⁴Department of Plastic and Reconstructive Surgery, Caen University Hospital, Caen, France

Key words: facial paralysis, temporalis muscle myoplasty, dynamic reanimation

IMAJ 2007;9:123–124

Facial paralysis severely hinders mastication, speech production and eye protection, but above all it deprives one of the essential means of mental and affective expressions: the mimic and smile. For this reason it is considered a highly important functional and esthetic handicap. The procedures for the treatment of total unilateral facial paralysis are either static or dynamic, the latter giving the best result.

Facial reanimation using lengthening temporalis myoplasty is a dynamic procedure rooted in Gillies' idea [1], which in 1934 formulated the concept of using part of the temporalis muscle with a strip of the fascia lata. In 1949 McLaughlin [2] described a method that used the whole temporalis muscle after sectioning the coronoid process, still utilizing a strip of the fascia lata. In 2000 this dynamic technique was further improved by Labbé and Huault [3] who reported a true myoplasty procedure using no intermediate grafts. The temporalis muscle is elongated and the released coronoid tendon of the muscle is transferred to the nasolabial fold and lips, thus preserving a fixed temporal point. The technique has been practiced by Labbé for the last 11 years with satisfactory results, and was recently implemented at the Carmel Medical Center, Haifa. We describe our experience of facial reanimation in five patients.

Patient Descriptions

Patients 1 and 2: Two men, 54 and 59 years old, suffered from a left and right complete peripheral facial palsy, respectively,

for the last 10 years due to an excision of acoustic neuroma. The patients had both the physiologic functional disabilities and the stigma of facial disfigurement that had destroyed their professional careers.

Patients 3 and 4: Two women, 56 and 50 years old, suffered from a left complete peripheral facial palsy 4 and 18 months, respectively, following an excision of acoustic neuroma. The latter patient had previously undergone lateral tarsoraphy of the left eyelids.

Patient 5: A 50 year old woman had a left complete peripheral facial palsy for 20 years due to an excision of acoustic neuroma. Six years previously she underwent a satisfactory static surgical attempt for facial reanimation using tensor fascia lata slings.

Surgical method

The patient's smile was evaluated preoperatively according to the Rubin classification [4], which is based on the point of insertion of the zygomatic muscles to the nasolabial fold, commissure and orbicularis oris contraction vectors on the healthy side. These insertion points are marked as a mirror image on the paralyzed side along the nasolabial fold and commissure; in addition, the nasolabial crease is lined according to the healthy side as well. The different smile patterns consist of: the commissure smile – which is the common Mona Lisa type of smile; the cupid smile – which is a canine type; and the rare full-teeth complex smile. Fourteen days prior to surgery the patient

underwent Botox™ injection to the zygomatic, orbicularis oris and depressor labi muscles (as required according to the smile classification) to weaken the tensioned healthy smile muscles.

The surgical technique consists of a W-shaped coronal incision, which allows exposure of the temporal aponeurosis and muscle as well as the zygomatic arch on the paralyzed side. The zygomatic arch is sectioned using a saw, and shifted inferiorly, still attached to the masseter muscle and underlining subcutaneous tissue. The coronoid process is osteotomized from the mandible. The entire temporalis muscle is dissected off the temporal fossa, while the deep temporal nerve and vessels, which are often clearly visible at the deep inferior border of the muscle, are preserved. An incision is made in the nasolabial crease (which was marked beforehand) and the subcutaneous tissue of the cheek is tunneled by scissors via Bichat's fat pad, and thereafter bluntly above the masseter muscle and under the malar buttress to allow the free bony coronoid process to be grasped by Kocher tweezers and pulled with the attached temporalis tendon into the labial commissure. The tendon is dissected off the bone. The coronoid tendon of the temporalis muscle is spread out and sutured to the previous marked insertion points with non-absorbable sutures. The temporalis muscle body is slid, stretched and sutured to the aponeurotic strip that remained on the anterior portion of the temporal crest. The traction of the muscle before its fixation creates a partial overcorrection of the paralyzed side. The zygomatic arch is plated with

screws, followed by sutures and dressing of the coronal incision of the scalp.

Drains are left in place until the third postoperative day. Speech therapy to regain muscle and facial animation is begun on the 20th postoperative day. The smile is obtained by soliciting the mandibular movements that correspond to the original function of the temporalis muscle (e.g., mastication). After several sessions during 4–6 weeks, the smile appears without mobilizing the mandible and eventually allows spontaneous elevation of the oral commissure and lips, at appropriate moments, to create a symmetrical smile.

Comment

Facial reanimation is performed for patients with various etiologies of facial paralysis, including congenital, acoustic neuroma, trauma, parotid cylindroma, long-lasting Bell's palsy, etc [3]. All five patients presented here suffered facial palsy due to an excision of acoustic neuroma and were operated on by the same surgeon.

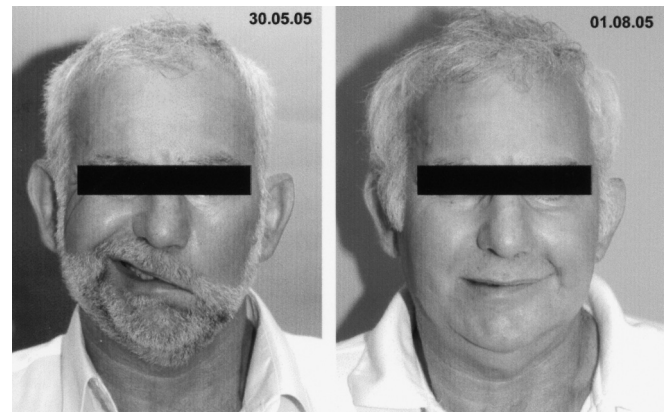
Improvement of this novel technique described by Labbé is based on anatomic study performed on fresh cadavers. The dissection showed that a 4 cm lengthening of the temporalis muscle is obtained at the expense of the posterior and upper part of the muscle above the internal raphe, omitting the need for interposition grafts.

A 5–10 month follow-up of the five patients revealed significant improvement in patients 1 [Figure], 2, 3 and 4 who reported a spontaneous smile and the complete disappearance of all preoperative complaints. Patient 5 was unable to smile, although a significant static improvement was achieved. Electromyogram and ultrasound demonstrated that the temporal muscle was functioning normally, but its insertion to the labial commissure had been dehiscenced, which prevented the creation of the smile. Resuturing the muscle's tendon with a fascia lata interposition graft to the left lip commissure corrected this problem, thus enabling a

partially spontaneous smile. None of the patients suffered infection or significant blood loss and the average hospitalization stay was 6 days.

Facial reanimation with this novel technique has several advantages. The smile is obtained in a single operation. Due to the sliding and passage of the temporalis muscle under the zygomatic arch, no anterior temporal hollow is created. The facial scar is discrete in the nasolabial crease. Cross-face nerve grafting combined with functional muscle transplantation has become the gold standard in reconstructing an emotionally controlled smile in completely irreversible facial palsy; however, this method requires at the very least two procedures with a long interval between them. The presented method can be performed immediately after the documented injury of the facial nerve (as in acoustic neuroma excision). Thanks to the retromalar and zygomatic sliding plane, the technique allows an ideal vector for physiologic traction creating a natural and symmetric smile, which is in contrast to the masseter myoplasty. The presented technique surpasses that of Gillies, which places the muscle under the skin and leads to bulkiness and adherence to the skin, creating a zygomatic bulge and cheek deformation.

The temporal myoplasty procedure is not without disadvantages however; namely, the mimic is not spontaneous and requires physical therapy with much cooperation and compliance on the part of the patient. Although emotional mimic remains problematic, two of our five patients had contraction with no mandibular movement or mastication. The technique is not indicated for patients



Patient 1: A 54 year old man with left complete peripheral facial palsy of 10 years duration due to an excision of acoustic neuroma. **Left:** Attempt to smile before surgery; **right:** smiling after surgery.

who suffered trauma to the temporalis muscle and its nerves or blood supply or had irradiation to the face. In cases of Bell's palsy it is recommended to wait for several months until the final recovery status is obtained prior to performing the myoplasty procedure. Finally, Zuker [5] commended this technique by calling it the "Rolls Royce" of regional transfer procedures. This innovative technique is now accessible for the treatment of facial palsy in Israel.

References

1. Gillies H. Experiences with fascia lata grafts in the operative treatment of facial paralysis. *Proc R Soc Med* 1934;27:1372–9.
2. McLaughlin CR. Surgical support in permanent facial paralysis. *Plast Reconstr Surg* 1953;11:302–14.
3. Labbé D, Huault M. Lengthening temporalis myoplasty and lip reanimation. *Plast Reconstr Surg* 2000;105(4):1289–97.
4. Rubin LR. The anatomy of a smile: its importance in the treatment of facial paralysis. *Plast Reconstr Surg* 1974;53:384–7.
5. Zuker RM. Lengthening temporalis myoplasty and lip reanimation. *Plast Reconstr Surg* 2000;105(4):1298.

Correspondence: Dr. Y. Har-Shai, Unit of Plastic Surgery, Carmel Medical Center, Haifa34362, Israel.

Phone: (972-4) 825-0679

Fax: (972-4) 825-0729

email: yaron07@yahoo.com

Kindness is in our power, even when fondness is not

Samuel Johnson (1709-1784), British poet, critic and lexicographer