

Catheter Ablation of Cardiac Arrhythmias Guided by Electroanatomic Imaging (CARTO): A Single-Center Experience

Mahmoud Suleiman MD, Lior Gepstein MD PhD, Ariel Roguin MD PhD, Rafael Beyar MD DSc and Monther Boulos MD

Electrophysiology and Invasive Cardiology Units, Rambam Medical Center, Haifa, Israel
Affiliated to Rappaport Faculty of Medicine, Technion-Israel Institute of Technology, Haifa, Israel

Key words: arrhythmias, ablation, non-fluoroscopic technique, CARTO mapping

Abstract

Background: Catheter ablation is assuming a larger role in the management of patients with cardiac arrhythmias. Conventional fluoroscopic catheter mapping has limited spatial resolution and involves prolonged fluoroscopy. The non-fluoroscopic electroanatomic mapping technique (CARTO) has been developed to overcome these drawbacks.

Objectives: To report the early and late outcome in patients with different arrhythmias treated with radiofrequency ablation combined with the CARTO mapping and navigation system.

Methods: The study cohort comprised 125 consecutive patients with different cardiac arrhythmias referred to our center from January 1999 to July 2005 for mapping and/or ablation procedures using the CARTO system. Forty patients (32%) had previous failed conventional ablation or mapping procedures and were referred by other centers. The arrhythmia included atrial fibrillation (n=13), atrial flutter (n=38), atrial tachycardia (n=25), ventricular tachycardia (n=24), arrhythmogenic right ventricular dysplasia (n=9), and supraventricular tachycardia (n=16).

Results: During the study period, a total of 125 patients (mean age 49 ± 19 years, 59% males) underwent electrophysiological study and electroanatomic mapping of the heart chambers. Supraventricular arrhythmias were identified in 92 patients (73 %) and ventricular arrhythmias in 33 (27%). Acute and late success rates, defined as termination of the arrhythmia without anti-arrhythmic drugs, were 87% and 76% respectively. One patient (0.8%) developed a clinically significant complication.

Conclusions: The CARTO system advances our understanding of arrhythmias, and increases the safety, efficacy and efficiency of radiofrequency ablation.

IMAJ 2007;9:260-264

other abnormal electrical circuits with radiofrequency current is termed radiofrequency ablation. RF ablation came into clinical practice at the end of the 1980s and revolutionized the way patients with arrhythmias could be treated and sometimes cured [1]. For various arrhythmias (e.g., ventricular tachycardia, atrial tachycardia, atrial fibrillation and flutter), a detailed description of the arrhythmogenic substrate and accurate electrophysiological mapping are necessary for our understanding of the ongoing arrhythmia and for successful ablation therapy. Conventional fluoroscopic catheter mapping has limited spatial resolution and may involve prolonged fluoroscopy and high ionizing radiation doses to patients and staff. In recent years, non-fluoroscopic electroanatomic mapping techniques were developed to overcome these drawbacks. The CARTO system (Biosense-Webster, Johnson & Johnson, USA) uses a mapping catheter with a localization sensor in its tip to automatically and simultaneously acquire an electrogram and determine its three-dimensional coordinates [2].

We describe this relatively new technology and report our experience with the use of this navigation and mapping system in the diagnosis and ablation of selected cardiac arrhythmias.

Patients and Methods

The study cohort comprised 125 consecutive patients with cardiac arrhythmia (atrial flutter, atrial fibrillation, atrial tachycardia, ventricular tachycardia, arrhythmogenic right ventricular dysplasia, and supraventricular tachycardia) referred to our center from January 1999 to July 2005 for mapping and/or ablation procedures using the CARTO navigation system. Forty patients (32%) had previous failed conventional ablation or mapping procedures and were referred by other centers.

Electrophysiological study

Written informed consent was obtained from all patients. Anti-arrhythmic medications, except for amiodarone, were discontinued at least 5 half-lives before the procedure, which was performed

RF = radiofrequency

For Editorial see page 326

The management of cardiac arrhythmias starts with a careful assessment of the patient and a search for a possible underlying cause. Cardiac arrhythmias most commonly result from the development of a reentry circuit caused by a myocardial scar or a developmental anomaly. Wolff-Parkinson-White syndrome is a classic example where the reentry current is due to the presence of a congenital accessory pathway. Destruction of this and any

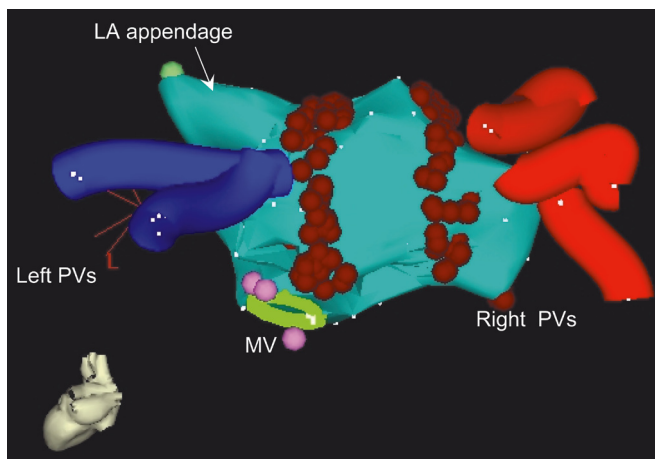


Figure 1. Anatomic map of patient treated with circumferential pulmonary vein ablation (posterior view). Brown circles show ablation lines around pulmonary vein ostia. PVs = pulmonary veins; MV = mitral valve.

in the post-absorptive state. Quadripolar catheters (6F) were positioned in the high right atrium, His bundle region, right ventricular apex, and, when necessary, in the coronary sinus. In the case of left atrial tachycardias or atrial fibrillation, a trans-septal puncture was performed using a Brockenbrough needle (USCI Angiographic Systems, Tewksbury, MA, USA) and a multipurpose sheath (8F) (Biosence-Webster, Johnson & Johnson). Body surface ECG leads VI, V3, I, II and aVF and intracardiac bipolar electrograms were recorded simultaneously by the electrophysiological laboratory system (Prucka Engineering, Houston, TX, USA). All patients had a regular electrophysiological testing protocol performed prior to the mapping and ablation procedure with the electroanatomic mapping system. If clinical arrhythmia was neither incessant nor inducible, isoprenaline at a dose of 1–4 $\mu\text{g}/\text{min}$ was infused and the stimulation protocol was repeated. In the case of left-sided arrhythmias, anticoagulation was performed by intravenous heparin administration.

Non-fluoroscopic mapping system

The CARTO electroanatomic mapping and navigation system was developed at the Technion-Israel Institute of Technology [2]. The system comprises a miniature passive magnetic field sensor, an external ultralow magnetic field emitter (location pad), and a processing unit. The locatable catheter is similar to a regular electrophysiological 8F deflectable-tip catheter. The catheter tip is mounted on the distal end of the shaft and includes the tip electrode and several additional proximal electrodes that enable recording of unipolar or bipolar signals. Just proximal to the tip electrode lies the location sensor, totally embedded within the catheter. Signals received within the sensor are transmitted along the catheter shaft to the main processing unit. The catheter is equipped with radiofrequency delivery capabilities and can be used with an ordinary radiofrequency generator. When the roving catheter is moved in three-dimensional space, its location in relation to the fixed sensor is monitored by the system, with a resolution of < 1 mm. By gating the acquisition

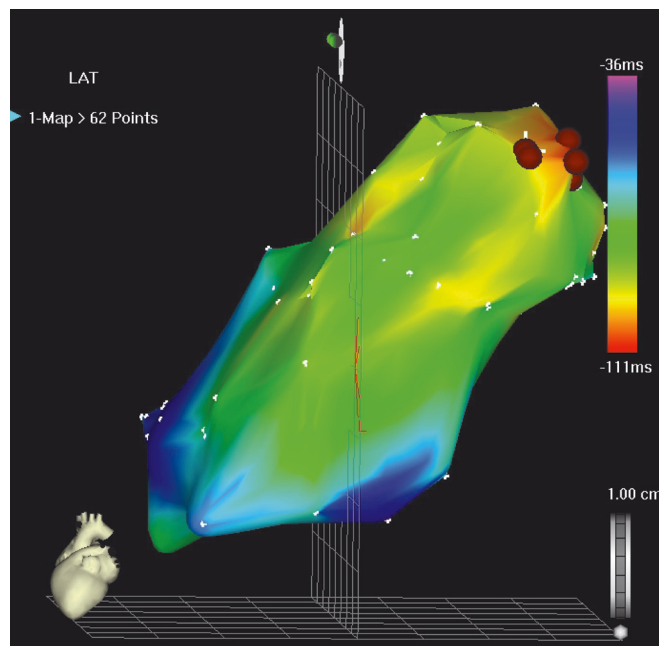


Figure 2. Left anterior oblique view of a RV electroanatomic map of patient with RVOT tachycardia acquired during tachycardia. The color-coded isochrones represent activation times during tachycardia; earliest activation times are shown in red. The brown circles represent ablation sites that terminated the arrhythmia.

of points in space to the cardiac electrical activity, points that represent both location and electrical activity at that location can be acquired and displayed on a computer screen. After acquiring a number of points, a three-dimensional representation is constructed and may be displayed from any viewing projection. Clinical applications of the system include defining the mechanisms of arrhythmias, designing ablation strategies, guiding ablations, and improving the safety of mapping and

Table 1. Clinical characteristics of the study population

	No. (percentage)
Age (mean \pm SD)	49 \pm 19
Male gender	74 (59)
Coronary artery disease	25 (20)
Congestive heart failure	15 (12)
Hypertension	28 (22)
Diabetes mellitus	17 (14)
Dyslipidemia	32 (26)
Valvular disease	15 (12)
Concomitant medications	
Class I anti-arrhythmics	30 (24)
Class III anti-arrhythmics	28 (22)
Beta-blockers	42 (34)
Calcium channel blockers	6 (5)
Repeated procedure	40 (32)
Procedure duration (min)	148 \pm 59
Fluoroscopy time (min)	10.3 \pm 6.9

Table 2. Index arrhythmia, immediate and long-term success rates

Index arrhythmia	No. of patients (%)	Successes rate* (%)	
		Acute	Late
Atrial fibrillation	13 (10)	12/13 (92)	8/13 (62)
Atrial flutter	38 (30)	35/37 (95)	33/37 (89)
Atrial tachycardia	25 (20)	15/20 (75)	13/20 (65)
RVOT tachycardia	15 (12)	12/15 (80)	11/15 (73)
LV tachycardia	9 (7)	4/7 (57)	4/7 (57)
ARVD	9 (7)	No RF ablation	
SVT	11 (9)	11/11 (100)	10/11 (91)
WPW syndrome	5 (4)	5/5 (100)	5/5 (100)

* Not all patients received RF ablation

RVOT = right ventricular out-flow tract, LV = left ventricular, ARVD = arrhythmogenic RV dysplasia, SVT = supraventricular tachycardia, WPW = Wolff-Parkinson-White.

ablation procedures by allowing localization of critical cardiac structures such as the atrioventricular node and His bundle [2,3]

Follow-up

Follow-up was conducted at the arrhythmia clinic 4 weeks after the procedure and at 3 monthly intervals thereafter, or was obtained from the referring cardiologist at the end of the study. Additional ECGs and Holter studies were obtained routinely and when patients had complaints suggestive of arrhythmia recurrence. During follow-up, patients were classified as asymptomatic (successful ablation) if they experienced no recurrence of their symptoms and no arrhythmias were recorded.

Statistical analysis

Data are expressed as mean \pm SD or frequency and percentage when appropriate. Non-continuous variables were compared by use of the chi-square statistic. A *P* value less than 0.05 was considered statistically significant. Data were analyzed using the SPSS statistical software 11.1 (SPSS, Chicago, IL).

Results

Patients' characteristics

Between January 1999 and July 2005, 125 patients underwent electrophysiological studies and electroanatomic mapping of the heart chambers. The mean age of the study population was 49 \pm 19 years (range 11–85 years) with male/female predominance (59%). The baseline and electrophysiological characteristics of the study population are presented in Table 1.

Success rates and complications

Radiofrequency ablation was applied in 108 patients and was acutely successful in 94 patients (87%). In the remaining 17 patients, RF ablation was not indicated in 9 patients with ARVD, and no significant arrhythmia could be induced in the others (1 patient with atrial flutter, 5 patients with AT and 2 patients

with VT). The outcomes for specific arrhythmias were as follows [Table 2]:

- **Atrial tachycardia:** Complete electroanatomic maps of the atria could be created in 20 of the 25 patients. In the remaining five patients the arrhythmia could not be induced to enable sufficient mapping. The success rate of ablation of AT was 80% for right atrial foci and 72% for left atrial foci.
- **Atrial fibrillation:** Complete pulmonary vein isolation could be achieved in all 13 patients. Sinus rhythm could not be restored in one patient with long-lasting permanent AF.
- **Ventricular tachycardia:** In patients with inducible or spontaneous ischemic VT (n=7), detailed endocardial CARTO mapping was performed during sinus rhythm to define areas of scar (< 0.5 mV). Linear ablation lesions were created from the scar to anatomic boundaries or normal endocardium. Short-term success was achieved in four patients (57%). In 15 patients who were undergoing ablation for right ventricular outflow tract VT, a detailed electroanatomic map of RVOT was constructed during sustained VT and/or isolated ectopic beats with the same morphology as the clinical VT. Catheter ablation was successful in 80% of the patients.

One patient had transient cerebrovascular accident following RF ablation of the pulmonary veins for AF. No other immediate or long-term significant complications were recorded.

Follow-up

After a mean follow-up of 33 \pm 22 months (range 3–86), 10 (10.6%) of the 94 patients in whom success was achieved had recurrence of the same arrhythmia. Eight patients had symptomatic arrhythmia while two patients had their arrhythmia documented by Holter study. The recurrence rate tended to be higher (11.5%) among patients with supraventricular arrhythmia as compared to patients with ventricular arrhythmias (6.2%, *P* = 0.5). The acute and long-term success rates, stratified by the index arrhythmia, are shown in Table 2.

Discussion

According to our experience and the published literature the CARTO mapping system is most useful in the diagnosis and management of the following cardiac arrhythmias: atrial tachycardia, atrial fibrillation, and some forms of ventricular tachycardia. Its role in the diagnosis and treatment of supraventricular tachycardia and atrial flutter is less well established.

Electroanatomic mapping and ablation of AT

Atrial tachycardia can result from multiple mechanisms, including ectopic atrial foci or intraatrial reentrant circuits. The latter is generally associated with underlying heart disease or other atrial arrhythmia (i.e., AF) and is usually paroxysmal in nature.

VT = ventricular tachycardia

AF = atrial fibrillation

RVOT = right ventricular outflow tract

In contrast, ectopic AT can occur in structurally normal hearts of young patients and is more likely to be incessant. In its incessant form, this tachycardia is frequently associated with the development of tachycardia-induced cardiomyopathy. There is widespread agreement that anti-arrhythmic drugs have low efficacy in the treatment of focal AT. Catheter ablation has been shown to be the treatment of choice for drug-refractory ectopic atrial tachycardia [4,5]. However, the success of catheter ablation of ectopic atrial tachycardia has been limited by the inherent difficulty of localizing the arrhythmia site of origin within the complex three-dimensional structures of the right and left atria. 3-D electromagnetic catheter technology has been reported in a small series of patients to be useful for the localization of the arrhythmogenic foci and to guide successful catheter ablation [6,7]. The present study demonstrates the clinical experience with the CARTO electroanatomic mapping system in a consecutive series of 25 patients with right or left atrial tachycardias. The success rate of ablation of AT was 80% for right atrial foci and 72% for left atrial foci.

Electroanatomic mapping and ablation of AF

Atrial fibrillation is the most common sustained arrhythmia seen in clinical practice and accounts for significant morbidity and mortality worldwide. Although pharmacological therapy with atrioventricular nodal blocking agents, anti-arrhythmics and anticoagulation are the mainstay of therapy for AF, curative therapy has recently become possible for some patients with this condition. An improved understanding of the pathophysiology and electrophysiological basis of AF coupled with the availability of better mapping techniques as well as advances in catheter technology offer promise for curative treatment. In the late 1990s, Haissaguerre et al. [8] made a critical observation that the muscle fibers associated with the pulmonary veins are an important source of ectopic beats capable of triggering AF. Many catheter techniques for control and elimination of AF have been developed over the past decade. However, a detailed description of these techniques is beyond the scope of this article. Pappone and collaborators [9] developed an electroanatomic approach using the CARTO system to map the atria and pulmonary veins aimed at isolating each pulmonary vein from the left atrium by circumferential RF lesions around their ostia [Figure 1]. The 1 year success rate, defined as freedom from AF, obtained by the Pappone group in 251 patients (179 paroxysmal AF, 72 permanent AF) was 80% overall, with 86% for paroxysmal AF and 68% for permanent AF [10]. Stabile et al. [11] conducted a multi-center prospective controlled randomized trial to investigate the adjunctive role of ablation therapy to anti-arrhythmic drug therapy in preventing AF relapses in patients with paroxysmal or persistent AF in whom anti-arrhythmic drug therapy had already failed. In contrast to the results reported by Pappone et al. [9], they reported a lower efficacy of circumferential ablation. Among 68 patients undergoing catheter ablation, 44.1% had atrial arrhythmia recurrences at 12 months follow-up. In our experience, the

efficacy of circumferential ablation of AF, free of anti-arrhythmic drugs, was 54%. An additional 8% of patients were free of AF with previously ineffective anti-arrhythmic drugs.

Despite all the technological advances, the technique is still far from perfect and stimulates research toward the development of less complex procedures. Magnetic resonance imaging and multi-slice computed tomography are non-invasive imaging modalities that can provide detailed information on the precise number, location and anatomy of the pulmonary veins and have been demonstrated to be useful in the planning of ablation procedures [12]. In experienced centers, the risk of a major complication including systemic thromboembolism, pulmonary vein stenosis, cardiac tamponade, phrenic nerve paralysis, stroke and death is approximately 4%. At the present time, AF ablation is restricted to symptomatic patients who have failed at least two anti-arrhythmic drugs, but future technical improvements based on presently applied concepts are likely to widen the indications for ablation therapy of atrial fibrillation.

Electroanatomic mapping and ablation of atrial flutter

A third type of arrhythmia that CARTO has assisted us with is typical atrial flutter that results from atrial macro-reentry, usually after a single circuit in the right atrium that circles the annulus of the tricuspid valve. RF ablation of atrial flutter is usually performed by creating an ablation line along the cavotricuspid isthmus. Creating a limited activation map, and acquiring catheter tip contact data on the medial and lateral aspects of the linear lesion during coronary sinus pacing can then prove conduction block in the cavotricuspid isthmus. The success rate of isthmus-dependent atrial flutter ablation is high (> 90%) with a low complication rate [13]. In our experience, the use of the CARTO system does not improve the success rate of atrial flutter ablation; its utility lies apparently in reducing the fluoroscopy time [14].

Electroanatomic mapping and ablation of VT

The approach to mapping and ablation of ventricular tachycardia depends on the nature of the arrhythmia substrate, which is largely determined by the underlying heart disease. The CARTO mapping system has substantially improved our understanding of ventricular arrhythmia mechanisms in patients both with and without structural heart disease. At present, ablation is considered curative and a first-line treatment only for patients with idiopathic VT or bundle branch reentry tachycardia [15]. One form of the idiopathic VT originates from the RVOT. When sufficient arrhythmia is present to permit mapping, the CARTO system can identify the area of the origination site of the tachycardia by using the activation map feature. The color-coded activation map will indicate in red the exit site of the tachycardia [Figure 2]. The RF ablation/mapping catheter can be manipulated into the red area to deliver the RF lesion. Successful ablation can be expected in 85–90% of patients, with a recurrence risk of approximately 5% [15,16].

In a recent report we demonstrated, using detailed electroanatomic mapping of the RV in patients with established ARVD (an

3-D = three-dimensional

important cause of ventricular arrhythmias and sudden cardiac death in young individuals and due to the progressive replacement of the RV musculature by fibrotic and fatty tissue), that the RV pathologic substrate in these patients can be identified, localized and quantified by the spatial association of low amplitude intracardiac electrogram reflecting replaced myocardial tissue [17]. In addition, our group recently compared the electroanatomic findings in patients with idiopathic RVOT tachycardia and patients with ARVD [18]. Electroanatomic mapping in the RVOT tachycardia group revealed normal electrogram parameters throughout the right ventricle. Hence, the regional distribution of local electrogram amplitude, duration, and amplitude/duration ratio values did not differ from the same parameters measured in the control group and in the non-affected regions in the ARVD group. In contrast, the findings in the RVOT groups were significantly different from those in the dysplastic regions in the ARVD group with the latter characterized by significantly lower voltage values, prolonged electrogram duration values, and reduced amplitude/duration ratio values. This ability to differentiate between RVOT tachycardia patients and established ARVD patients may have important diagnostic, prognostic and therapeutic implications and supports the existence of a different pathogenic mechanism underlying these two entities.

Only 10% of patients with structural heart disease and re-entrant VT actually have hemodynamically stable VT and are suitable for catheter ablation by use of conventional techniques. The CARTO system enables us to delineate scar tissue during sinus rhythm and guide linear scar-to-scar or scar-to-anatomic boundary ablation in patients with scar-related hemodynamically unstable VT. In most patients, catheter ablation is usually used as an adjunct to implantable cardioverter defibrillator and is aimed mainly at reducing the possibility of any future ICD shocks [15,19].

Conclusions

The CARTO system reduces the amount of fluoroscopy time used in treating or diagnosing clinical arrhythmias. It allows us to see, online, 3-D views without the use of fluoroscopy. The CARTO system has enabled previously incurable arrhythmias to be cured, advanced our understanding of arrhythmias, and increased the safety, efficacy and efficiency of RF ablation.

References

- Morady F. Radio-frequency ablation as treatment for cardiac arrhythmias [Review]. *N Engl J Med* 1999;340:534-44.
- Gepstein L, Hayam G, Ben-Haim SA. A novel method for non-fluoroscopic catheter-based electroanatomical mapping of the heart: in vitro and in vivo accuracy results. *Circulation* 1997;95:1611-22.
- Gepstein L, Evans SJ. Electroanatomical mapping of the heart: basic concepts and implications for the treatment of cardiac arrhythmias. *Pacing Clin Electrophysiol* 1998;21:1268-78.
- Roberts-Thomson KC, Kistler PM, Kalman JM. Atrial tachycardia: mechanisms, diagnosis, and management. *Curr Probl Cardiol* 2005;30:529-73.
- Lesh MD, Van Hare GF, Epstein LM, et al. Radiofrequency catheter ablation of atrial arrhythmias. Results and mechanisms. *Circulation* 1994;89:1074-89.
- Hoffmann E, Reithmann C, Nimmermann P, et al. Clinical experience with electroanatomic mapping of ectopic atrial tachycardia. *Pacing Clin Electrophysiol* 2002;25:49-56.
- Natale A, Breeding L, Tomasoni G, et al. Ablation of right and left ectopic atrial tachycardias using a three-dimensional nonfluoroscopic mapping system. *Am J Cardiol* 1998;82:989-91.
- Haissaguerre M, Shah DC, Jais P, et al. Spontaneous initiation of atrial fibrillation by ectopic beats originating in the pulmonary veins. *N Engl J Med* 1998;339:659-66.
- Pappone C, Rosanio S, Oreto G, et al. Circumferential radiofrequency ablation of pulmonary vein ostia. *Circulation* 2000;102:2619-28.
- Pappone C, Oreto G, Rosanio S, et al. Atrial electroanatomic remodeling after circumferential radiofrequency pulmonary vein ablation: efficacy of an anatomic approach in a large cohort of patients with atrial fibrillation. *Circulation* 2001;104:2539-44.
- Stabile G, Bertaglia E, Senatore G, et al. Catheter ablation treatment in patients with drug-refractory atrial fibrillation: a prospective, multi-centre, randomized, controlled study (Catheter Ablation For The Cure Of Atrial Fibrillation Study). *Eur Heart J* 2006;27:216-21.
- Dong J, Calkins H, Solomon SB, et al. Integrated electroanatomic mapping with three-dimensional computed tomographic images for real-time guided ablations. *Circulation* 2006;113:186-94.
- Wijetunga M, Gonzaga A, Adam Strickberger S. Ablation of isthmus dependent atrial flutter: when to call for the next patient. *Pacing Clin Electrophysiol* 2004;27:1428-36.
- Willems S, Weiss C, Ventura R, et al. Catheter ablation of atrial flutter guided by electroanatomic mapping (CARTO): a randomized comparison to the conventional approach. *J Cardiovasc Electrophysiol* 2000;11:1223-30.
- Stevenson WG. Catheter ablation of monomorphic ventricular tachycardia [Review]. *Curr Opin Cardiol* 2005;20:42-7.
- Joshi S, Wilber DJ. Ablation of idiopathic right ventricular outflow tract tachycardia: current perspectives [Review]. *J Cardiovasc Electrophysiol* 2005;16(Suppl 1):S52-8.
- Boulos M, Lashevsky I, Reisner S, Gepstein L. Electroanatomic mapping of arrhythmogenic right ventricular dysplasia. *J Am Coll Cardiol* 2001;38:2020-7.
- Boulos M, Lashevsky I, Gepstein L. Usefulness of electroanatomical mapping to differentiate between right ventricular outflow tract tachycardia and arrhythmogenic right ventricular dysplasia. *Am J Cardiol* 2005;95:935-40.
- de Chillou C, Lacroix D, Klug D, et al. Isthmus characteristics of reentrant ventricular tachycardia after myocardial infarction. *Circulation* 2002;105:726-31.

Correspondence: Dr. M. Suleiman, Electrophysiology Unit, Rambam Medical Center, Haifa 31096, Israel.
Phone: (972-4) 854-2181 Fax: (972-4) 854-2354
email: m_suleiman@rambam.health.gov.il

Intellectuals solve problems; geniuses prevent them

Albert Einstein (1879-1955), physicist and Nobel laureate