# Breast Magnetic Resonance Imaging Characteristics in Women with Occult Primary Breast Carcinoma

Sivan Lieberman MD[1], Tamar Sella MD[1], Bella Maly MD[2], Jacob Sosna MD[1], Beatrice Uziely MD[3] and Miri Sklair-Levy MD[1]

Departments of [1]Diagnostic Radiology, [2]Pathology and [3]Oncology, Hadassah-Hebrew University Medical Center (Ein Kerem Campus), Jerusalem, Israel

**Key words:** breast cancer, magnetic resonance imaging, occult primary tumor, biopsy

## Abstract

**Background:** Occult breast cancer without clinically or mammographically detectable breast tumor is an uncommon presentation.

**Objectives:** To assess the role of breast MRI in women with metastatic carcinoma and an occult primary, and to define the MRI characteristics of the primary breast tumor.

**Methods:** This retrospective study evaluated 20 women with metastatic carcinoma of unknown origin who underwent breast MRI between 2000 and 2006. Four women were excluded, leaving 16 in the study group. Probability of malignancy was assessed according to BIRADS classification. MRI performance in detecting lesions and evaluating disease extent was assessed, with the gold standard being surgical or biopsy pathology.

**Results:** MRI detected suspicious lesions in 15 patients. Lesion size ranged from 0.4 to 7 cm (median 1.5 cm). MRI detected a single lesion in 6 patients (40%), multifocal disease in 3 (20%), multicentric disease in 4 (27%), and bilateral breast lesions in 2 (13%). In 13 patients MRI depicted the primary breast cancer. Initial treatment was surgical in 9; MRI correctly estimated disease extent in 6 (67%), underestimated disease extent in 1 (11%), and overestimated it in 2 (22%). Four patients had biopsy followed by chemotherapy; one had multicentric disease and one had multifocal disease. MR findings were false positive in two patients and false negative in one.

**Conclusions:** MRI is sensitive in detecting the primary tumor and beneficial in assessing tumor extent. Small size and multiple foci are common features. We suggest that bilateral breast MRI be part of the evaluation of women with metastatic carcinoma and an occult primary.

*IMAJ 2008;10;448–452*

Breast cancer is usually detected either on routine screening mammography or by palpating a mass. Occult breast cancer presenting with distant metastatic disease or axillary lymph node metastasis without a clinically or mammographically detectable breast tumor is an uncommon presentation, accounting for less than 0.5% of all women with newly diagnosed breast cancer [1].

The use of breast magnetic resonance imaging has recently been reported for screening high risk women and for evaluating disease extent in women with known breast cancer before or after treatment [2-6]. There are several reports in the literature describing the use of MRI to locate the primary tumor site in patients with occult breast cancer [7-15]. The aims of the present study were to assess the role of breast MRI in women with metastatic carcinoma and an occult primary site, and to define the MR characteristics of breast cancer in these patients.

## Patients and Methods

This retrospective study evaluated 20 women with metastatic disease consistent with breast origin, and negative clinical and mammographic evaluation of the breasts, who underwent contrast-enhanced breast MRI between 2000 and 2006 at a single institution. Metastatic disease was found in axillary lymph nodes in 14 patients, bone in 3, supraclavicular lymph nodes in one eye globe in one and paraneoplastic syndrome in one.

Biopsy of the metastatic site was performed in 18 of the 20 women. Adenocarcinoma of probable breast origin was found in 16 patients and anaplastic carcinoma in 2. The results of immunohistochemical staining for estrogen and progesterone receptors were available in 11 patients and were positive in 7. Biopsy was not performed in a patient with an eye globe tumor and in a patient with a paraneoplastic syndrome.

Four women were excluded from the study: one had an eye globe tumor that was suspected as breast metastasis and was found to be an eye melanoma; two had suspicious enhancing lesions detected on MRI but tissue diagnosis from the breast was not obtained and the patients were lost to follow-up; and in the final patient, tissue diagnosis from the breast was not obtained before neoadjuvant chemotherapy. In this woman mastectomy following neoadjuvant chemotherapy revealed a small residual tumor in an area that correlated with the pretreatment MRI findings. The remaining 16 women thus comprised the study group. Patient age ranged from 31 to 77 years (median age 54). No patient had a prior history of malignancy.

Two senior breast radiologists with more than 5 years of experience in breast imaging reviewed all mammograms prior to the MRI study and confirmed no mammographic evidence of disease. All mammograms revealed dense breast tissue and were classified as Breast Imaging Reporting and Data System (BIRADS) 3 or 4. Eleven of the 16 patients also underwent breast sonography prior to MRI; all were negative for disease.

MRI was performed with a 1.5-T Signa system (GE Medical Systems, Milwaukee, WI, USA). The patients were imaged in the prone position, utilizing a dedicated breast coil (USA Instruments, Cleveland, OH). Sagittal T2-weighted, fat-suppressed, fast spin echo (TR/TE, 4000-5500/85-100) images of the breasts were

obtained. Sagittal three-dimensional fat-suppressed T1-weighted images (TR/TE, 6.6 -17/1.8-2.4; flip angle, 35°; bandwidth, 31.25 MHz) were then obtained before and three times after administration of 20 ml gadopentate dimeglumine (Magnevist, Schering, Berlin, Germany). Section thickness was 3 mm without a gap using a matrix of 256 x 192–256 and a field of view of 22 cm. Unenhanced images were subtracted from the contrast-enhanced images on a pixel-by-pixel basis. Maximal intensity projection reconstructions were extracted from contrast-enhanced images. All MRI exams were interpreted by one of two radiologists experienced in breast MRI and familiar with the patients' clinical histories.

Enhancing lesions were graded according to probability of malignancy using BIRADS classification [16]. Lesions considered suspicious (BIRADS 4 and 5) were defined as masses with irregular or spiculated margins, and those with heterogeneous, linear, irregular rim or segmental enhancement.

Second-look targeted ultrasonography was performed based on MRI findings. Whenever a correlating lesion was noted, ultrasound-guided core needle biopsy was performed using a previously described technique [17]. If the lesion was not identified on targeted ultrasound or if ultrasound-guided core needle biopsy was negative, and in cases where second-look targeted ultrasound was not performed, an excisional biopsy after MR-guided needle localization was performed using previously described methods [18].

We studied the correlation between MRI findings and biopsy or surgical pathology and assessed MRI performance in detecting lesions and evaluating disease extent. Descriptive statistics were used.

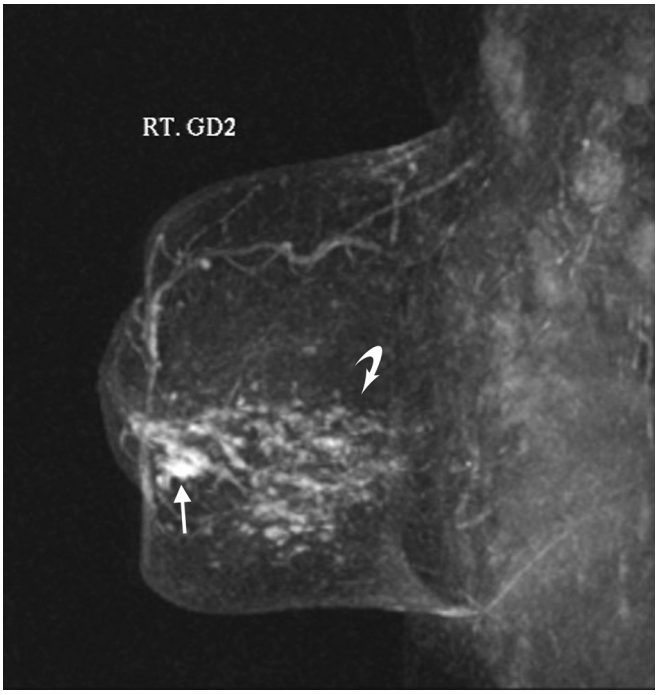


**Figure 1.** A 55 year old woman with an enlarged right axillary lymph node and fine needle aspiration cytology suspicious for breast cancer. Physical examination of the breasts, mammography and initial breast ultrasound were negative. MIP-reconstructed MR image shows a 1.6 cm ill-defined mass (arrow) with adjacent segmental enhancement involving most of the lower breast (curved arrow). Second-look targeted ultrasound demonstrated two lesions, both biopsied under ultrasound guidance and revealing DCIS.

## Results

Twenty-nine suspicious enhancing lesions were detected on MRI in 15 of the 16 patients. Lesion size ranged from 0.4 to 7 cm (median 1.5 cm). Twenty-four lesions (83%) had characteristics of malignancy (BIRADS 4 and 5) and 5 (17%) were indeterminate (BIRADS 3). Mass enhancement was found in 26 lesions and non-mass enhancement in 3 lesions. The pattern of enhancement in these three included ductal enhancement in one and segmental enhancement in two lesions [Figure 1]. A single lesion was found on MRI in 6 (40%), multifocal disease (multiple lesions in the same quadrant) in 3 (20%), multicentric disease (lesions in more than one quadrant) in 4 (27%), and bilateral breast lesions in 2 patients (13%) [Figure 2].

In 13 of the 16 patients (81%) MRI lesions were proven to be a primary breast cancer. Tissue diagnosis was obtained by ultrasound-guided biopsy in nine patients [Figure 3], MR-guided needle localization and excisional biopsy in three, and excisional biopsy with no imaging guidance in one (retroareolar MRI findings). Pathology disclosed invasive ductal carcinoma in six, mixed invasive ductal and lobular carcinoma in one, invasive ductal carcinoma with component of ductal carcinoma *in situ* in five patients, and DCIS only, in one patient. Histological tumor grade was high in six patients, intermediate in five, and low in two patients.

Initial treatment was surgical in nine patients. Mastectomy was performed in three, all with multicentric disease on MRI. Surgery confirmed multicentric disease in only one of these patients. Lumpectomy was performed in five patients. Four of them had MRI findings in one quadrant only and one patient had a single focus of enhancement in each breast and subsequently underwent bilateral lumpectomies. One patient initially had a lumpectomy, based on a solitary small focus of disease on MRI, later followed by mastectomy. In this patient, axillary lymph node dissection performed at the time of lumpectomy incidentally revealed another 3 mm focus of carcinoma in the axillary tail. This focus was not demonstrated on MRI; therefore, the MRI underestimated the extent of disease. In retrospect, we found that this area was not included in the MRI field of view.

Overall, of the 9 patients who underwent initial surgical therapy, MRI findings correctly estimated disease extent in 6 patients (67%), underestimated the extent in 1 patient (11%), and overestimated disease in 2 (22%). Four patients were treated initially with chemotherapy. Among these, multiple biopsies

BIRADS = Breast Imaging Reporting and Data System

DCIS = ductal carcinoma *in situ*

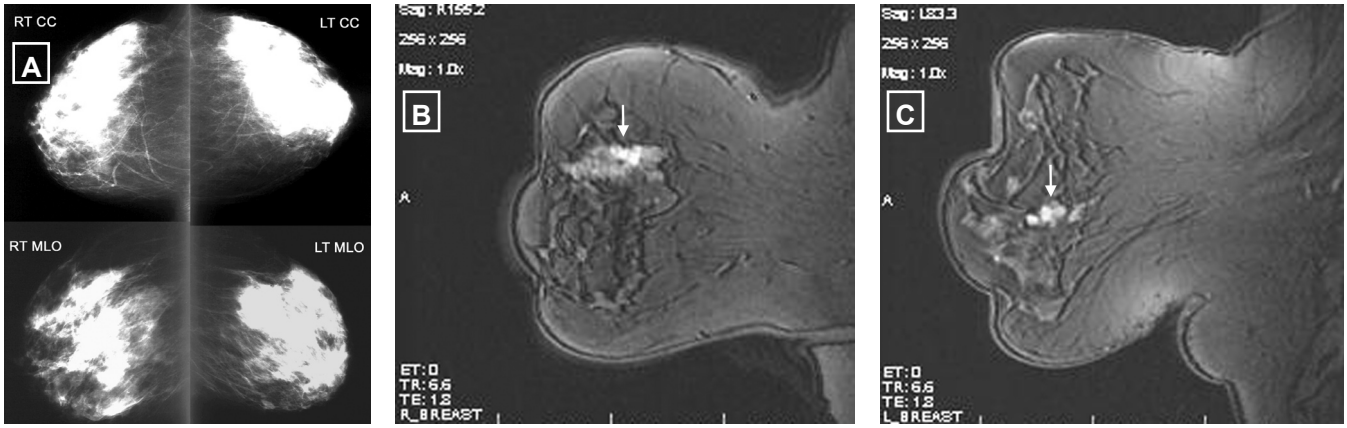


**Figure 2.** A 70 year old woman with an enlarged left axillary lymph node suspicious on fine needle aspiration cytology for breast cancer. Physical examination of the breasts was negative. Mammography **[A]** demonstrated heterogeneously dense breasts with no focal abnormality. Bilateral breast ultrasounds were negative. Contrast-enhanced T1-weighted fat-suppressed MR images showed bilateral abnormalities. In the right upper outer quadrant **[B]** note the 4 cm area of heterogeneous enhancement (arrow), and in the left lateral breast **[C]** a 2.5 cm lobulated enhancing mass (arrow). Bilateral lumpectomies revealed tubulolobular carcinoma from both sites.

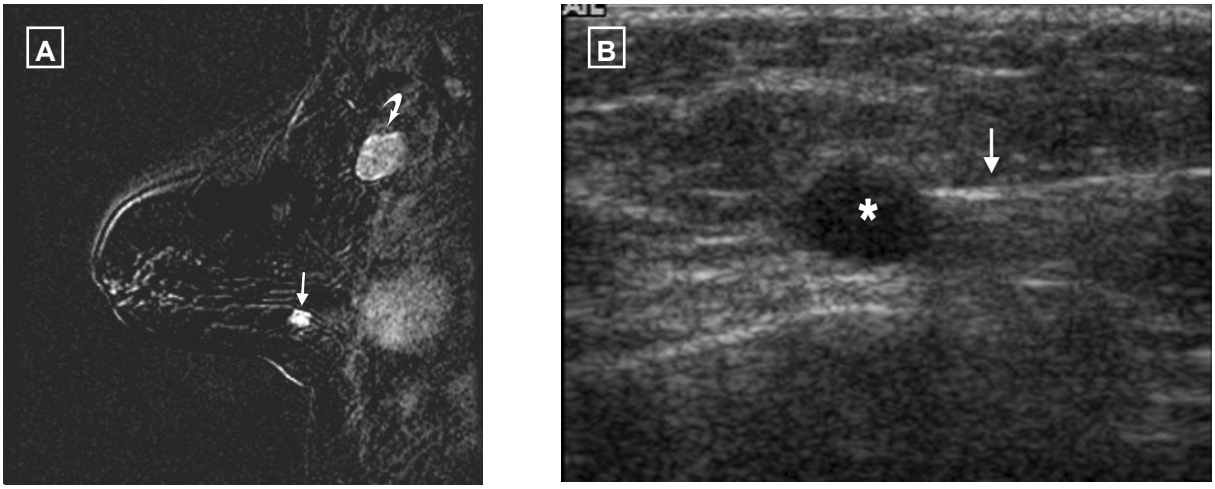


**Figure 3.** A 77 year old woman with an enlarged left axillary lymph node proven on core needle biopsy to represent metastatic breast cancer. Physical examination of the breasts, mammography and initial ultrasound of the breasts were negative. Contrast-enhanced subtracted MR image **[A]** shows a 1.2 cm mass in the left lower outer quadrant (arrow) as well as an enlarged axillary lymph node (curved arrow). **[B]** Second-look targeted ultrasound demonstrated a correlating lesion; an ultrasound-guided core needle biopsy was performed. The needle (arrow) is seen in relation to the suspicious mass (asterisk). Pathology revealed invasive duct carcinoma.

before treatment proved multicentric disease in one patient and multifocal disease in another.

In two patients biopsy of suspicious MRI lesions did not reveal tumor. One of them [Table 1, patient #15] underwent MR-guided needle localization and excisional biopsy, which did not reveal a primary breast tumor. This patient had bilateral MRI lesions graded BIRADS 3; biopsy revealed benign pathology from both (fibroadenoma on one side and fibrocystic changes on the other). The other patient [Table 1, patient #14] had an ultrasound-guided core needle biopsy of a lesion, which correlated with the MRI pathology, revealing lobular carcinoma *in situ* only. Therefore, there were two patients with false positive MRI findings

No suspicious findings on MRI were found in one patient in whom the primary breast tumor site was detected later as an area of abnormal uptake on positron emission tomography/computed tomography. A correlating lesion was subsequently located on targeted second-look ultrasound, and lumpectomy after ultrasound-guided needle localization revealed foci of low grade DCIS. Therefore, in one patient the MRI was false negative. The results of the 16 patients with metastatic disease and unknown primary site are presented in Table 1.

**Table 1.** Results of 16 patients with metastatic disease and unknown primary site

| Primary cancer site | No. of patients | MRI findings |
|---|---|---|
| Breast | 14 | True positive enhancing lesions in 13 patients<br>False negative MRI in 1 patient |
| Primary tumor site not found | 2 | False positive enhancing lesions in 2 patients |

## Discussion

MRI of the breast is a relatively expensive and not readily available examination with high sensitivity but variable low specificity, and is not routinely performed as a breast screening tool in the general population [6,19]. Women with occult breast cancer in whom the primary tumor cannot be identified on mammography or clinical examination pose a specific diagnostic problem. This group of patients may benefit from breast MRI due to its high sensitivity for detecting the primary tumor site.

Treatment of women who have isolated axillary lymph node metastasis but without a diagnosed primary site is controversial. In the past, the standard therapy was mastectomy and axillary lymph node dissection, with or without radiation therapy. It has been shown that in up to one-third of these women the tumor is not identified even at mastectomy. Moreover, the patient survival rate is not improved with mastectomy, and the prognosis of these patients is determined by the number of lymph nodes involved and by the histological tumor grade. If the primary tumor site is found, local control may be achieved by breast-conserving surgery [1,20,21]. Since MRI is known to have high sensitivity in detecting breast cancer and evaluating disease extent [2], it may play an important role in planning treatment for patients with occult axillary lymph node metastases.

In patients with remote metastatic disease of unknown origin, it is also important to locate the primary tumor site. This knowledge can provide important prognostic and therapeutic information and may provide an accessible site for biopsy, thereby enabling a targeted chemotherapy regimen. Follow-up of the primary tumor site may also serve as an indicator of disease response.

Given the importance of detecting the primary tumor site in these patients, we lowered our index of suspicion of MRI findings and included undetermined lesions (BIRADS 3) in two patients. All these lesions were found to have a benign pathology. In one of these patients no tumor was found at pathology, and in the second, disease extent was overestimated. Thus, lowering our index of suspicion led to a lower specificity. We also obtained one false negative result, which was found to be low grade DCIS at pathology. It has been shown that MRI is less sensitive to low grade DCIS than to invasive tumors [22]. We also present one case where the MRI exam underestimated disease extent and did not demonstrate a small tumor in the axillary tail; the region of this tumor was found retrospectively not to have been included in the MRI field of view. Other investigators have also reported that false negative MRI findings are very uncommon in patients with occult breast cancer [7,10,12]. Therefore, in patients with occult breast cancer, if there is no enhancing lesion on MRI the presence of invasive carcinoma is very unlikely.

In most of our patients (10 of 15) the tissue diagnosis was obtained by targeted ultrasound-guided biopsy based on the MRI findings. Obdeijn et al. [10] previously showed that targeted ultrasound-guided fine needle aspiration following MRI of the breast, with knowledge of the location of the MRI pathology, is sensitive in patients with occult breast cancer. We also found that when performed in correlation with the MRI findings, ultrasound has a high rate of detection. We recommend performing targeted ultrasound directed to the location of MRI pathology in all women with occult breast cancer and suspicious findings on MRI, even if initial sonography prior to MRI is negative. If positive, this procedure can provide a relatively easy and accessible modality for tissue diagnosis. We performed MR-guided needle localizations with subsequent surgical excision in four patients only. This method is more time consuming, expensive and uncomfortable for the patient as compared to ultrasound-guided biopsy. Furthermore, this technique requires special training and equipment. In addition, in some cases unnecessary surgery is performed. Alternatively, MR-guided biopsy could be performed in a patient with a negative second-look targeted ultrasound, eliminating the need for surgery. In our series, MR-guided biopsies were not performed due to lack of adequate equipment at the time.

In some patients biopsies of several MRI-detected lesions were performed. This is because of the low specificity of MRI for differentiating benign from malignant lesions, and the importance of accurate estimation of disease extent for treatment planning. Multiple targeted biopsies based on MRI findings helped prove more than one focus of disease in four patients in our study, and in one patient multiple biopsies revealed bilateral breast carcinoma.

Most occult cancers in this series were small (median diameter 1.5 cm). Intermediate and high histological tumor grade was common, found in 11 of 13 patients (85%) with tissue diagnosis of breast cancer. It is known that histologically low grade tumors are less likely to metastasize [23,24]. It is possible that the reason for early metastases in occult small tumors is its high grade. Another feature that was commonly observed in our patient group was the multiplicity of tumor foci within the breasts. More than one focus of disease was found on MRI and histologically proven in 6 of 13 patients (46%). This finding enhances the importance of performing MRI in patients with occult breast cancer for more accurate assessment of disease extent before treatment and for identifying multicentric and bilateral tumors. The relationship between specific tumor characteristics such as tumor size, grade and multiplicity in patients with occult breast cancer needs to be further studied.

The retrospective nature of this study is an inherent limitation that may affect the results. Some patients were lost to follow-up. Additionally, clinically and mammographically occult breast cancer is an uncommon presentation and therefore results in relatively small patient populations; the largest group published to date comprised 69 patients collected over 6 years in a large referral facility (Memorial Sloan-Kettering Cancer Center, New York), however, most articles on patients with occult breast cancer included much smaller groups, similar to ours [9,10,12,14,15].

In conclusion, this study shows that in patients with metastatic carcinoma of unknown origin breast MRI is sensitive in detecting the primary tumor site and beneficial in assessing tumor extent. Small size and multiple foci are common features. We suggest including bilateral breast MRI as part of the evaluation of women with metastatic carcinoma and an occult primary site.

## References


1. Baron PL, Moore MP, Kinne DW, Candela FC, Osborne MP, Petrek JA. Occult breast cancer presenting with axillary metastases. Updated management. *Arch Surg* 1990;125:210–14.
2. Blair S, McElroy M, Middleton MS, et al. The efficacy of breast MRI in predicting breast conservation therapy. *J Surg Oncol* 2006;94:220–5.
3. Padhani AR, Hayes C, Assersohn L, et al. Prediction of clinicopathologic response of breast cancer to primary chemotherapy at contrast-enhanced MR imaging: initial clinical results. *Radiology* 2006;239:361–74.
4. Plevritis SK, Kurian AW, Sigal BM, et al. Cost-effectiveness of screening BRCA1/2 mutation carriers with breast magnetic resonance imaging. *JAMA* 2006;295:2374–84.
5. Galinsky D, Kisselgoff D, Sella T, Peretz T, Libson E, Sklair-Levy M. Effect of breast magnetic resonance imaging on the clinical management of breast cancer. *IMAJ* 2005;7:700–3.
6. Saslow D, Boetes C, Burke W, et al. American Cancer Society guidelines for breast screening with MRI as an adjunct to mammography. *CA Cancer J Clin* 2007;57:75–89.
7. Buchanan CL, Morris EA, Dorn PL, Borgen PI, Van Zee KJ. Utility of breast magnetic resonance imaging in patients with occult primary breast cancer. *Ann Surg Oncol* 2005;12:1045–53.
8. Cisneros-Reig I, Laguna Sastre M, Alcalde Sanchez M, et al. Bilateral occult breast carcinoma: a second primary tumour or contralateral tumour metastasis? *Eur J Surg* 2001;167:312–15.
9. Henry-Tillman RS, Harms SE, Westbrook KC, Korourian S, Klimberg VS. Role of breast magnetic resonance imaging in determining breast as a source of unknown metastatic lymphadenopathy. *Am J Surg* 1999;178:496–500.
10. Obdeijn IM, Brouwers-Kuyper EM, Tilanus-Linthorst MM, Wiggers T, Oudkerk M. MR imaging-guided sonography followed by fine-needle aspiration cytology in occult carcinoma of the breast. *AJR Am J Roentgenol* 2000;174:1079–84.
11. Olson JA, Jr., Morris EA, Van Zee KJ, Linehan DC, Borgen PI. Magnetic resonance imaging facilitates breast conservation for occult breast cancer. *Ann Surg Oncol* 2000;7:411–15.
12. Orel SG, Weinstein SP, Schnall MD, et al. Breast MR imaging in patients with axillary node metastases and unknown primary malignancy. *Radiology* 1999;212:543–9.
13. Schelfout K, Kersschot E, Van Goethem M, et al. Breast MR imaging in a patient with unilateral axillary lymphadenopathy and unknown primary malignancy. *Eur Radiol* 2003;13:2128–32.
14. Schorn C, Fischer U, Luftner-Nagel S, Westerhof JP, Grabbe E. MRI of the breast in patients with metastatic disease of unknown primary. *Eur Radiol* 1999;9:470–3.
15. Tilanus-Linthorst MM, Obdeijn AI, Bontenbal M, Oudkerk M. MRI in patients with axillary metastases of occult breast carcinoma. *Breast Cancer Res Treat* 1997;44:179–82.
16. Erguvan-Dogan B, Whitman GJ, Kushwaha AC, Phelps MJ, Dempsey PJ. BI-RADS-MRI: a primer. *AJR Am J Roentgenol* 2006;187: W152–60.
17. Shulman SG, March DE. Ultrasound-guided breast interventions: accuracy of biopsy techniques and applications in patient management. *Semin Ultrasound CT MR* 2006;27:298–307.
18. Orel SG, Schnall MD, Newman RW, Powell CM, Torosian MH, Rosato EF. MR imaging-guided localization and biopsy of breast lesions: initial experience. *Radiology* 1994;193:97–102.
19. Le-Petross HT. Breast MRI as a screening tool: the appropriate role. *J Natl Compr Canc Netw* 2006;4:523–6.
20. Campana F, Fourquet A, Ashby MA, et al. Presentation of axillary lymphadenopathy without detectable breast primary (T0 N1b breast cancer): experience at Institut Curie. *Radiother Oncol* 1989;15:321–5.
21. Ellerbroek N, Holmes F, Singletary E, Evans H, Oswald M, McNeese M. Treatment of patients with isolated axillary nodal metastases from an occult primary carcinoma consistent with breast origin. *Cancer* 1990;66:1461–7.
22. Zuiani C, Francescutti GE, Londero V, Zunnui I, Bazzocchi M. Ductal carcinoma in situ: is there a role for MRI? *J Exp Clin Cancer Res* 2002;21:89–95.
23. Iwasaki Y, Fukutomi T, Akashi-Tanaka S, Nanasawa T, Tsuda H. Axillary node metastasis from T1N0M0 breast cancer: possible avoidance of dissection in a subgroup. *Jpn J Clin Oncol* 1998; 28:601–3.
24. DeVita V, Hellman S, Rosenberg S. Cancer: Principles and Practice of Oncology, 7th edn. Philadelphia: Lippincott Williams and Wilkins, 2005:1423.



**Correspondence:** Dr. S. Lieberman, Dept. of Radiology, Hadassah-Hebrew University Hospital, P.O. Box 12000, Jerusalem 91120, Israel.

Phone: (972-2) 677-6901

Fax: (972-2) 643-4434

email: sivanlieberman@hotmail.com