

Herpes Simplex Encephalitis as an Initial Presentation of Creutzfeldt-Jakob Disease

Lea Pollak MD¹, Evelyn Shabazov MD¹, Sonia Mendlovic MD² and Martin José Rabey MD¹

Departments of ¹Neurology and ²Pathology, Assaf Harofeh Medical Center, Zerifin, Israel

Key words: herpes encephalitis, Creutzfeldt-Jakob disease, possible causative interrelations

IMAJ 2008;10:392–394

Creutzfeldt-Jakob disease is the most common prion disease in humans [1]. Although the disease appears in all parts of the world, the incidence is higher among Jews of North African origin (Sephardic Jews from Libya and Tunisia). Cognitive decline or behavioral changes are usually the first presenting symptoms, whereas signs of cerebellar dysfunction, myoclonus and other neurological signs usually appear later [1]. Magnetic resonance diffusion weighted imaging studies show increased signal in the basal ganglia and/or cortex in up to 80% of established cases of the disease, but imaging can be normal at onset of the disease.

Herpes encephalitis presents as an acute febrile illness with various degrees of altered consciousness and behavioral abnormalities including hallucinations, personality changes, or a frankly psychotic state. Focal neurological deficits, seizures and myoclonus are often present and reflect the site of infection and inflammation. Whereas herpes encephalitis is usually due to herpes simplex virus-1, the type 2 herpes simplex virus causes encephalitis mainly in neonates and immunologically compromised adults [2].

We report on a patient who was initially diagnosed with herpes encephalitis and who subsequently developed histologically confirmed Creutzfeldt-Jakob disease. The possible causative interrelations of both conditions is discussed in view of some recent findings in neuroimmunology.

Patient Description

A 60 year old man of Tunisian origin, living in Israel since 1956, was admitted because of acute onset of speech disturbances, apathy and perseverations. At the age of 30 he was hospitalized for acute

psychosis and discharged after 1 month. There was no need for subsequent psychiatric therapy. He was working as a train driver and was healthy. One year before admission he was involved in a mild motor vehicle accident and suffered post-traumatic nervous instability. About 5 days before admission his behavior changed: he became apathetic, his speech was slurred and he spontaneously repeated words and phrases of people around him.

On admission he was abulic, did not speak spontaneously, and his answers were laconic with features of motor aphasia. He was able to understand and perform simple commands. There was a conspicuous verbal and gesture perseveration. The cranial nerves were intact. His muscle tone was intermittently increased (gegenhalten). There were no pyramidal, cerebellar or other focal neurological findings. The gait was normal. Elevated body temperature up to 38°C was measured during the first week of hospitalization.

Laboratory examinations, including full blood count, electrolytes, liver and renal functions, thyroid-stimulating hormone and coagulation properties were within normal limits. Blood tests for rheumatoid factor, antinuclear factor, complement 3 and 4 and serum electroimmunophoresis were normal. Vitamin B1, B12 and folic acid levels were also normal. Brain computed tomography and magnetic resonance imaging scans were normal. An electroencephalogram showed intermittent slowing above the left hemisphere. A lumbar puncture revealed 253 cells (70% of them mononuclears), elevated protein of 76 mg/dl (normal < 40 mg/dl) and a normal glucose level. A direct smear for bacteria (including *Mycoplasma tuberculosis*), yeasts and molds and cerebrospinal fluid

cultures were negative. No atypical cells or oligoclonal immunoglobulin G bands were found in the liquor. However, polymerase chain reaction was positive for herpes simplex type 2.

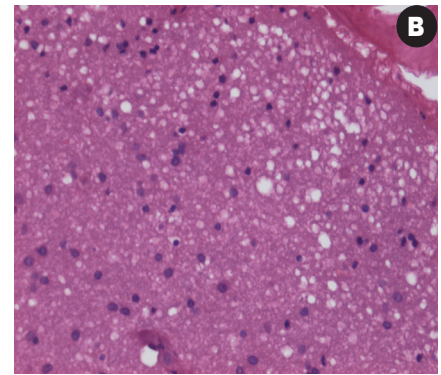
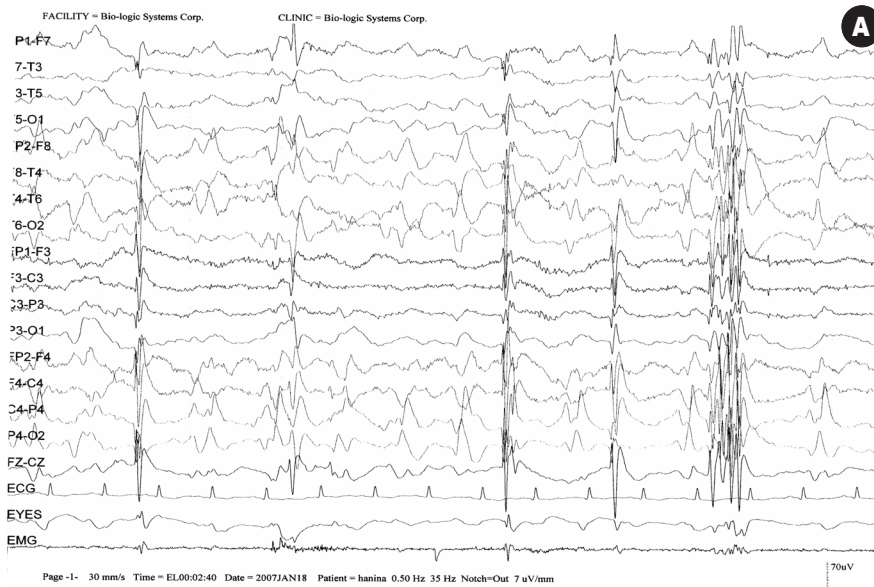Serological tests for Epstein-Barr virus, cytomegalovirus and West Nile virus were negative. Tumor markers, human immunodeficiency virus, VDRL and TPHA were negative. The CD4/CD8 index in peripheral blood smear was normal. A whole body CT scan and a transthoracic echocardiogram were normal.

Due to the finding of positive PCR for HSV-2 in the cerebrospinal fluid, herpes encephalitis was suspected and treatment with acyclovir (30 mg/kg daily) was started and continued for 21 days. Elevated anti-thyroid antibodies were detected: anti-thyroglobulin 134 IU/ml (normal < 40 IU/ml) and anti-thyroid peroxidase 75.3 IU/ml (normal < 35 IU/ml). In view of the possibility of Hashimoto's encephalopathy the patient was treated with high dose steroids.

Despite the above treatment the patient's state deteriorated rapidly. His mental state and cognitive functions worsened progressively. Initially, he had attacks of psychosis with visual hallucinations and later became mute and no contact could be made by the hospital staff or family. Severe ataxia and generalized myoclonic jerks appeared.

Serial EEGs showed generalization of slowing accentuated over the left fronto-temporal region. Over a period of some weeks, rhythmic generalized epileptiform discharges appeared, initially over the left hemisphere and later generalized with

PCR = polymerase chain reaction
HSV = herpes simplex virus



[A] Generalized epileptiform discharges (multiple spikes). Burst suppression over the left hemisphere and continuous slowing with triphasic-like waves over the right hemisphere. **[B]** Brain biopsy of the grey matter shows spongiform vacuolization of the neuropil (hematoxylin & eosin x 100).

epochs of burst suppression [Figure A]. A repeated brain MRI was normal. Two weeks after the first lumbar puncture another sample was obtained and revealed a drop in pleocytosis (48 mononuclears) with normal protein and glucose levels and negative PCR for HSV. A further CSF tap, obtained 1 month following the first lumbar puncture, was normal. Tau protein levels in the CSF were mildly elevated (300 pg/ml, normal < 230 pg/ml).

Subsequently, the patient was found to be positive for the PrP mutation on codon 200.

A brain biopsy showed spongiform changes – vacuolization, neuronal loss and gliosis, changes compatible with Creutzfeldt-Jakob disease [Figure B]. Staining for PrP was positive. No inclusion bodies or inflammatory changes attributable to viral encephalitis were found. The patient's condition deteriorated further and he became unresponsive, tetraplegic and was transferred to a nursing home where he died 1 month later.

Comment

The reported patient presented with behavioral changes and focal signs (aphasia) of acute onset. The findings of pleocytosis in the cerebrospinal fluid and PCR positive for HSV-2 prompted the diagnosis of encephalitis and acyclovir treatment, since the sensitivity and specificity of CSF PCR

are high (98% sensitivity, 94% specificity) [2]. Moreover, a normal MRI does not exclude the diagnosis since approximately 10% of patients with PCR-documented HSV encephalitis have a normal MRI.

Later, the CSF findings cleared although the clinical picture deteriorated rapidly to a severe encephalopathy with unresponsiveness, myoclonus and ataxia suggestive of Creutzfeldt-Jakob disease that was confirmed pathologically. The key question is how the two unrelated infectious diseases – Creutzfeldt-Jakob and HSV encephalitis – would be interconnected?

To the best of our knowledge only one case of concurrent HSV encephalitis and Creutzfeldt-Jakob disease has been reported [3]. In that case immunoglobulin G titers to HSV-1 were positive and acyclovir was administered for the possibility of HSV encephalitis. A transient improvement was followed by further deterioration and death.

In addition to signs of Creutzfeldt-Jakob disease, postmortem examination also demonstrated inflammatory changes. Immunocytochemical stains were positive for HSV-1, in contrast to our case where no pathological signs of inflammation were found. However, the brain biopsy in our case was performed about 2 months after completion of the antiviral therapy. The authors suggested that the disease may stimulate recrudescence of latent HSV in the CNS. Moreover, they referred to the finding of 14-3-3-protein marker for

Creutzfeldt-Jakob disease which was found to be positive at a high rate in patients with HSV encephalitis.

Conversely, HSV infection might accelerate the onset of disease in individuals with a genetic predisposition, as in our patient. Indeed, inflammation has been shown to affect the sites of PrPSc accumulation. To investigate whether an inflammatory disease influences prion pathogenesis, mice with inflammatory diseases of different organs were inoculated with prion strain. In all cases, chronic lymphocytic inflammation resulted in prion accumulation in otherwise prion-free organs and correlated with the up-regulation of lymphotoxin – a product of B lymphocytes that contributes to maturation and maintenance of cells.

A recently reported experimental work in prion-infected mice with experimental autoimmune encephalomyelitis as a model for brain inflammation resulted in an earlier fatal neurological disease in the animals, as compared with only EAE or prion-infected mice [4]. However, incubation time, disease severity and clinical symptoms did not correlate with the accumulation of PrPSc.

We would like to mention some similar EEG features of Creutzfeldt-Jakob disease and HSV encephalitis: The EEG picture of stereotyped periodic bursts

EAE = experimental autoimmune encephalomyelitis

of high voltage sharp waves occurring every 1–2 seconds in Creutzfeldt-Jakob disease closely resemble the periodic sharp and slow wave complexes at 2–3 sec intervals that are typically encountered in some patients with herpes virus encephalitis. In both conditions these changes may occur with one-side predominance and can be helpful in the diagnosis.

Hashimoto encephalitis can be a simulator of Creutzfeldt-Jakob disease. Indeed, antibodies to thyroid were found to be elevated in our patient, but steroid therapy failed. EEG changes in Hashimoto encephalitis consist of periodic discharges of triphasic waves rather than sharp polyspikes and sharp wave/slow wave polyspikes as in our patient. Furthermore, elevated thyroid antibodies are found in up to 1.8% of a clinically healthy population.

Despite the possibility of the causative interrelations between HSV en-

cephalitis and Creutzfeldt-Jakob disease discussed above, the simultaneous presence of both conditions might be purely coincidental. A recent CSF analysis of 25 patients with pathologically proved Creutzfeldt-Jakob disease revealed intrathecally synthesized antibodies against varicella-zoster virus in 2 patients and against HSV in 3 [5]. The conclusion of the study was that the findings of mild pleocytosis, oligoclonal bands and viral antibodies do not exclude the diagnosis of Creutzfeldt-Jakob disease. The most likely explanation, according to the authors, was an earlier, clinically not apparent viral infection. Release of viral DNA from dying neurons would offer an alternative explanation.

References

1. Prusiner SB, ed. Prion Biology and Diseases. 2nd edn. Cold Spring Harbor, New York: Cold Spring Harbor Laboratory Press, 2004.

2. Lakeman FD, Whitley RJ. Diagnosis of herpes simplex encephalitis: application of polymerase chain reaction to cerebrospinal fluid from brain-biopsied patients and correlation with disease. *J Infect Dis* 1995;171:857–63.
3. Brecher K, Stopa EG, Kenney K. Concurrent herpes simplex virus encephalitis and Creutzfeldt-Jakob disease. *J Neurol Neurosurg Psych* 1998;64:418–19.
4. Friedman-Levi Y, Ovadia H, Einstein O, et al. Early death of scrapie infected mice after induction of EAE. Presented at the Annual Meeting of the Israel Medical Association, Tel Aviv, December 2006.
5. Jacobi C, Arlt S, Reiber H, et al. Immunoglobulins and virus-specific antibodies in patients with Creutzfeldt-Jakob disease. *Acta Neurol Scand* 2005;111:185–90.

Correspondence: Dr. L. Pollak, 4 Kikbutz Galuyot Street, Ness Ziona 74012, Israel.
Phone: (972-8) 940-47474
Fax: (972-8) 9401995
email: lea.pollak@gmail.com