

Excessive Weight Gain as a Possible Predictor of Necrotizing Enterocolitis in Premature Infants

Iris Morag MD¹, Michael Goldman MD², Jacob Kuint MD³ and Eli Heyman MD¹

¹Neonatal Intensive Care Unit and ²Department of Pediatrics, Assaf Harofeh Medical Center, Zerifin

³Safra Hospital for Children, Sheba Medical Center, Tel Hashomer, Israel

Affiliated to Sackler Faculty of Medicine, Tel Aviv University, Ramat Aviv, Israel

Key words: necrotizing enterocolitis, very low birth weight

Abstract

Background: Necrotizing enterocolitis is a common progressive gastrointestinal disease affecting more than 5% of very low birth weight infants and associated with a high mortality rate.

Objectives: To determine whether excessive weight gain in preterm infants is an early sign of NEC.

Methods: Seventeen preterm infants with perforated NEC were identified and matched with 17 control subjects for birth weight and gestational age. The postnatal age (days) at diagnosis of NEC was identified, and weight changes as well as clinical and laboratory data were recorded and compared for 7 days prior through 7 days post-diagnosis.

Results: A significant difference in weight gain was noticed between D-1 and D 0. The NEC and control groups gained 5.1% and 1.2%, respectively ($P = 0.002$). None of the sick infants lost weight on days -1 to D 0.

Conclusions: Excessive weight gain was observed in premature infants who subsequently developed NEC. Daily evaluation of weight changes should be considered part of a strategy for early identification of infants at risk for developing NEC. Future studies are needed to confirm this finding in a prospective manner and to investigate its pathogenesis.

IMAJ 2007;9:24–27

Necrotizing enterocolitis is a common progressive gastrointestinal disease affecting more than 5% of very low birth weight infants and associated with a high mortality rate of 20%–35% [1]. Premature birth, feeding, bacterial colonization and ischemia of the bowel mucosa are considered to be risk factors [1-4]. The diagnosis of NEC is based on clinical, laboratory and radiologic signs. Clinical signs of NEC are abdominal distention, feeding intolerance with increased gastric residuals, emesis, blood in the stools, and diarrhea [5]. These signs are non-specific and may be present in other gastrointestinal disorders common in premature infants. Laboratory findings correlate with those of sepsis: thrombocytopenia, leukopenia or leukocytosis, glucose instability, metabolic acidosis and hyponatremia, as well as other electrolyte disturbances [6]. As the disease progresses, more specific clinical and radiologic features appear [7-9]. Early recognition and prompt treatment may prevent further deterioration, thus avoiding bowel perforation and decreasing long-term morbidity and mortality [10,11]. In the present study we hypothesized, based on clinical

observation, that excessive weight gain is a consistent early sign in infants who develop NEC.

Patients and Methods

Patients

In this retrospective case-control study we reviewed the charts of all consecutive preterm infants born weighing less than 33 weeks gestational age at birth who were admitted to the neonatal intensive care units at Assaf Harofeh and Sheba Medical Centers between January 1990 and December 2002 and were diagnosed with perforated NEC (Bell's stage III) [9]. Infants with non-perforated NEC were excluded from the study in order to prevent the possible bias of false diagnosis. Other exclusion criteria were thrombocytopenia at birth (platelets $< 100 \times 10^9/L$), congenital cardiac malformation, and spontaneous bowel perforation. Twenty-one infants with perforated NEC were identified. Four patients were excluded from the study at the time of data collection due to lack of weight measurements. Seventeen had perforated NEC documented on pathologic specimens obtained at the time of surgery or autopsy. Seventeen control subjects born during the same period were selected and matched by gestational age (± 3 days) and birth weight ($\pm 1-3\%$). Each case was matched with the very next control subject who met the above criteria. The day that NEC was clinically diagnosed was recorded as day 0 in the NEC group and in the corresponding control group.

Data collection

The data extracted from the infants' medical records included gestational age, birth weight and gender. Laboratory data, weight changes, total daily fluid volume, and volume of feeds were recorded for a 2 week period beginning 1 week prior to the diagnosis of NEC and continuing through the week following the diagnosis (D-7 to D+7). Other neonatal co-morbidities that may affect weight, such as antenatal steroids, chorioamnionitis, Apgar scores, cord blood gases, and pharmacological treatment for patent ductus arteriosus were extracted. Arterial blood gas, electrolyte and blood count were measured twice a week in stable preterm infants, and daily in those infants diagnosed with NEC. Perforation was diagnosed according to both clinical and radiographic criteria [9], and confirmed at the time of surgery or autopsy.

NEC = necrotizing enterocolitis

Concomitant treatment

During the study period, in keeping with the routine at our institution, fluids were started at 80 ml/kg/day and increased by 20 ml/kg/day to a maximum of 160 ml/kg/day. Enteral feedings were started as soon as the infants were hemodynamically stable. Feeding was started at 1–3 ml every 3 hours and if well tolerated was increased by 2 ml every 24 hours to a maximum of 160 ml/kg/day. Infants were weighed daily by night-shift nurses using the same scale for each infant.

For treatment of respiratory distress syndrome, infants received respiratory support (conventional or high frequency ventilation), oxygen supplements, and surfactant. Prophylactic antibiotics were administered from admission to the neonatal intensive care unit and stopped after 48 hours if blood cultures were negative. Following the clinical diagnosis of NEC, feeds were discontinued and an orogastric tube was inserted. Parenteral nutrition and broad-spectrum systemic antibiotics were initiated. Frequent blood work was performed with the aim of correcting electrolyte disturbances, metabolic acidosis and coagulopathy. Repeat abdominal X-rays were taken. Perforation, diagnosed according to clinical and radiologic criteria [9], was treated by surgical resection or peritoneal drainage, depending on the infant's condition and the surgeon's decision. The study was approved by the Institutional Review Board.

Statistics

Data were analyzed with SPSS software version 11.0. Baseline characteristics and comparisons between the two matched case-control groups were conducted by paired *t*-tests for continuous variables and McNemar tests for categorical variables. Progressions of weight, platelets and sodium were measured by means and standard deviation and were compared using analysis of variance with repeated measures analysis.

Results

Thirty-four infants met the study criteria, 17 each in the study and control groups. Patient characteristics at birth and the frequency of common neonatal complications were similar [Table 1]. In both groups feeds were introduced between the 2nd and the 11th day of life (mean 5th day). The total daily fluid intake in the two groups was similar on day -7 to day 0. NEC was diagnosed at a mean age of 19 ± 11 days (range 5–38 days), and perforation occurred at a mean of 2.4 days later (range 0–7 days following the initial diagnosis of NEC). While the overall weight gain was similar in both groups, the pattern of weight gain was different [Figure 1]. On D-7 to D-1, and D 0 to D+7, there was no difference between the groups. On D-1 to D 0, however, the NEC group gained 5.1% while the control group gained 1.2% ($P = 0.002$) [Table 2]. None of the infants in the NEC group lost weight on day -1 to D 0.

Platelet counts at birth and D-7 through D 0 were similar in the groups. Significant thrombocytopenia ($< 100,000$) developed in the NEC group after day 0 and reached a nadir on day +4. This was in contrast to the normal platelet count in the control group ($P = 0.001$). Hyponatremia ($\text{Na} < 135$)

Table 1. Clinical and laboratory characteristics

	NEC (n=17)	Control (n=17)
Gender (female)*	9 (52.9%)	10 (58.8%)
Gestational age (wk)	27.8 ± 2.6	27.8 ± 2.3
Birth weight (g)	1018 ± 316	1019 ± 318
Apgar 1 minute	6.1 ± 2.4	6.3 ± 2.6
Apgar 5 minutes	8.4 ± 1.5	8.2 ± 1.5
Cord pH	7.35 ± 0.061	7.33 ± 0.064
Respiratory distress syndrome	12 (70.6)	13 (76.5)
Indomethacin for patent ductus arteriosus	9 (52.9)	7 (41.2)
Antenatal steroids**	10 (58.8)	16 (94.1)
Mechanical ventilation	14 (82.4)	11 (64.7)
Intraventricular hemorrhage grade > 1	6 (35.2)	5 (29.4)
First feeding (days)	5.0 ± 2.4	4.6 ± 2.0

* Categorical variables are presented as frequency and percentage, and numerical variables are presented as mean \pm standard deviation.

**None of the variables demonstrated a statistically significant difference between the two groups excluding that of antenatal steroids ($P > 0.10$).

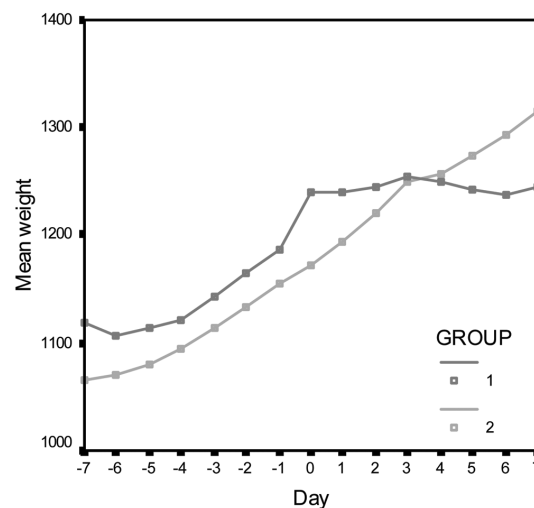


Figure 1. Progression in weight gain (in grams) the week before through the week following the diagnosis of NEC. Group 1 = NEC patients, Group 2 = control

was detected on D 0 and continued to D+4 in the NEC group alone.

Discussion

Necrotizing enterocolitis is the most serious acquired gastrointestinal disease in the preterm infant. Diagnosis is based on clinical, laboratory and radiologic signs according to the modified Bell criteria [9]. Once NEC is definitively diagnosed (stage II or higher), little can be done to alter the course of the disease [12]. The mortality rate is 20–35%, and the long-term gastrointestinal and neurologic morbidity is high [13,14]. Ischemia is probably the final common pathway of inflammatory response initiated by feeding and bacterial toxins in the gut of premature infants.

Table 2. Weight changes in the week before and the week after the diagnosis of NEC

Age	Weight change (%)		P
	NEC group	Control group	
Day -7 to -6	-0.3	0.3	0.339
Day -6 to -5	0.8	1.0	0.706
Day -5 to -4	0.6	1.2	0.547
Day -4 to -3	0.9	1.2	0.759
Day -3 to -2	1.6	1.8	0.842
Day -2 to -1	1.4	1.7	0.686
Day -1 to 0	5.1	1.2	0.002
Day 0 to +1	0.9	1.8	0.485
Day 1 to +2	2.5	1.5	0.548
Day 2 to +3	0.7	1.7	0.352
Day 3 to +4	1.1	0.0	0.546
Day 4 to +5	1.5	1.4	0.894
Day 5 to +6	0.5	1.3	0.657
Day 6 to +7	1.2	1.6	0.712

Stage I NEC lacks definitive objective criteria for its identification and a high index of suspicion is therefore required for diagnosing infants presenting without significant gastrointestinal symptoms. Over-diagnosis on the other hand, based on abdominal distention and gastric residuals of one or two feeds ("medical NEC") – common events in premature infants – may lead to unnecessary cessation of feeds and initiation of systemic antibiotics [15]. A combination of a high index of suspicion and early diagnostic tools are required, therefore, to avert over- or under-diagnosis. In the present study we detected one such possible tool: significant weight gain between D-1 and D 0 in preterm infants who subsequently developed NEC.

In both groups the rate of weight gain was 1–2% of the previous weight per day. This rate is consistent with the normal weight gain expected in preterm infants. The control group continued to gain weight in the same rate throughout all the days of data collection, whereas the NEC group gained 5% of the previous weight between D-1 and D 0. None of the infants in the NEC group lost weight on day -1 to D 0, and this may serve as a negative predictor.

Following the diagnosis of NEC we observed a flat tendency of weight gain in the NEC group [Figure 1]. This was probably secondary to discontinuation of feeds. Cobb et al. [16] demonstrated that very low birth weight infants who developed NEC had an increased amount of gastric residuals. In our study there was a trend of slower weight gain on D-6 to D-3 [Figure 1] in the NEC group. This finding, while not statistically significant, is consistent with Cobb's findings and may be secondary to increased gastric residuals.

In our department weight is measured daily by the night-shift nurses, using the same scale for each infant. Preterm infants who are less than a month old and who gained excessive weight are considered to be at high risk for developing NEC. If other known clinical or laboratory signs develop, early treatment is initiated.

Several pathophysiologic mechanisms may explain early

weight gain in NEC. One possible etiology is the capillary leak syndrome, which represents the result of capillary fluid loss into a third space caused by a deleterious increase in capillary permeability. CLS is defined as a combination of generalized edema, significant weight gain, tachycardia, and arterial hypotension necessitating catecholamines [17-19]. Sonntag and co-authors [20] found that of 50 infants with NEC 10 had CLS. All infants who presented with CLS required surgical treatment and eight of them died later. Salat and team [17] provided supporting evidence for the relation between complement activation and CLS. Animal studies have propagated the ongoing injury to the intestinal mucosa, which in turn triggers a cascade of inflammatory events [21,22]. This inflammatory response, consisting of leukocyte adhesion and activation, complement activation and release of other cytokines, results in areas of focal necrosis. Other possible explanations for weight gain accompanied by hyponatremia are the syndrome of inappropriate antidiuretic hormone secretion, congestive heart failure, and renal insufficiency. While one may speculate that the reason for weight gain in the NEC group was related solely to sepsis (six patients in the NEC group had a positive blood culture), to the best of our knowledge no study has demonstrated this association. Significantly, the differences in the pattern of weight gain between the two groups were not related to differences in the severity of the sickness of the NEC infants [Table 1] or to differences in fluid management.

There are several limitations in this study. First, it is a retrospective study with a relatively small number of patients. Another limitation results from including only infants with perforated NEC. Thus, a possible correlation between the percent of weight gain and the extent of disease could not be evaluated. Finally, we did not investigate the pathophysiologic mechanisms and therefore we can only speculate that CLS was the cause of the hyponatremia and weight gain.

In conclusion, excessive weight gain was observed on the day prior to the diagnosis of NEC in preterm infants compared with control subjects. We suggest that careful monitoring of weight may help in the early diagnosis of NEC. Future prospective studies are needed to confirm this finding and to investigate its pathogenesis.

References

1. Kliegman RM, Walker WA, Yolken RH. Necrotizing enterocolitis: research agenda for a disease of unknown etiology and pathogenesis. *Pediatr Res* 1993;34:701–8.
2. Kliegman RM. Models of the pathogenesis of necrotizing enterocolitis. *J Pediatr* 1990;117:S2–5.
3. Kosloske AM. Epidemiology of necrotizing enterocolitis. *Acta Paediatr Suppl* 1994;396:2–7.
4. Touloukian RJ, Posch JN, Spencer R. The pathogenesis of ischemic gastroenterocolitis of the neonate: selective gut mucosal ischemia in asphyxiated neonatal piglets. *J Pediatr Surg* 1972;7:194–205.
5. Kliegman RM, Fanaroff AA. Necrotizing enterocolitis. *N Engl J Med* 1984;310:1093–103.
6. Hutter JJ, Hathaway WE, Wayne ER. Hematologic abnormalities in severe neonatal necrotizing enterocolitis. *J Pediatr* 1976;88:1026–31.

CLS = capillary leak syndrome

7. Daneman A, Woodward S, de Silva M. The radiology of neonatal necrotizing enterocolitis (NEC). A review of 47 cases and the literature. *Pediatr Radiol* 1978;19:70–7.
8. Bell MJ, Ternberg JL, Feigin RD, et al. Neonatal necrotizing enterocolitis. Therapeutic decisions based upon clinical staging. *Ann Surg* 1978;187:1–7.
9. Walsh MC, Kliegman RM. Necrotizing enterocolitis: treatment based on staging criteria. *Pediatr Clin North Am* 1986;33:179–201.
10. Brown EG, Sweet AY. Preventing necrotizing enterocolitis in neonates. *JAMA* 1978 240:2452–4.
11. Foglia RP. Necrotizing enterocolitis. *Curr Probl Surg* 1995;32:757–823.
12. Lee JS, Polin RA. Treatment and prevention of necrotizing enterocolitis *Semin Neonatol* 2003;8:449–59.
13. Tobiansky R, Lui K, Roberts S, Veddovi M. Neurodevelopmental outcome in very low birthweight infants with necrotizing enterocolitis requiring surgery. *J Paediatr Child Health* 1995;31:233–6.
14. Sonntag J, Grimmer I, Scholz T, Metze B, Wit J, Obladen M. Growth and neurodevelopmental outcome of very low birth weight infants with necrotizing enterocolitis. *Acta Paediatr* 2000;89: 528–32.
15. Jobe AH. Feed the infant with NEC. *J Pediatr* 2003;143:484.
16. Cobb BA, Carlo WA, Ambalavanan N. Gastric residuals and their relationship to necrotizing enterocolitis in very low birth weight infants. *Pediatrics* 2004;113:50–3.
17. Salat C, Holler E, Schleuning M, et al. Levels of the terminal complement complex, C3a-desArg and C1-inhibitor in adult patients with capillary leak syndrome following bone marrow transplantation. *Ann Hematol* 1995;71:271–4.
18. Hack CE, Ogilvie AC, Eisele B, Eerenberg AJ, Wagstaff J, Thijs LG. C1-inhibitor substitution therapy in septic shock and in the vascular leak syndrome induced by high doses of interleukin-2. *Intensive Care Med* 1993;19(Suppl 1):S19–28.
19. Nurnberger W, Gobel U, Stannigel H, Eisele B, Janssen A, Delves U. C1-inhibitor concentrate for sepsis-related capillary leak syndrome. *Lancet* 1992;339:990.
20. Sonntag J, Wagner MH, Waldschmidt J, Wit J, Obladen M. Multisystem organ failure and capillary leak syndrome in severe necrotizing enterocolitis of very low birth weight infants. *J Pediatr Surg* 1998;33:481–4.
21. Claud EC, Walker WA. Hypothesis: inappropriate colonization of the premature intestine can cause neonatal necrotizing enterocolitis. *FASEB J* 2001;15:1398–403.
22. Hsueh W, Caplan MS, Tan X, MacKendrick W, Gonzalez-Crussi F. Necrotizing enterocolitis of the newborn: pathogenetic concepts in perspective. *Pediatr Dev Pathol* 1998;1:2–16.

Correspondence: Dr. M. Goldman, Dept. of Pediatrics, Assaf Harofeh Medical Center, Zerifin 70300, Israel.

Phone: (972-8) 779-34

Fax: (972-8) 977-9136

email: mgoldman@walla.co.il