

Propofol Infusion Syndrome: a Rare Cause of Multi-Organ Failure in a Man with Complicated Myocardial Infarction

Avi Shimony MD¹, Yaniv Almog MD² and Doron Zahger MD¹

¹Department of Cardiology Intensive Cardiac Care Unit and ²Medical Intensive Care Unit, Soroka University Medical Center and Faculty of Health Sciences, Ben-Gurion University of the Negev, Beer Sheva, Israel

Key words: propofol, myocardial infarction, rhabdomyolysis

IMAJ 2008;10:316–317

Patients who are admitted to the cardiac care unit with acute coronary syndromes occasionally require prolonged mechanical ventilation, as do many patients who have sustained out-of-hospital cardiac arrest. These patients typically require sedation, which is often carried out with the widely used anesthetic drug propofol.

Propofol infusion syndrome is a rare syndrome consisting of rhabdomyolysis, metabolic acidosis, hyperlypemic plasma, acute renal failure, congestive heart failure and conduction abnormalities. It was first described in 1992 by Parke et al. [1] in children. Since then, this unexpected serious complication has been reported in adults, mostly those with traumatic head injury; however, this syndrome had not been described in patients with acute myocardial infarction or in survivors of cardiopulmonary resuscitation [2-6]. We describe for the first time a case of PRIS in a patient who was admitted to the cardiac care unit after cardiopulmonary resuscitation and ST elevation myocardial infarction.

Patient Description

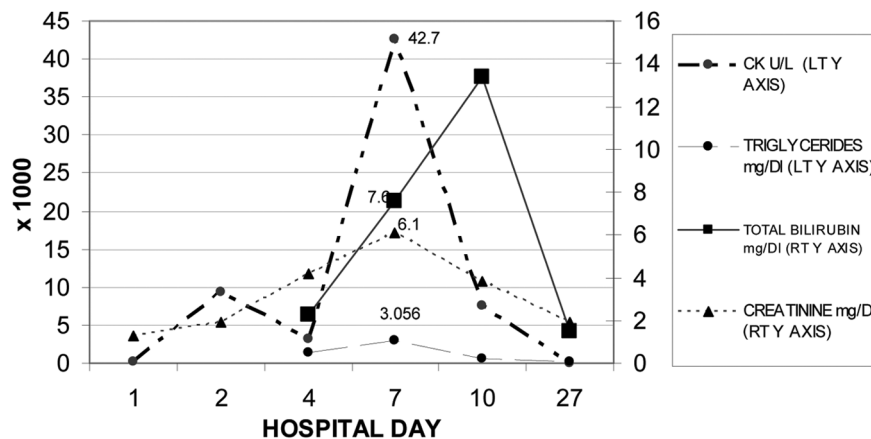
A 52 year old previously healthy man was admitted to our hospital after out-of-hospital cardiac arrest. Apart from smoking he had no risk factors for coronary artery disease. The patient collapsed in a shopping center without prior symptoms and a few minutes later paramedics found him in ventricular fibrillation and administered defibrillation and advanced cardiac life support. He was brought to the emergency department intubated and sedated. The electrocardiogram revealed anterior wall

ST elevation and the patient underwent successful primary stenting of an occluded proximal left anterior descending coronary artery. An intra-aortic balloon pump was inserted due to hemodynamic instability.

Echocardiography revealed severe left ventricular dysfunction. On admission to the cardiac care unit the patient was given atracium and propofol and induced hypothermia was initiated using external cooling for 24 hours. After discontinuation of hypothermia and sedation the patient became extremely agitated; propofol was therefore resumed and continued at a dose of 400 mg/hour for 7 days. The patient improved gradually with initial resolution of some of the laboratory abnormalities (creatinine kinase from 9432 U/L to 3148 U/L and aspartate aminotransferase from 896 to 349 U/L on the sixth day). However, on the seventh hospital day the patient developed hemodynamic instability, profound hyperbilirubinemia (total bilirubin up to 13.4 mg/dl with direct

bilirubin reaching 7.3 mg/dl), elevated liver enzymes (alanine aminotransferase up to 206 U/L and aspartate aminotransferase up to 828 U/L), progressive renal failure and rhabdomyolysis (creatinine up to 7.6 mg/dl and creatine kinase up to 42,700 U/L), metabolic acidosis (bicarbonate 14.4 mmol/L) and a hyperlypemic plasma (triglycerides up to 3050 mg/dl) [Figure]. Echocardiography was unchanged.

The combination of acute renal failure, rhabdomyolysis, bilirubinemia and triglyceridemia in a patient receiving high dose propofol led us to suspect the propofol infusion syndrome. The patient was transferred to the medical intensive care unit. Propofol was replaced by midazolam and continuous veno-venous hemodiafiltration was initiated. Metabolic abnormalities gradually subsided, renal failure completely resolved, and after 3 weeks the patient was weaned off mechanical ventilation and decannulated. He demonstrated some residual anoxic brain



Laboratory data during hospitalization. Propofol was initiated on day 1 and replaced on day 7 by midazolam. Left Y axis shows creatine kinase and triglyceride levels (x 1000). Right Y axis shows total bilirubin and creatinine levels.

PRIS = propofol infusion syndrome

damage but had normal bilirubin, creatine kinase, pH and triglyceride levels, and the creatinine was 1.56 mg/dl. The patient was then moved to a rehabilitation center.

Comment

Propofol is an alkylphenol (2, 6-diisopropylphenol). Its exact mechanism of action is unclear, although it is thought to act at the GABA receptor. It is oil at room temperature and is prepared as a lipid emulsion. The drug is widely used for induction and maintenance of anesthesia or sedation, particularly when a short-term effect is desired. Its rapid onset of action and short half-life make it advantageous for patients who need frequent evaluation. It was approved for mechanically ventilated adults in 1993 and has since had a good safety profile [2].

PRIS is a rare, severe, often lethal complication of propofol. It has mainly been reported in children (leading to a substantial decline in the use of this agent in pediatric intensive care units [3]) and less frequently in adults, especially when high doses (> 80 µg/kg/min) are used. PRIS is characterized by renal, cardiac and hepatic failure, rhabdomyolysis, metabolic acidosis, dysrhythmias, hemodynamic instability and hyperlypemic plasma [4,5] – the latter probably reflecting lipid load as the propofol formulation is highly lipid soluble. The syndrome develops most commonly after a few days of high dose propofol infusion (> 5 mg/kg/hr). Since reports of this complication are sporadic, it is difficult to characterize a specific risk profile. However, it has been described in association with neurological dysfunction, trauma, sepsis and severe burns [5].

This is the first report of PRIS complicating acute myocardial infarction

and cardiopulmonary resuscitation. We hypothesize that the multi-organ dysfunction and the ensuing shock state in our patient might have set the context for the development of PRIS.

PRIS has a complex and incompletely understood pathophysiology [3-5]. At the cellular level propofol impairs free fatty acid utilization and mitochondrial activity. It uncouples oxidative phosphorylation, impairs the mitochondrial respiratory chain, and diminishes cardiac performance by acting on cardiac calcium channel receptors. In critically ill patients with severe sepsis or circulatory shock, oxygen supply and delivery are often diminished, making free fatty acid an important energy source. Propofol-induced inhibition of free fatty acid utilization may render cardiac and skeletal muscles susceptible to ischemia and necrosis. Therefore, an imbalance between energy requirements and supply may play a key role in the pathophysiology of muscle necrosis and cardiac failure. Factors such as acute brain injury, systemic inflammatory cytokine production, multi-organ failure, sepsis and use of catecholamines may all increase metabolic needs, further aggravating the propofol-induced imbalance between energy requirements and production. A genetic preponderance for the syndrome has been suggested [4].

Early diagnosis of PRIS is of paramount importance. Management consists of immediate discontinuation of the drug and supportive care. Sepsis, hypoperfusion and hypoxia should be treated vigorously. It might be necessary to limit nutritional lipid load. Physicians using propofol for sedation, particularly in high doses, should be aware of this rare but severe complication, as a delay in diagnosis and

continued propofol administration may prove fatal. Unexplained clinical deterioration associated with metabolic acidosis, rhabdomyolysis, renal failure hyperlypemic plasma and hypertriglyceridemia should alert the clinician that PRIS might be evolving. Once suspected, propofol infusion should be immediately stopped. Since hyperlypemia might be the first clue of impending PRIS, it is prudent to monitor triglyceride levels in patients receiving continuous propofol infusion as it may facilitate early diagnosis of this serious complication [4].

References

1. Parke TJ, Stevens JE, Rice AS, et al. Metabolic acidosis and fatal myocardial failure after Propofol infusion in children: five case reports. *BMJ* 1992;305:613–16.
2. Sabsovich I, Rehman Z, Yunen J, Coritsidis G. Propofol infusion syndrome: a case of increasing morbidity with traumatic brain injury. *Am J Crit Care* 2007; 16:82–5.
3. Fudickar A, Bein B, Tonner PH. Propofol infusion syndrome in anesthesia and intensive care medicine. *Curr Opin Anaesthesiol* 2006;19:404–10.
4. Ahlen K, Buckley CJ, Goodale DB, Pulsford AH. The Propofol infusion syndrome: the facts, their interpretation and implications for patient care. *Eur J Anaesthesiol* 2006;23:990–8.
5. Vasile B, Rasulo F, Candiani A, Latronico N.. The pathophysiology of Propofol infusion syndrome: a simple name for a complex syndrome. *Intensive Care Med* 2003;29:1417–25.

Correspondence: Dr. A. Shimony Dept. of Cardiology Intensive Cardiac Care Unit, Soroka University Medical Center, P.O. Box 151, Beer Sheva 84101, Israel.
Phone: (972-8) 640-0418
Fax: (972-8) 628-2112
email: ashimony@bgu.ac.il