Late Relapse of Hodgkin's Lymphoma Presenting as Fatal Hematemesis Caused by an Esophago-Tracheo-Arterial Fistula

Michael Kutchuk MD[1], Yevgeny Edelstein MD[2] and Martin H. Ellis MD[3]

Departments of [1]Pulmonology and [2]Pathology, and [3]Hematology Unit, Meir Medical Center, Kfar Saba and Sackler Faculty of Medicine, Tel Aviv University, Ramat Aviv, Israel

KEY WORDS: Hodgkin's lymphoma, fistula, hemorrhage

IMAJ 2009;11:637–638

Lymph nodes involved by Hodgkin's lymphoma typically displace and compress structures as they enlarge, unlike carcinomatous nodes that typically have a destructive and tissue-invasive growth pattern. In this paper we describe a case of late relapse of nodular sclerosis classical Hodgkin's lymphoma presenting with a rapidly fatal complication caused by tissue invasion.

PATIENT DESCRIPTION

A 36 year old woman presented to the emergency department with dyspnea, cough, purulent sputum and vomiting. Ten years earlier she had been diagnosed with nodular sclerosis classical Hodgkin's lymphoma stage IIB. On admission she had bilateral axillary adenopathy and an 8 cm mediastinal mass that was not separable from the heart on computed tomography. The left main bronchus was entrapped in the tumor and a large pericardial effusion was present. She received combined modality treatment comprising mantle irradiation (3600 cGy) and four courses of combination chemotherapy consisting of adriamycin, bleomycin, vinblastine and dacarbazine (ABVD). After completing treatment a CT scan revealed a residual mediastinal mass of 3–4 cm diameter that was not gallium avid and she was assessed as being in complete remission. She was observed clinically every 6 months and by CT scan every 1–2 years over the subsequent 9 years. She demonstrated no evidence of relapse, nor did she develop any complications of treatment. Her last clinic visit was a year prior to the current hospitalization.

Symptoms began a few days prior to hospitalization, and she was treated with amoxycillin for a presumed upper respiratory tract infection. She presented to the emergency department 2 days later because of persistent cough. On examination her temperature was 37.5^{0}C and she had a purulent postnasal drip. Fiberoptic sinus examination revealed evidence of acute sinusitis. Chest X-ray showed a right upper lobe lung shadow, a widened mediastinum and shifting of the trachea to the right. The patient was admitted for intravenous antibiotic administration and for further evaluation of the X-ray finding.

Twelve hours afer admission she developed sudden massive hematemesis leading to hemorrhagic shock. Attempts at resuscitation were unsuccessful and she died within 1 hour of the onset of hematemesis.

An autopsy was performed. Macroscopic examination revealed a mediastinal mass measuring 9 x 8 x 7 cm, extending into the apex of the left lung and left supraclavicular subcutaneous area. Cut sections disclosed a conglomerate of enlarged necrotic lymph nodes in the mediastinum. Enclosed in the mass was an esophago-tracheal left common carotid artery fistula 1.3 cm in diameter [Figure A]. Both lungs and the stomach were filled with blood. The remainder of the lymph nodes, the spleen and the liver were normal in weight and dimension.

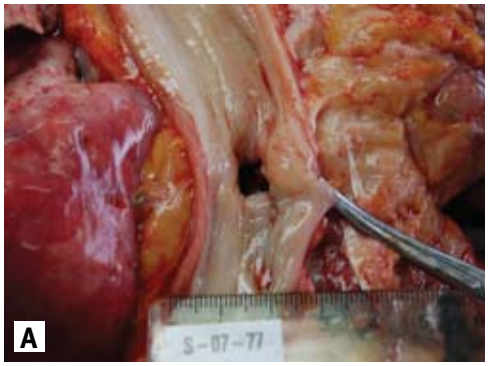

[A] Origin of the esophago-tracheal left common carotid artery fistula 6 cm from the proximal end of the esophagus. The opened esophagus is encased by the tumor.

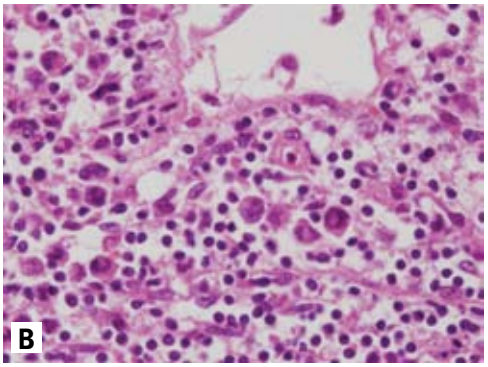

[B] Diagnostic Reed-Sternberg cells against a background of a pleomorphic infiltrate comprising plasma cells, eosinophilis and reactive T lymphocytes (hematoxylin and eosin stain, x 200 magnification).

Microscopic examination of the mediastinal lymph nodes and involved pulmonary tissue revealed diffuse proliferation of both pleomorphic and typical CD30 positive Reed-Sternberg cells with sparse mature background T lymphocytes, plasma cells and eosinophils, and areas of non-birefringent fibrosis [Figure B]. There were wide areas of necrosis involving esophageal, tracheal and left common carotid artery walls. The findings were diagnostic for nodular sclerosis classical Hodgkin's lymphoma, reticular type.

COMMENT

The commonest cause of death in the first 15–20 years after initial remission of Hodgkin's lymphoma is disease recurrence [1]. The incidence of fatal recurrence of Hodgkin's lymphoma plateaus at approximately 10 years and accounts for an accumulative mortality rate of 5%. The second most frequent cause of death during this period is the emergence of second malignancies; however, after the first 15–20 years the incidence of fatal second malignancy overtakes that of recurrent Hodgkin's to become the most common cause of late mortality after treatment for Hodgkin's lymphoma [2]. Cardiovascular and pulmonary disease are also important causes of late mortality after treatment. We describe an unusual form of late recurrence of Hodgkin's lymphoma, occurring after 9 years of remission from the disease and presenting with fatal invasion of critical organs and fistula formation.

Fistula formation in Hodgkin's lymphoma has been described rarely in the English-language medical literature and is usually attributed to radiation treatment [3] but may also be a presenting feature of the disease [4]. Little is known of the pathogenesis of fistula formation in Hodgkin's lymphoma, but production of inflammatory cytokines may contribute to local tissue necrosis and tumor invasion of neighboring structures. In our patient, the initial presentation of the disease may in fact have been associated with a degree of tissue invasion, as imaging studies revealed an intimate relation between the tumor mass and adjacent structures, namely the pericardium and left main bronchus. Although the patient received mantle radiation, this is unlikely to have been the cause of the fistula at relapse given the long interval between treatment and disease recurrence.

The diagnosis of relapsed Hodgkin's lymphoma was made only at autopsy in our patient because the clinical presentaion was coincident with a fatal complication, namely fistulous involvement of the carotid artery. However, this case demonstrates that in patients with even a remote history of Hodgkin's lymphoma, unexplained symptoms such as severe coughing on swallowing should alert the clinician to the possibility of disease relapse with fistula formation. This case also serves to remind us that during the first 15–20 years after treatment, recurrent disease remains the leading cause of death in patients who had achieved complete remission of Hodgkin's lymphoma.

Correspondence:
Dr. M.H. Ellis
Hematology Unit, Meir Medical Center, Kfar Saba 44281, Israel
Phone: (972-9) 747-1045
Fax: (972-9) 747-1644
email: martinel@clalit.org.il

References

1. Mauch P, Ng A, Aleman B, et al. Report from the Rockefellar Foundation Sponsored International Workshop on reducing mortality and improving quality of life in long-term survivors of Hodgkin's disease: July 9-16, 2003. *Eur J Haematol Suppl* 2005; 66: 68-76.
2. Ng AK, Bernardo MVP, Weller E, et al. Second malignancy after Hodgkin disease treated with radiation therapy with or without chemotherapy: long-term risks and risk factors. *Blood* 2002; 100: 1989-96.
3. Kassi ES, Belani CP, Ferson PF, Keenan RJ, Luketich JD. Hodgkin's disease presenting with a bronchoesophageal fistula. *Ann Thorac Surg* 1998; 66: 1409-10.
4. Munshi A, Pandey MB, Kumar L, Karak AK, Mohanti BK. A case of Hodgkin's disease presenting with recurrent laryngeal nerve palsy and tracheoesophageal fistula. *Med J Malaysia* 2006; 61: 97-99.