



Strychnine – A Killer from the Past

Igor Makarovsky MSc¹, Gal Markel MD PhD^{1,2}, Azik Hoffman MD¹, Ophir Schein MD¹, Tal Brosh-Nissimov MD¹, Zeev Tashma PhD^{1,3}, Tsvika Dushnitsky MD¹ and Arik Eisenkraft MD¹

¹CBRN Medicine Branch, Medical Corps, Israel Defense Force

²Sheba Cancer Research Center, Sheba Medical Center, Tel Hashomer, Israel

³Department of Medicinal Chemistry and Natural Products, School of Pharmacy, Hebrew University-Hadassah Medical School, Jerusalem, Israel

Key words: strychnine, terror, glycine antagonist, convulsions, health effects, medical care

IMAJ 2008;10:142-145

Strychnine is a natural alkaloid commercially obtained from the dried seeds of *Strychnos nux-vomica*. The various species of *Strychnos*, distributed around the world's tropics, include *Strychnos nux-vomica*, a tree native to southeast Asia, especially India and Myanmar (formerly Burma); *Strychnos toxifera*, a plant source of the poison curare, originating from South America; *Strychnos spinosa*, found mainly in tropical and subtropical Africa (the species was recently introduced into Israel as a potential new commercial crop); and *Strychnos potatorum*, found in India and used as a coagulant to purify water [1]. Seeds of *Strychnos nux-vomica* contain 1.1–1.4% strychnine [2]. Commercial baits, usually containing < 0.5% strychnine by weight, are pelleted and often dyed red or green. It is highly toxic to humans and most domestic animals and is used mainly as a rodenticide.

Over the years the cancellation of registrations of agents containing strychnine has reduced its usage throughout the world [3]. Israeli authorities have prohibited its use, as have Britain and the European Union, yet it is still in use in other Middle Eastern countries. Veterinarians are allowed to employ it under specific circumstances, e.g., to prevent the spread of rabies.

In the last 20 years human poisonings occurred mainly due to ingestion of the poison in suicidal and homicidal attempts. The lethal dose for human adults ranges between 30 and 120 mg, although death of an adult has been reported after an ingestion of 16 mg. The lethal dose for children is about 15 mg [4,5]. Though strychnine is lethal to humans, early aggressive treatment can be life saving, even following exposure to large doses as high as 3750 mg [6]. In view of the rise in global terrorism, it is important to recognize that strychnine may be utilized by terrorists to induce mass poisoning in urban populations by contamination of major food and water supplies.

This short review focuses on the unique clinical effects of strychnine and the proposed medical care that should be employed in case of strychnine poisoning.

Chemical properties and mechanism of action

Strychnine is a colorless, odorless, bitter-tasting chemical that turns into powder in dry air. The chemical structure of strychnine

is illustrated in Figure 1. Strychnine dissolves in acidic media but dissolves poorly in either water or ether [7]. The chemical has a very low vapor pressure and decomposes to release toxic combustion products, such as carbon monoxide, carbon dioxide and various nitrogen oxides [8].

Strychnine interferes with post-synaptic inhibition mediated by glycine, especially in the ventral horns of the spinal cord, brainstem and higher centers. It blocks recurrent inhibition at the Renshaw cell-motor neuron synapse* by competitively antagonizing the action of glycine released by these cells [9-11]. The loss of post-synaptic inhibition results in excessive motor neuron activity and convulsions [9,10]. Central nervous system involvement may also bring about exaggerated responses to visual, auditory and tactile stimulation. Even the slightest breeze may evoke a new set of convulsions [2,12,13].

Pharmacological properties

Strychnine is absorbed very rapidly through the gastrointestinal tract, the respiratory tract and intact skin [14,15]. In addition, it is well absorbed when given via the parenteral route (subcutaneous or intranasal). The first symptoms usually appear within 5 minutes to 1 hour after exposure, depending on the dose, the route of exposure, and the general medical health of the person exposed. It undergoes rapid and extensive metabolism by hepatic cytochrome P-450 2B and it does not seem to have an accumulative effect [2,5]. Five metabolites formed *in vitro* by rabbit liver were isolated and purified. Three of them were identified as 2-hydroxystrychnine,

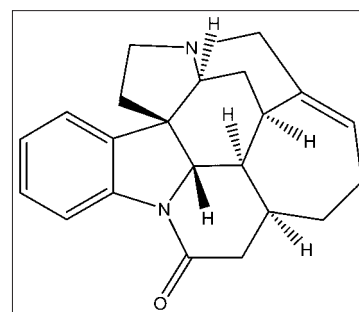


Figure 1. Chemical structure of strychnine

* Renshaw cells are interneurons in the ventromedial region of the ventral horn that make inhibitory connections with the motoneurons.

strychnine N-oxide, and 21- α ,22- β -dihydroxy-22-hydrostrychnine, when compared to authentic samples by means of ultraviolet, nuclear magnetic resonance and mass spectrometries. Additionally, two other metabolites were tentatively identified as strychnine by spectral measurements: 21,22-epoxide and 11,12-dehydrostrychnine. Strychnine N-oxide was the major metabolite and accounted for approximately 15% of the metabolized strychnine. All other metabolites accounted for < 1% [16].

The combination of detoxification and excretion renders strychnine a biological half-life (in humans) of 10–12 hours [2,17]. Up to 20% is excreted unchanged in the urine within 24 hours [2].

Health effects

Most strychnine poisonings occur through ingestion or inhalation, while only a few cases are due to topical exposure. Clinical manifestations begin with a prodromal stage.

Prodromal stage

Prodromal symptoms may often occur within 15–30 minutes following ingestion or 5 minutes after inhalation. In case of a topical exposure, the prodromal period may last up to 14–15 hours [14]. These symptoms include apprehension, restlessness, a heightened sense of awareness (hearing, vision, tactile sensation, etc.), hyper-reflexia and muscular stiffness of face and legs. Vomiting is uncommon [2].

Clinical stage

The clinical hallmark of this stage is manifested mainly by recurrent violent seizures while the victim is fully alert [2,12]. Short yet violent convulsions lasting from 30 seconds to 2 minutes are triggered even by a faint sensory stimulus. The combination of convulsions with intact sensorium is the most noticeable manifestation of strychnine poisoning. These convulsions are clonic at first, and then become tetanic with opisthotonus, trismus of the jaws, and the appearance of “risus sardonicus” (a grinning expression produced by spasm of the facial muscles). The eyes protrude in a fixed stare. Tetanic contractions of the diaphragm, thoracic muscles and abdominal muscles prevent normal respiration, generating anoxia and cyanosis. The convulsions may be accompanied by mydriasis, proptosis, and conjugated or dissociated deviations of the eyes. Full consciousness is present throughout the seizure and the victim remains anxious, frightened and in pain. Complete muscular relaxation occurs between the convulsions, when the victim is breathing and cyanosis disappears. Dilated pupils may contract and the victim may fall asleep from exhaustion. These intervals usually last for up to 10–15 minutes and are interrupted by additional spasms triggered even by a draft of air [2]. Usually there are between one and ten attacks; each is more intense than the previous one, with shortening of the intervals. In the absence of effective treatment (and occasionally despite it), the victim rarely survives the fifth spasm and dies from respiratory arrest. If the victim survives the first 5–6 hours, the prognosis is favorable [2]. Possible complications include hyperthermia, respiratory and metabolic acidosis, rhabdomyolysis and myoglobinuric renal failure. Anoxic brain

Table 1. Major human health effects following strychnine poisoning

System	Prodromal stage	Clinical stage
Eyes		Exophthalmus, mydriasis, bilateral horizontal pendular nystagmus
Skin	Allergic response	Hypersensitivity
Respiratory tract		Spasmodic diaphragm movements, cyanosis, dyspnea, hypoxia, respiratory failure
Central nervous system	Restlessness, apprehension, cold perspiration, heightened acuity of perception	Tremor, violent repeated convulsions with opisthotonus, impairment of short and medium-term memory
Gastrointestinal tract	Vomiting (uncommon)	Vomiting
Cardiovascular		Weak pulse, tachycardia, hypertension, cardiac arrest
Renal and urinary tract		Myoglobinuria, acute renal failure
Musculoskeletal and smooth muscles	Stiffness of facial and neck muscles, hyper-reflexia	Contractions of all voluntary muscles simultaneously, including chest and abdominal muscles, hypertonicity of the muscles, tonic twitching of the face and neck muscles, trismus, risus sardonicus, rhabdomyolysis
Metabolic		Hyperthermia
Laboratory findings		Lactic acidosis, hyperkalemia, elevations of AST, LDH, CPK, leukocytosis
Carcinogenicity		Not considered a carcinogen

See refs. 5,8,11,12,14,26-30

AST = aspartate aminotransferase, LDH = lactate dehydrogenase, CPK = creatine phosphokinase

damage and multi-organ failure due to hyperthermia may cause late death. Long-term sequelae are not usually expected [2]. Major human health effects following acute strychnine exposure are summarized in Table I.

Differential diagnosis

Strychnine is a strong convulsing agent. The differential diagnosis includes pathological conditions such as epilepsy, tetanus, meningitis, rabies, phenothiazine overdose, cocaine and phencyclidine use, and exposure to chlorinated hydrocarbons, isoniazid, cyanides, organophosphates or other substances that may cause myoclonus or seizures [3,12]. The victim, however, remains conscious until moments before death, which distinguishes this condition from various causes and forms of epilepsy. The absence of fever and the sudden onset of convulsions exclude meningitis and meningoencephalitis. The relatively clear sensorium, coupled with powerful and painful convulsions, arouses panic in the patient [12,13,17].

Medical care

In severe cases of strychnine intoxication the patient dies before reaching the hospital. Since strychnine does not have a specific antidote, the treatment is supportive and symptomatic. The pa-

tient should be moved to a dark and quiet room, and vomiting should not be induced since it may lead to asphyxia.

The spasmodic motoneuron activity is generally treated with intravenous benzodiazepines (e.g., diazepam or midazolam) or a short-acting barbiturate [15,18,19]. When unsuccessful, the patient should be sedated and paralyzed, usually with neuromuscular blockers such as pancuronium or vecuronium bromide, then ventilated [20,21]. Introducing a nasogastric tube may trigger a new attack and should be avoided if possible. Strychnine is rapidly absorbed and by the time the patient arrives at the emergency department it is unlikely to be found in the stomach. This renders gastrointestinal decontamination useless.

Hyperthermia should be treated aggressively by active cooling with ice-water immersion, cooling blanket or cool mist, depending on the degree of temperature elevation [12,18]. In severe cases of hyperthermia dantrolene may be used.

Rhabdomyolysis, metabolic acidosis and myoglobinuria may occur secondary to severe muscular spasms during seizures. It is important to monitor the patient and correct these conditions in time [21]. Levels of lactate dehydrogenase, creatine phosphokinase, aspartate aminotransferase, urine myoglobin and coagulation should be monitored for 24–48 hours. Urine output should be promoted. Strychnine levels may be detected in the blood, urine or other organs, but these do not correlate well with

clinical toxicity or the need for therapy [22]. A biopsy reported by Perper [23] identified strychnine in the gastrointestinal tract, in the kidneys and urine, in the plasma, and a small amount was even detected in the cerebrospinal fluid. Usually, if the victim survives the critical phase (first 24 hours), even after ingesting a large dose of strychnine, the prognosis is favorable, with an average treatment time of a few days to a few weeks until full recovery [13,24].

Case studies

Although strychnine is now used only as a rodenticide and occasionally to eradicate rabies, some use it for other purposes. There are three major causes of strychnine intoxication: suicide attempts, accidental ingestion (especially by children, since strychnine tablets may look like pink or green candies), or as an adulterant in street drugs (such as amphetamines, heroin and cocaine) [20].

It has also been used with intent to kill. The only mass-poisoning event with strychnine that we found occurred about 150 years ago in the “new world.” While celebrating a peace agreement with the Shasta nation (an Indian tribe in early California) at Fort Jones in 1851, the Americans fed the Indians meat laced with strychnine. As a result, 4000 Indians died from poisoning [25]. Representative contemporary strychnine poisoning cases are listed in Table 2.

Table 2. Representative contemporary strychnine poisoning cases

	Case 1	Case 2	Case 3	Case 4
Year and place	1985, Pittsburgh, USA	1992, Toledo, USA	2001, Manitoba, Canada	2003, Bedouin village, Negev, Israel
Publication	Perper	Yamarick et al.	Greene & Meatherall	Starretz-Hacham et al.
Age	56	14	50	6
Gender	Male	Female	Female	Male
Intention	Suicidal	Innocent	Innocent	Innocent
Source	76 g of “Mole-Nots” rodenticide containing 0.35% of strychnine sulfate	A suspected bottle of medication	An old bottle of strychnine solution	Several pink tablets of unknown substance (approximately 140 mg strychnine)
Route	Ingestion	Intravenous	Dermal	Ingestion
Time to onset	50 min	30 min	14–15 hrs	30 min
Clinical manifestations	Full consciousness, abdominal pains, a set of two 30 sec attacks of tonic convulsions, extreme body rigidity, opisthotonus, a period of total flaccidity, apnea, loss of consciousness	Tonic convulsions, a temperature rise after 24 hrs (40.5°C), diaphoresis, alertness, inability to walk, loss of feeling in her legs, frequent tonic-clonic convulsions (each lasting for 1–2 minutes) triggered by the slightest stimuli, both feet were drawn up and inward, ECG revealed sinus tachycardia with non-specific ST-T segment abnormalities, myalgia, rhabdomyolysis	Spasms in arms and legs, alertness, awareness, muscular cramps, pain while opening the jaw; palpation of the calves was painful, dermal hypersensitivity of the legs, could not walk due to pain felt with any attempt to stand	Severe muscle cramps, consciousness yet disorientation, vomiting, severe muscle tetania, mydriasis, hypotension, sinus tachycardia; metabolic acidosis; rhabdomyolysis (CPK 4992 U/L, high serum myoglobin 750 ng/ml, creatinine 1.3 mg/dl),
Treatment	Cardiopulmonary resuscitation was initiated	Repeated doses of i.v. diazepam 5 mg, sodium bicarbonate 250 ml to correct her acidosis, activated charcoal 50 g per os, adequate hydration and urine output were maintained	Fluid rehydration and alkalization drugs as prophylaxis against renal failure secondary to rhabdomyolysis (creatinine kinase 677 U/L)	Repeated doses of i.v. diazepam 0.5 mg/kg/dose with no effect, intubation, ventilation, treatment with intravenous vecuronium bromide (0.1 mg/kg/hr for 20 hrs)
Outcome	Death	Full recovery and discharge after 72 hrs	Condition resolved, discharged 48 hrs after admission, asymptomatic	Good response to medication; discharged after 3 days

See refs. 14,21,23,31

Summary

Strychnine is still used as a powerful rodenticide and to a lesser extent against rabies-infected dogs. Strychnine poisoning is characterized by a short prodromal phase, after which there is an unusual combination of seizures with intact sensorium. Complications consist of hyperthermia, renal failure and rhabdomyolysis. The common cause of death is respiratory failure. The most important medical treatment includes termination of seizures (e.g., benzodiazepines), correcting the acidosis, and sedating, paralyzing and ventilating the patient as needed. When dealing with recurrent or unresponsive seizures, the physician should take strychnine poisoning into consideration. Early intervention could save patients' lives.

References

- Philippe G, Angenot L, Tits M, Frederich M. About the toxicity of some Strychnos species and their alkaloids. *Toxicol* 2004;44:405-16.
- Gosselin RE, Smith RP, Hodge HC. *Clinical Toxicology of Commercial Products*. 5th edn. Baltimore/London: Williams & Wilkins, 1984:375-9.
- Radosavljevic J, Jeffries WS, Peter JV. Intentional strychnine use and overdose – an entity of the past? *Crit Care Resusc* 2006;8:260-1.
- The Committee for Veterinary Medicinal Products. Strychni Semen. Summary Report. www.emea.eu.int/pdfs/vet/mrls/050498en.pdf 1999 March.
- Borges A, Abrantes J, Teixeira MT, Parada P. Strychnine. www.inchem.org/documents/pims/chemical/pim507.htm 2006.
- Burn DJ, Tomson CR, Seviour J, Dale G. Strychnine poisoning as an unusual cause of convulsions. *Postgrad Med J* 1989;65:563-4.
- Strychnine. In: Budavari S, ed. *The Merck Index: An Encyclopedia of Chemicals, Drugs, and Biologicals*. 12th edn. Rahway, NJ: Merck and Co. Inc., 1996:1512.
- Strychnine Material Safety Data Sheet. www.jtbaker.com/msds/englishhtml/s6976.htm 2006.
- Aprison MH, Lipkowitz KB, Simon JR. Identification of a glycine-like fragment on the strychnine molecule. *J Neurosci Res* 1987; 17:209-13.
- Aprison MH, Galvez-Ruano E, Lipkowitz KB. Identification of a second glycine-like fragment on the strychnine molecule. *J Neurosci Res* 1995;40:396-400.
- Klaassen CD. Nonmetallic environmental toxicants: air pollutants, solvents and vapors, and pesticides. In: Hardman JG, Limbird LE, eds. *Goodman & Gilman's Pharmacological Basis of Therapeutics*. 10th edn. New York: McGraw-Hill, 2001:1894-5.
- Chan Y-C. Strychnine. In: Goldfrank LR, Flomenbaum M, Hoffman RJ, Howland M-A, Lewin NA, Nelson LS, eds. *Goldfrank's Toxicologic Emergencies*. 8th edn. New York: McGraw-Hill, 2002: 1492-6.
- Cotten MS, Lane DH. Massive strychnine poisoning: a successful treatment. *J Miss State Med Assoc* 1966;7:466-8.
- Greene R, Meatherall R. Dermal exposure to strychnine. *J Anal Toxicol* 2001;25:344-7.
- Lambert JR, Byrick RJ, Hammeke MD. Management of acute strychnine poisoning. *Can Med Assoc J* 1981;124:1268-70.
- Mishima M, Tanimoto Y, Oguri Z, Yoshimura H. Metabolism of strychnine in vitro. *Drug Metab Dispos* 1985;13:716-21.
- Boyd RE, Brennan PT, Deng JF, Rochester DF, Spyker DA. Strychnine poisoning. Recovery from profound lactic acidosis, hyperthermia, and rhabdomyolysis. *Am J Med* 1983;74:507-12.
- Worthley LI. *Clinical Toxicology. Part II: Diagnosis and management of uncommon poisonings*. *Crit Care Resusc* 2002;4:216-30.
- Billimoria RB, Naik PR, Satoskar RS. Effect of diazepam alone and in combination with chlorpromazine or propranolol in experimentally induced convulsions in mice. *J Postgrad Med* 1981; 27:73-9.
- O'Callaghan WG, Joyce N, Counihan HE, Ward M, Lavelle P, O'Brien E. Unusual strychnine poisoning and its treatment: report of eight cases. *Br Med J (Clin Res Ed)* 1982;285:478.
- Starretz-Hacham O, Sofer S, Lifshitz M. Strychnine intoxication in a child. *IMAJ* 2003;5:531-2.
- HSDB – Hazardous Substances Data Bank. Strychnine. <http://toxnet.nlm.nih.gov/cgi-bin/sis/search/f?temp/~D9QRS8:1> 2007.
- Perper JA. Fatal strychnine poisoning – a case report and review of the literature. *J Forens Sci* 1985;30:1248-55.
- Nishiyama T, Nagase M. Strychnine poisoning: natural course of a nonfatal case. *Am J Emerg Med* 1995;13:172-3.
- Giese P. Norma Jean Croy – California History: The Hidden Genocide. <http://www.kstrom.net/isk/stories/normtrea.html> 1995.
- Sax NI. *Strychnine. Dangerous Properties of Industrial Material*. New York: Van Nostrand Reinhold, 1988:78-83.
- Gossel TA, Bricker JD. *Principles of Clinical Toxicology*. New York: Raven Press, 1994:350-5.
- Conn HJ. Raket: Conn's Current Therapy. www.mdconsult.com 2007(59).
- Blain PG, Nightingale S, Stoddart JC. Strychnine poisoning: abnormal eye movements. *J Toxicol Clin Toxicol* 1982;19:215-17.
- Hayes WJ. *Pesticides Studied in Man*. Baltimore/London: Williams & Wilkins, 1982:96-101.
- Yamarick W, Walson P, DiTraglia J. Strychnine poisoning in an adolescent. *J Toxicol Clin Toxicol* 1992;30:141-8.

Correspondence: Dr. A. Eisenkraft, 2 Hatavor Street, Ganei Tikva 55900, Israel.

Phone: (972-3) 737-3108; Fax: (972-3) 737-6111
email: aizenkra@gmail.com