IMAJ • VOL 11 • DECEMBER 2009

Fortunate Retention of an Endoscopic Video Capsule by Primary Small Bowel Carcinoma

Osnat Zmora MD[1], Samuel N. Adler MD[2], Joseph M. Klausner MD[1] and Joseph Kuriansky MD[1]

[1]Division of General Surgery, Tel Aviv Sourasky Medical Center, Tel Aviv, Israel
[2]Institute of Gastroeneterology, Bikur Holim Hospital, Jerusalem, Israel

KEY WORDS: retention, endoscopic video capsule, obstruction, small bowel, tumor

IMAJ 2009; 11: 762–763

Wireless capsule endoscopy has become the most sensitive and most specific modality for evaluation of the mucosa of the small bowel and is increasingly used by gastroenterologists to diagnose small bowel pathology. This methodology was found to be superior to barium X-ray and push enteroscopy in the investigation of obscure gastrointestinal bleeding and in the evaluation of suspected Crohn's disease [1]. The procedure is usually safe, with the main complication being retention of the video capsule in patients with unsuspected obstructive small bowel disease. As such, small bowel obstruction and strictures are still considered by many physicians to be a contraindication to capsule endoscopy for fear of capsule retention or impaction, although there are indications of a changing trend in attitude [2].

We describe a case of capsule retention due to primary small bowel carcinoma that led to laparotomy and resection of small bowel malignancy.

[A] Video capsule image of the suspected polypoid mid-small bowel tumor

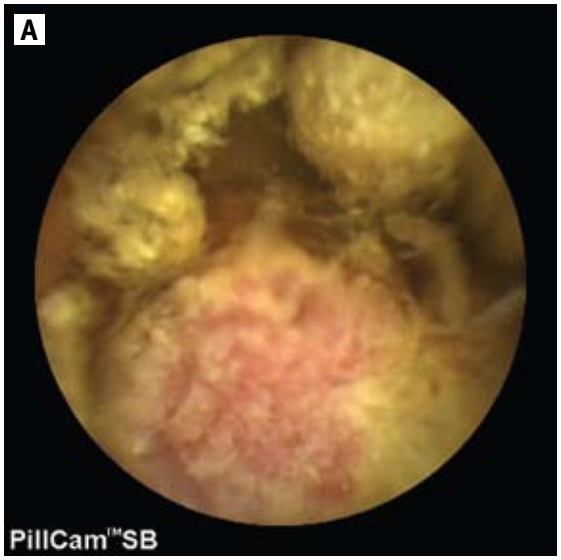

PATIENT DESCRIPTION

A 65 year old woman with juvenile polyposis was referred to our division of surgery because of a retained video capsule. She was a carrier of *BRCA II* mutation, and had undergone prophylactic bilateral oophorectomy 9 years earlier. Her medical history also included bilateral lumpectomies and chemoradiation as well as hormonal treatment due to breast cancer 5 years earlier. One year prior to her referral to us, she began to suffer from postprandial cramping and diffuse abdominal pain accompanied by nausea and constipation. She had lost 13 kg of her body weight during the previous year.

A laboratory workup revealed iron deficiency anemia and a mildly elevated blood level of CA 19-9 (69 U/ml, normal 0–37), which stabilized in repeat blood tests. Colonoscopy, gastroscopy, abdominal computed tomography and small bowel follow-through were negative except for three small juvenile colonic polyps that were resected. Positron emission tomographic-CT scanning demonstrated three areas of enhancement: in the small bowel, at the site where mild thickening had been demonstrated by CT, in the ascending colon and in the cecum. Abdominal sonography demonstrated mild dilatation of the common bile duct. Since the findings were neither convincing nor consistent for the bowel as the source of complaints, an endoscopic ultrasound was performed in search of a pancreatic tumor and was negative. It was decided to perform wireless capsule endoscopy, and recordings from the capsule indicated a neoplastic-type lesion in the mid-small bowel [Figure A].

A few hours after ingestion of the capsule, the patient started complaining of cramping abdominal pain and vomiting. She continued to have normal bowel movements and regular eating habits. Plain abdominal film demonstrated a retained capsule in the small bowel without clear-cut signs of bowel obstruction. The patient's condition improved under conservative treatment by the gastrointestinal service. The surgical team was consulted and the patient was prepared for laparotomy and possible intraoperative enteroscopy.

At surgery, abdominal exploration revealed distended loops of small bowel proximal to a mid-ileal constricting mass. The capsule was palpated just proximal to this mass. Small bowel loops were slightly collapsed distally. There were no signs of omental, peritoneal or hepatic spread. The rest of the small bowel was normal. There was no need to perform an enteroscopy. A small bowel

resection and anastomosis were performed. Figure B displays the excised specimen and the extracted capsule.

Pathology revealed a polypoid infiltrating mucus-secreting adenocarcinoma penetrating the entire wall into the mesentery, without lymph node invasion. Five months later, the patient is being treated with chemotherapy and is feeling generally well.

COMMENT

Video capsule endoscopy is most commonly used to detect obscure gastrointestinal bleeding not located by conventional endoscopy. Other indications include suspicion of inflammatory bowel disease, malabsorption disorders, iatrogenic disease (such as non-steroidal anti-inflammatory drug strictures, radiation enteritis), clarification of previous imaging, and chronic abdominal pain. Small bowel neoplasms have also been extensively explored using this method [3].

In 2002, when the American Society of Gastrointestinal Endoscopy issued the first set of guidelines on wireless capsule endoscopy, gastrointestinal obstruction was defined as an absolute contraindication for fear of capsule retention. Rates of capsule non-passage or retention vary depending on the series and were relatively uncommon (0.75%–13%) [4], although clinically significant. Capsule retrieval has been achieved by endoscopic means, including double balloon enteroscopy [5] and by surgery, including laparoscopic surgery.

A recent retrospective study on the safety and efficacy of capsule endoscopy in the evaluation of patients with suspected bowel obstruction included 19 cases of suspected small bowel obstruction; there were 4 cases of capsule retention (21%), none due to cancer. The authors concluded that capsule endoscopy can be safely used to help identify the etiology and site of a small bowel obstruction, although it is understood that retention could lead to surgery in a patient who otherwise may have been treated medically, e.g., in Crohn's disease or NSAID enteropathy. It is important to note that, just as in our patient, there has been no case in which capsule ingestion caused an acute small bowel obstruction [2].

Our patient had a chronic small bowel obstruction with a high index of suspicion for malignancy, but without consistent or sufficient evidence on multiple and varying imaging studies to justify abdominal exploration until video capsule endoscopy provided images consistent with a malignant lesion. Capsule retention eventually mandated surgery, leading to a definitive diagnosis and appropriate treatment. Our case is a good example of the application of video capsule endoscopy when there is suspicion of a tumoral small bowel obstruction but insufficient evidence from other methodologies to justify surgery. Retention of the capsule in our case was fortunate, leading to optimal patient management.

NSAID = non-steroidal anti-inflammatory drug

[B] Resected small bowel segment with the constricting tumor and the video capsule

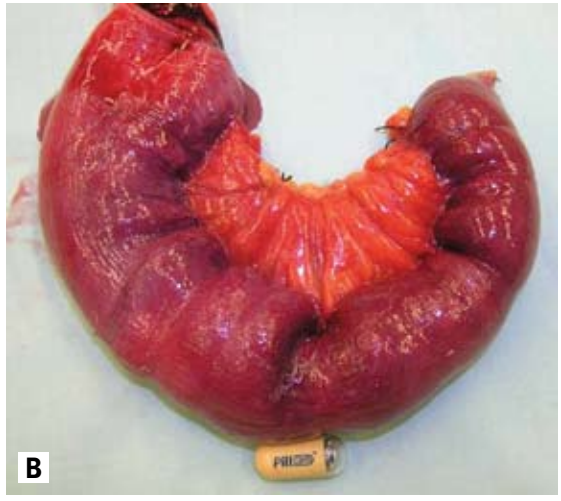

Correspondence:
Dr. O. Zmora
Division of General Surgery, Tel Aviv Sourasky Medical Center, 6 Weizmann Street, Tel Aviv 64239, Israel
Phone: (972-3) 697-4711
Fax: (972-3) 697-4635
email: tomor2304@yahoo.com

References

1. Ginsberg GG, Barkun AN, Bosco JJ, et al. Wireless capsule endoscopy: August 2002. *Gastrointest Endosc* 2002; 56(5): 621-4.
2. Cheifetz AS, Lewis BS. Capsule endoscopy retention: is it a complication? *J Clin Gastroenterol* 2006; 40(8): 688-91.
3. Remedios ML, Appleyard M. Capsule endoscopy: current indications and future prospects. *Intern Med J* 2005; 35: 234-9.
4. Barkin JS, Friedman S. Wireless capsule endoscopy requiring surgical intervention. The world's experience. *Gastrointest Endosc* 2003; 58: 650-5.
5. Fireman Z, Kopelman Y, Fish L, Sternberg A, Scapa E, Mahajna E. Effect of oral purgatives on gastric and small bowel transit time in capsule endoscopy. *IMAJ* 2004; 9: 521-3; Editorial 560-1.