

# Obviating Lethal Catheter Placement in a Preterm Heart

Ronella Marom MD, Alon Haham MD and Shaul Dollberg MD

Department of Neonatology, Lis Maternity Hospital, Tel Aviv Sourasky Medical Center, Tel Aviv, affiliated with Sackler Faculty of Medicine, Tel Aviv University, Ramat Aviv, Israel

**KEY WORDS:** peripherally inserted central catheter, pericardial tamponade, preterm infants

IMAJ 2012; 14: 652

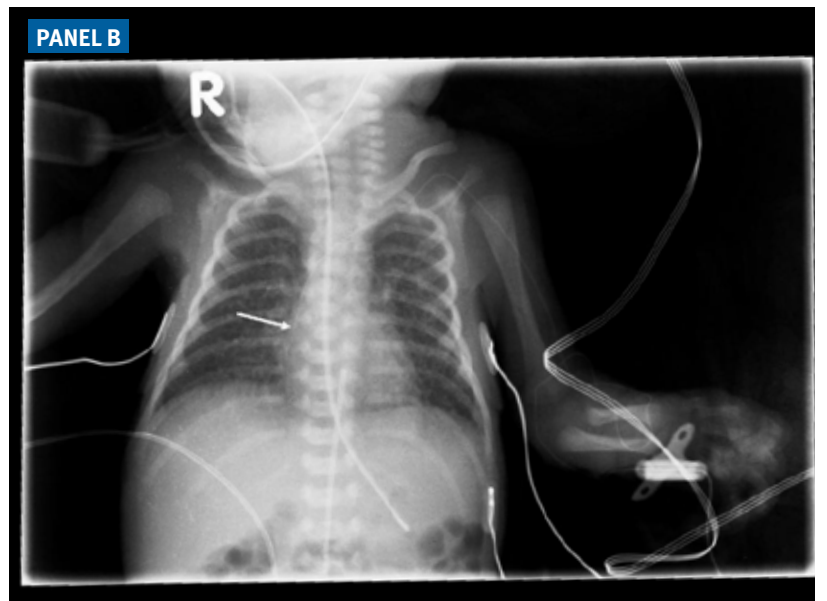
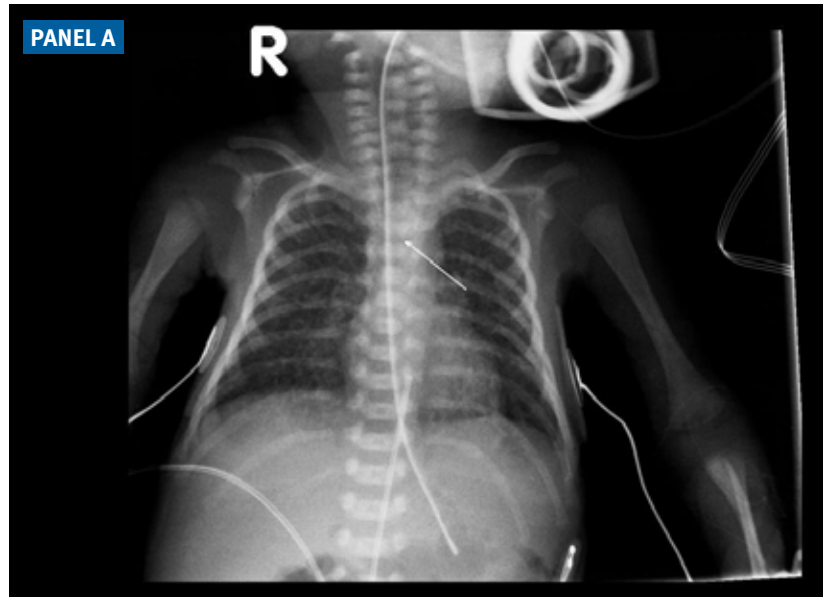
A percutaneously placed central catheter (PICC) (Vygon premicath 28G, 1Fr, Germany) was inserted into the central venous system of a preterm infant born after 26 weeks of gestation for routine parenteral nutrition. A plain anteroposterior chest X-ray for verifying correct catheter placement erroneously showed the catheter tip to be located safely outside the heart silhouette [Panel A]. Injection of radio-opaque contrast medium into the catheter revealed that the catheter tip was inside the right ventricle [Panel B], putting the preterm infant at risk of the potentially lethal complication of cardiac tamponade caused by the tip's dissection of the cardiac wall. The tip placement was corrected. Other complications of misplaced tips include ascites, pericarditis and venous sinus thrombosis. PICCs are routinely used in term and preterm infants to provide intravenous access for prolonged therapy and parenteral nutrition. We recommend mandatory use of contrast material on chest X-rays in this setting.

**Corresponding author:**

**Dr. R. Marom**

Dept. of Neonatology, Tel Aviv Sourasky Medical Center, Tel Aviv 64239, Israel

**email:** marom.ronella@gmail.com



Millions long for immortality who do not know what to do  
with themselves on a rainy Sunday afternoon

Susan Ertz (1894-1985), British novelist