Traumatic Carotid Artery Dissection

Gustavo Rajz MD[1], Dani Simon MD[4], Mati Bakon MD[2], Oded Goren MD[4], Jacob Zauberman MD[4], Zion Zibly MD[4], Eyal Zimlichman MD[3] and Sagi Harnof MD[4]

Departments of [1]Neurosurgery, [2]Neuroradiology and [3]Internal Medicine B and [4]Trauma Unit, Sheba Medical Center, Tel Hashomer, and Sackler Faculty of Medicine, Tel Aviv University, Ramat Aviv, Israel

KEY WORDS: trauma, extracranial, internal carotid artery dissection

IMAJ 2009;11:507–508

Carotid artery dissections are rare lesions following head and neck injury and are usually suspected in the case of direct neck trauma or evidence of bony fracture along the course of one of the major cranial arteries. Clinical presentation can vary among a wide range of symptoms and signs, leading often to a delay in diagnosis that could be fatal. We present here such a case and discuss the possible clinical presentation and imaging findings.

PATIENT DESCRIPTION

A 15 year old girl without any significant medical history was admitted after being hit by a car. In the emergency room her Glasgow Coma Scale was 9 and she was combative. She was intubated and a total body computed tomography scan was performed. The brain and spinal CT scans were normal and there was no evidence of intracranial trauma or of spinal and cranial bony injury. Other examinations revealed bleeding from the inferior pole of the spleen and macrohematuria due to left kidney injury. The patient was hemodynamically stable and embolization for her abdominal injury was performed.

Subsequently, after discontinuing sedation she was able to localize painful stimuli on the right side, but she had left hemiplegia. The pupils were reactive to light. Another CT scan of the head was performed and revealed a mild subarachnoid hemorrhage at the left ambient cistern. This imaging finding did not explain her hemiplegia and therefore a vascular injury of the carotid artery was suspected.

CT-angiography of the neck and brain revealed a bilateral internal carotid artery dissection that was prominent on the right side (right distal C1 carotid artery dissection just before the entrance to the skull), with patent blood flow at the carotid above the injury. There was a classical finding of the string sign and double lumen sign on the CTA [Figure A]. A digital subtraction angiography was performed to confirm the diagnosis [Figure B]. After consultation with the cerebrovascular team, it was decided to initiate anticoagulation therapy with heparin. On heparin treatment the patient developed a perinephric hemorrhage, and a second embolization to a branch of the renal artery was needed.

The anticoagulation therapy was renewed and the patient was discharged to a rehabilitation facility after 3 weeks on warfarin treatment. She continued rehabilitation at an outpatient clinic and at the last follow-up she showed no neurological deficit but still had mild cognitive disturbances. A follow-up CTA was performed and demonstrated the same pattern of dissection on both sides, with no propagation of the intimal tear or thrombus. Later, a three-dimensional

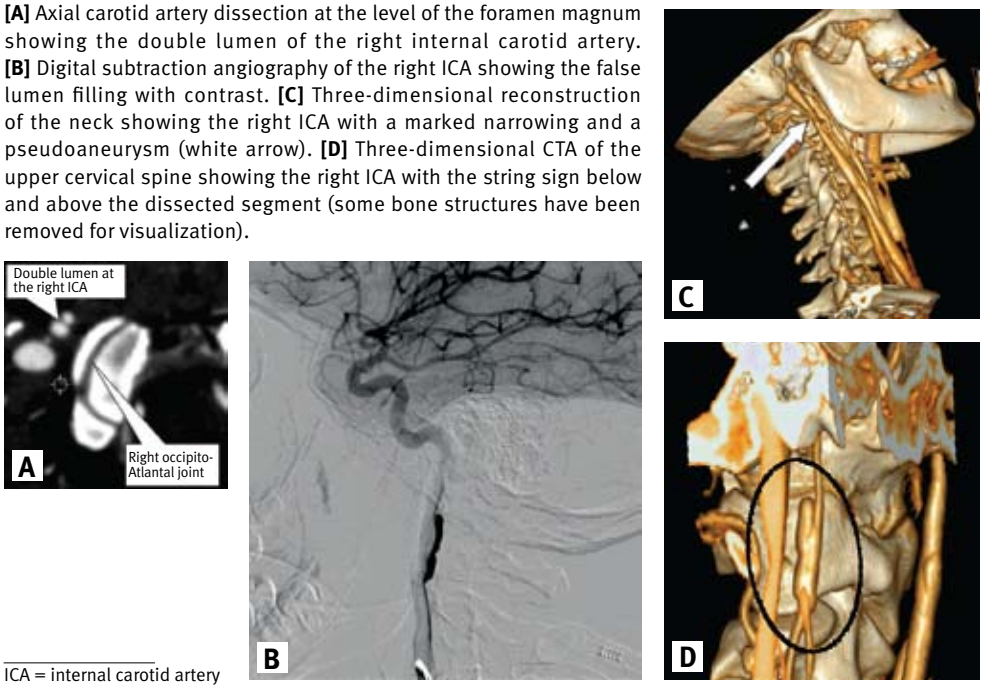

[A] Axial carotid artery dissection at the level of the foramen magnum showing the double lumen of the right internal carotid artery. **[B]** Digital subtraction angiography of the right ICA showing the false lumen filling with contrast. **[C]** Three-dimensional reconstruction of the neck showing the right ICA with a marked narrowing and a pseudoaneurysm (white arrow). **[D]** Three-dimensional CTA of the upper cervical spine showing the right ICA with the string sign below and above the dissected segment (some bone structures have been removed for visualization).

ICA = internal carotid artery

CTA = computed tomography-angiography

CTA reconstruction of the neck area was performed [Figure C,D].

COMMENT

Carotid artery dissections should be considered in patients after severe trauma presenting with localizing signs and normal CT scan as presented in this case. A multidisciplinary approach is needed to establish the diagnosis and start the appropriate treatment. Carotid artery dissections have varied presentations that depend on the location and vessel involved. The heterogeneous clinical pictures associated with carotid artery dissections often lead to delays in diagnosis and treatment. The condition may be asymptomatic or result in minor symptoms, stroke, or even death. Symptoms associated with transient ischemic attack and strokes are the most common presenting features, while neck pain (carotidynia) and headaches are other features that are often manifested. Extracranial carotid artery dissections may result in cerebral ischemia with corresponding neurological deficits, local symptoms due to compression phenomena, ipsilateral oculosympathetic palsy (i.e., partial or complete Horner syndrome), cranial nerve deficits, and pulsatile tinnitus. Further complicating the diagnosis is that in some cases damage to the vessel layers had preceded the onset of ischemic signs by months and even years. Our patient demonstrated an acute onset of hemiplegia early in the hospital course, thus warranting further investigations via imaging studies.

Cervicocephalic artery dissections should be considered in the differential diagnosis of young individuals presenting with neurological deficits, especially in the setting of trauma [3]. The average annual incidence rate for carotid artery dissections was 2.6 per 100,000 population. Traumatic dissection occurs in approximately 1% of all patients with blunt injury mechanisms [4]. Overall, dissections are estimated to account for only 2% of all ischemic strokes, but they are an important factor in the young and account for approximately 20% of strokes in patients under the age of 45.

As described in the literature, the symptoms may immediately follow the traumatic event or be delayed by days to months. Time delays following trauma until presentation are most frequent within the first 24 hours (57–73%) [5]. Initial symptoms and imaging findings may be subtle, thus presenting considerable diagnostic difficulties. The varied course of dissections further complicates the picture, as does the lack of consensus regarding effective treatment modalities.

Angiography is the definitive diagnostic study. However, the diagnosis is often delayed because errors in interpretation are frequent and include misinterpreting the dissection as an unusual saccular aneurysm (the most common error), atherosclerotic lesions, vasospasm following subarachnoid hemorrhage (the narrowing with vasospasm is delayed in onset versus the changes with dissection that are present from the beginning).

In our case, continued observation along with the use of anticoagulant agents proved to be helpful in attaining clinical improvement. It should be noted that continued as well as comprehensive follow-up is important, because of the possibility of delayed or recurrent manifestations.

In conclusion, carotid artery dissections are rare lesions following head and neck injury that are usually suspected in the case of direct neck trauma, or with evidence of bony fracture along the course of one of the major cranial arteries. They should be considered in patients after severe trauma presenting with localizing signs and normal CT scan, as in the case reported here. A multidisciplinary approach is needed to establish the diagnosis and initiate the appropriate treatment.

Correspondence:
Dr. E. Zimlichman
Central Management, Sheba Medical Center, Tel Hashomer 52621, Israel
Phone: (972-3) 530-4501
Fax: (972-3) 530-3512
email: zimliche@post.tau.ac.il

References

1. Menon R, Kerry S, Norris JW, Markus HS. Treatment of cervical artery dissection: a systematic review and meta-analysis. *Neurol Neurosurg Psychiatry* 2008; 79: 1122-7.
2. Anson J, Crowell RM. Cervicocranial arterial dissection. *Neurosurgery* 1991; 29: 89-96.
3. Lee VH, Brown RD, Mandrekar JN, Mokri B. Incidence and outcome of cervical artery dissection: a population-based study. *Neurology* 2006; 67: 1809-12.
4. Redekop GJ. Extracranial carotid and vertebral artery dissection: a review. *Can J Neurol Sci* 2008; 35: 146-52.
5. Jariwala SP, Crowley JG, Roychowdhury S. Trauma-induced extracranial internal carotid artery dissection leading to multiple infarcts in a young girl. *Pediatr Emerg Care* 2006; 22: 737-42.

"Man's capacity for justice makes democracy possible, but man's inclination to injustice makes democracy necessary"

Reinhold Niebuhr (1892-1971), American Protestant theologian, best known for his work to relate the Christian faith to the realities of modern politics

"The best armor is to keep out of gunshot"

Francis Bacon (1561-1626), British essayist, philosopher, statesman, scientist, lawyer, jurist, and author. He served both as Attorney General and Lord Chancellor of England. His works established and popularized an inductive methodology for scientific inquiry, often called the Baconian method or simply, the scientific method. His demand for a planned procedure of investigating all things natural marked a new turn in the rhetorical and theoretical framework for science, much of which still surrounds conceptions of proper methodology today.