

# Eosinophilic Fasciitis Accompanied by Serositis

Anastasios Andreopoulos MD, Tilemachos-Christos Antoniou MD, Xanthi Yiakoumis MD, George Andreopoulos MD, George Vaiopoulos MD and Kostas Konstantopoulos MD

First Department of Internal Medicine, University of Athens School of Medicine, Laikon General Hospital, Athens, Greece

**KEY WORDS:** fasciitis, serositis, eosinophilic, pleuritis, pericarditis

*IMAJ* 2009;11:319–320

**E**osinophilic fasciitis is an uncommon localized scleroderma-like disorder of unknown etiology that substantially affects quality of life [1]. It is characterized by inflammation of the fascia, limb or trunk erythema and edema, and collagenous thickening of the dermis and subcutaneous fascia; visceral involvement is rarely reported. Originally described as a diffuse fasciitis with peripheral blood eosinophilia, it is realized today that this disorder may accompany several disease conditions, including malignancies. The distinction between eosinophilic fasciitis and various forms of localized scleroderma (morphea) remains open. We describe a patient who presented with

localized pain and edema of the left calf and ankle associated with fever and pericardial and pleural effusion.

## PATIENT DESCRIPTION

Our patient was a 26 year old woman with localized pain and edema in her left calf and ankle associated with pericardial and pleural effusion. She presented with fever, dyspnea, pleuritic pain, edema and pain in her left calf and ankle that started 8 days before her admission. Her recent medical history included arthralgias in the right knee and pain in the right calf for which a physician prescribed low dose steroids for 6 months that resulted in considerable amelioration of symptoms. Laboratory tests conducted at that time, including rheumatoid factor, antinuclear antibodies and other immunology tests, were normal. Two months before her admission to our hospital she discontinued steroids and her symptoms recurred.

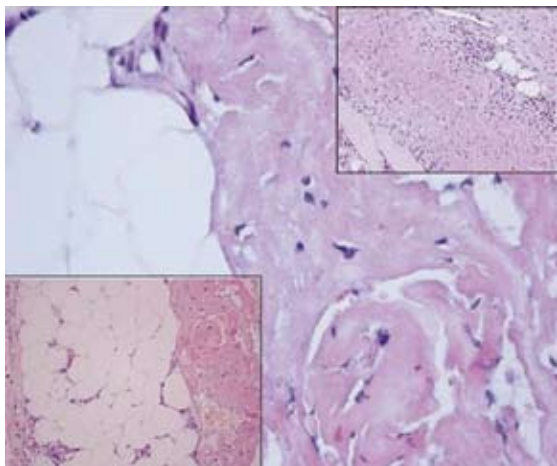
On presentation she denied any previous intense physical exercise. Physical examination revealed diminished breath sounds and crackles at her left lung base, tachycardia (120/minute) and a pericardial friction rub. Body temperature was 37.6°C. A mild swelling of her left calf and ankle without overt discoloration of the skin was noted, but the rest of the clinical examination was unremarkable. Laboratory tests showed mild anemia (hematocrit 32%, hemoglobin 10.3 g/dl), mild leukocytosis (white blood cells  $11.2 \times 10^9/L$ , neutrophils  $8.9 \times 10^9/L$ , lymphocytes  $1.37 \times 10^9/L$ , monocytes  $0.93 \times 10^9/L$ , eosinophils 0, baseophils 0), normal platelets, normal erythrocyte morphology, elevated erythrocyte sedimentation rate (130 mm/hr) and mild hypoxia

( $pO_2 = 70$  mmHg, in room air). Serum protein electrophoresis, electrolytes, liver and muscle enzymes were normal. Immunology testing was negative for rheumatoid factor, antinuclear and anti-erythrocyte antibodies. C-reactive protein was 8.5 mg/dl (normal < 1.0). Antibodies for human immunodeficiency virus, Epstein-Barr virus, cytomegalovirus, hepatitis B and C viruses were negative; VDRL test was negative. Urinalysis and blood and urine cultures were also negative. Electromyography was negative for conduction abnormalities. Chest X-ray, computed tomography scan of the thorax and echocardiography showed pleural and pericardial effusions. On aspiration, pleural effusion was an exudate (protein 3.0 g/dl); leukocyte content was  $1200$  cells/ $mm^3$  with lymphocyte predominance and no eosinophils. Fluid cytology, acid-fast staining microscopy and cultures were negative for microorganisms or neoplastic cells.

A full thickness skin-muscle surgical biopsy of the left calf disclosed vascular distension in the dermis and thickening of collagen fibers and collagenous diaphragms. There was an inflammatory reaction between muscle fibers, prominent thickening of muscle fascia, fibrosis and perivascular accumulation of lymphocytes, eosinophils and few neutrophils [Figure].

Based on the biopsy results the case was diagnosed as eosinophilic fasciitis, and treatment with prednisolone 75 mg/day was instituted. Within the next few days, rapid resolution of fever and arthralgias and gradual remission of pleural and pericardial effusions were noted. Hemoglobin and ESR returned

ESR = erythrocyte sedimentation rate



Muscle surgical biopsy; vascular distension in the dermis and thickening of collagen fibers and collagenous diaphragms; inflammatory reaction between muscle fibers with thickening of muscle fascia, fibrosis and perivascular accumulation of lymphocytes, eosinophils and few neutrophils (H&E stain)

to normal. Prednisolone was gradually tapered to 4 mg/day for 6 months and after 3 more months it was discontinued. Two years later the patient remains in complete remission without recurrence of symptoms.

---

### COMMENT

Eosinophilic fasciitis is characterized by acute or subacute development of painful induration of the skin, and subcutaneous tissues of the forearms, flank and distal legs. The hands and face are usually spared and Raynaud's phenomenon is usually absent. Arthritis, carpal tunnel syndrome, muscle pain, anemia, eosinophilia and elevated ESR are variably present, but there is a striking lack of visceral involvement [1]. An eosinophilia-myalgia syndrome associated with L-tryptophan ingestion, localized scleroderma, limited and diffuse cutaneous and systemic sclerosis and several scleroderma-like disorders must be considered in the differential diagnosis. A skin-muscle biopsy is essential for the diagnosis of this disorder and for differentiation from scleroderma in cases with multisystemic involvement. Perivascular inflammation, composed of lymphocytes, plasma cells and rare eosinophils, is observed mainly in the subcutis and deep fascia [2].

Our patient presented with an unusual combination of cutaneous involvement, arthritis and serositis. Both lower limbs

were affected; one limb first, for which she received therapy, then the other following discontinuation of steroids. Peripheral blood eosinophilia was absent; this absence is a rare finding in eosinophilic fasciitis [3], but in our case it may be attributed to the recent use of steroids for 6 months. Serositis is also rare in most series of eosinophilic fasciitis cases [4]. Interestingly, pleural effusion is occasionally described in eosinophilia-myalgia syndrome complicating L-tryptophan ingestion [5]. However, our patient denied the use of any medication; besides, she did not complain of generalized myalgias, a common symptom of eosinophilic fasciitis of this type. A similar presentation is also reported in toxic oil syndrome associated with the ingestion of denatured rapeseed oil and also after use of simvastatin. However, our patient did not have such a history. Autoimmune disorders or malignancies may also be considered in the differential diagnosis; the lack of other clinical and laboratory manifestations makes all these disorders unlikely.

In conclusion, this patient's presentation together with the results of the tissue biopsy point to eosinophilic fasciitis that also involves pleura and pericardium, a manifestation rarely reported in this disease [2]. Owing to a different therapeutic approach and prognosis of the discrete entities that are implicated in fasciitis cases, any expo-

sure to chemicals or medicines must be investigated [5]. Correlation of histology and imaging findings of the involved areas may be of help in diagnosis. The possibility of eosinophilic fasciitis with multisystem involvement or with solid tumors or blood dyscrasias must also be considered. The current elusiveness of this disorder, and the limited number of relevant series, point to the importance of reporting every documented case in order to better understand both common and uncommon manifestations of the disorder.

---

### Correspondence:

**Dr. K. Konstantopoulos**

Laikon General Hospital, Ag. Thoma 17, 11527, Athens, Greece

**Phone:** (302-10) 745-6214

**Fax:** (302-10) 778-8830

**email:** kkonstan@med.uoa.gr

### References

1. Doyle JA, Ginsburg WW. Eosinophilic fasciitis. *Med Clin North Am* 1989; 73: 1157-66.
2. Killen JW, Swift GL, White RJ. Eosinophilic fasciitis with pulmonary and pleural involvement. *Postgrad Med J* 2000; 76: 36-7.
3. Dybowski F, Neuen-Jacob E, Braun J. Eosinophilic fasciitis and myositis: use of imaging modalities for diagnosis and monitoring. *Ann Rheum Dis* 2008; 67: 572-4.
4. Bischoff L, Derk CT. Eosinophilic fasciitis: demographics, disease pattern and response to treatment: report of 12 cases and review of the literature. *Int J Dermatol* 2008; 47: 29-35.
5. Silver RM, Heyes MP, Maize JC, Quearry B, Vionnet-Fuasset M, Sternberg EM. Scleroderma, fasciitis, and eosinophilia associated with the ingestion of tryptophan. *N Engl J Med* 1990; 322: 874-81.