

# Drug Reaction with Eosinophilia and Systemic Symptoms (DRESS): A Complex Interaction of Drugs, Viruses and the Immune System

Paulo R. Criado MD<sup>1</sup>, João Avancini MD<sup>1</sup>, Claudia G. Santi MD<sup>1</sup>, Ana T. Amoedo Medrado MD<sup>2</sup>, Carlos E. Rodrigues MD<sup>3</sup> and Jozélio F. de Carvalho MD<sup>4</sup>

<sup>1</sup>Dermatology Department, Hospital das Clínicas of the Faculty of Medicine, University of São Paulo, São Paulo, Brazil

<sup>2</sup>Instituto de Medicina Especializada (IMME), feira de Santana, Bahia, Brazil

<sup>3</sup>Medicine Department, University of Fortaleza-Unifor, Ceará, Brazil

<sup>4</sup>Rheumatology Division, Hospital Universitário Prof. Edgard Santos, Federal University of Bahia, School of Medicine, Salvador, Bahia, Brazil

**ABSTRACT:** The DRESS syndrome (drug reaction with eosinophilia and systemic symptoms), also known as DIHS (drug-induced hypersensitivity syndrome), presents clinically as an extensive mucocutaneous rash, accompanied by fever, lymphadenopathy, hepatitis, hematologic abnormalities with eosinophilia and atypical lymphocytes, and may involve other organs with eosinophilic infiltration, producing damage in several systems, especially kidney, heart, lungs, and pancreas. The pathogenesis is related to specific drugs (especially the aromatic anticonvulsants), altered immune response, sequential reactivation of herpes virus, and association with some HLA alleles. Glucocorticoids are the basis for the treatment of the syndrome, which may be given with intravenous immunoglobulin and, in selected cases, ganciclovir. This article reviews current concepts regarding the interaction of drugs, viruses and immune responses during this complex adverse-drug reaction.

*IMAJ* 2012; 14: 577-582

**KEY WORDS:** drug reaction with eosinophilia and systemic symptoms (DRESS syndrome), drug-induced hypersensitivity syndrome (DIHS), exanthema, herpes virus, hepatitis, nephritis

**D**rug reaction with eosinophilia and systemic symptoms (DRESS) syndrome, also known as drug-induced hypersensitivity syndrome (DIHS), described for the first time in 1936, presents clinically as an extensive mucocutaneous rash, accompanied by fever, lymphadenopathy, hepatitis, hematologic abnormalities with eosinophilia and atypical lymphocytes, and may involve other organs with resultant damage in several systems [1].

The incidence ranges between 1 in 1000 and 1 in 10,000 exposures [2,3]. Adults are more affected than children, and although the precise incidence of drug reaction has not yet been

determined, it is much more common than Stevens-Johnson syndrome, which has an incidence of 1.2–6 cases per million persons-year, and most cases are sporadic, with no gender predilection. Recognition of this syndrome is of paramount importance, since the mortality rate is about 10%–20% and a specific therapy may be necessary [1].

## ETIOPATHOGENESIS

The exact mechanism of DRESS/DIHS remains to be determined but, in cases related to anticonvulsant drugs, three components are considered: a) deficiency or abnormality of the epoxide hydroxylase enzyme that detoxifies the metabolites of aromatic amine anticonvulsants (metabolic pathway), b) associated sequential reactivation of herpes virus family, and c) ethnic predisposition with certain human leukocyte antigen alleles (immune response) [4].

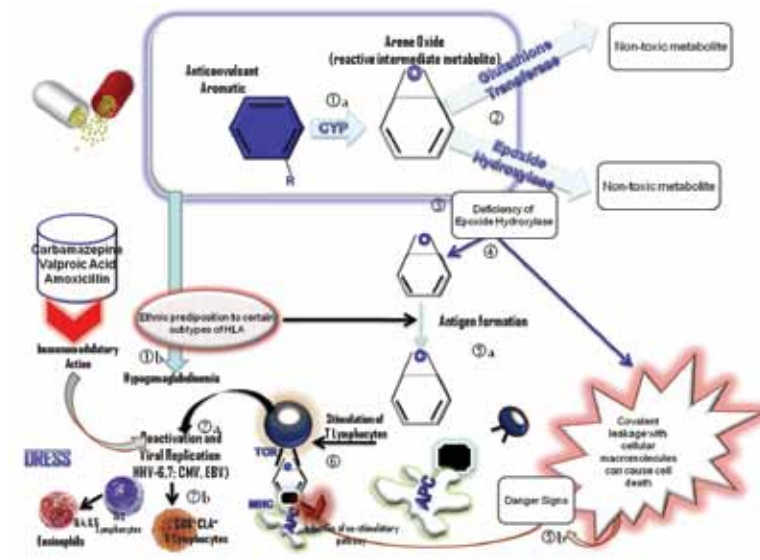
## DRUGS INVOLVED AND METABOLISM

This type of reaction is most commonly seen with seven different drug groups:

- anticonvulsants, such as the aromatic anticonvulsants (phenytoin, carbamazepine, phenobarbital, primidone), mexiletine, lamotrigine, valproate, ethosuximide, zonisamide
- antidepressants (desipramine, amitriptyline, fluoxetine)
- sulfonamides and sulfones (dapsone, sulfasalazine, trimethoprim-sulfamethoxazole, salazosulphopyridine)
- anti-inflammatory drugs (piroxicam, naproxen, diclofenac, sundilac, phenylbutazone, ibuprofen)
- anti-infectives (abacavir, cidofovir, terbinafine, nevirapine, minocycline, linezolid, doxycycline, telaprevir, nitrofurantoin, zalcitabine, spiramycin, metronidazole, piperacillin-tazobactam, ceftriaxone)
- angiotensin-converting enzyme inhibitors (captopril, enalapril)
- beta-blockers (atenolol, celiprolol)

**Figure 1.** Sequence of events of the drug-virus-immune system interaction in patients with DRESS/DIHS triggered by aromatic anticonvulsants

- [1a] Aromatic anticonvulsants are metabolized by the oxidation system of cytochrome P450 (CYP) in arene oxide radicals (intermediate reactive metabolite)
- [2] These arene oxides are detoxified by glutathione transferase and epoxide hydrolase in non-toxic metabolites
- [3] In genetically predisposed individuals or due to other factors, an impaired detoxification and accumulation of these metabolites occurs, which can cause cellular damage generating danger signs that can stimulate resting T cells, inducing co-stimulatory pathways
- [4] In addition, ethnic predisposition to certain HLA types may contribute to the formation of neoantigenes from the combination of these intermediary reactive metabolites with tissue macromolecules and formation of haptens
- [5a] Neoantigenes can be presented via the human histocompatibility complex class I (HLA-DR) or class II (HLA-A, B or C), to CD4 or CD8 T cells
- [5b] Reactive intermediate metabolites act as a danger sign and induce the pathways of co-stimulatory signs on antigen-presenting cells
- [6] It was demonstrated that carbamazepine, valproic acid and amoxicillin are able to exert immunomodulatory actions by inhibiting histone decarboxylase on B lymphocytes, producing a hypogammaglobulinemia that precedes the clinical onset of DRESS/DIHS.
- [7a] The clonal expansion of T cells requires sequential reactivation of latent herpes virus, and at the same time CD8+ CLA+ T cells are produced, which are directed towards skin
- [7b] There is a migration of CD8+ CCR4+ T cells to the lungs. Also, the production of IL4 and IL-5 by CD4+ T cells and IL-17 by CD4+Th17+ cells causes tissue and peripheral eosinophilia



- miscellaneous: allopurinol, gold salts, thalidomide, calcium channel blockers (diltiazem), ranitidine, sorbinil, azathioprine, dobutamine, methimazole, propylthiouracil and efamizulab [5].

The cases that were more consistent with DRESS/DIHS were caused by aromatic anticonvulsants, dapsone, salazosulphapyridine, allopurinol and minocycline. The cross-reactivity between the various aromatic anticonvulsant drugs is well documented, ranging from 40% to 80%.

The pathogenic mechanism of idiosyncratic reactions to drugs, such as DRESS/DIHS, has not been fully elucidated [5]. Sullivan and Shear [6] proposed a multifactorial model for the pathogen-

esis of DRESS/DIHS. Its occurrence would be determined by the combination of exposure to a drug capable of causing an adverse reaction, the dosage and the period of use in a susceptible patient.

Aromatic anticonvulsants such as carbamazepine, phenytoin and phenobarbital are metabolized by the hepatic cytochrome P450 (CYP) enzymes and undergo oxidation by aromatic hydroxylation, with subsequent formation of arene oxides. Arene oxides are toxic reactive intermediaries that are normally enzymatically converted to non-toxic metabolites by epoxide hydroxylase or glutathione transferase. In addition, spontaneous conversion to non-toxic phenol derivatives can occur. In cases of defective or deficient epoxide hydroxylase, arene oxides can accumulate and cause direct cellular toxicity or immune response [Figure 1].

### SEQUENTIAL REACTIVATION OF HERPES VIRUS IN DRESS/DIHS

Several clinical similarities that can be observed between DRESS/DIHS and infectious mononucleosis suggest a possible range of viruses as triggers for this syndrome. In addition, this syndrome has unique features that are not necessarily typical of a drug reaction. These include: a) late onset in relation to introduction of the causative medication, b) clinical signs and laboratory values suggesting a viral infection, and c) episodes of exacerbation, despite withdrawal of the offending drug [7].

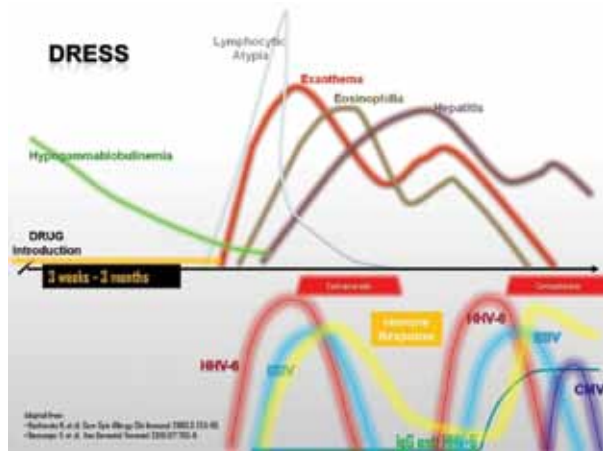
Although there are conflicting views on the pathogenesis of DRESS/DIHS in different parts of the world, recent studies have suggested a close relationship between human herpes virus 6 and the development of DRESS/DIHS [8,9]. Sporadic reports have shown that not only HHV-6, but also other herpes viruses such as HHV-7, Epstein-Barr virus and cytomegalovirus can be reactivated during the course of DRESS/DIHS [10,11].

Results obtained with polymerase chain reaction analysis showed that various herpes viruses are sequentially reactivated during the course of DRESS/DIHS in most patients. The cascade of viral reactivation is initiated by EBV or HHV-6 and extends over a period, followed by HHV-7 reactivation and eventually CMV proliferation [12]. In some patients, the clinical manifestations of this syndrome persist despite discontinuation of the drug, coinciding with the reactivation of herpes virus, as shown in Figure 2.

The reactivation of HHV-6 is evidenced by increased levels of immunoglobulin-G anti-HHV-6 DNA, and HHV-6 is commonly found in the second or third week after the rash onset, despite the high variability of clinical manifestations among patients with this drug reaction [7]. Since the reactivation of HHV-6 can be detected only in patients with DRESS/DIHS, but not other adverse drug reactions, as observed in a Japanese study,

HHV = herpes virus  
 EBV = Epstein-Barr virus  
 CMV = cytomegalovirus

**Figure 2.** DRESS/DHIS: successive events following drug exposure, symptoms onset and viral replication



this diagnostic test has become sensitive and specific for the diagnosis of all patients with DRESS/DIHS [8]. The detection of HHV-6 reactivation seems to be the gold standard diagnostic test for DRESS/DIHS in Japan, other Asian countries and Europe, helping to confirm the identification of this condition [7].

What remains unclear is the role of herpes virus in early DRESS/DIHS. There are two possibilities: DRESS/DIHS begins as an “allergic” immune reaction to a particular drug, which seems to possess an innate ability to stimulate T cells [13,14]. In the context of T cell activation a massive activation of herpes virus occurs in these cells, since the stimulation of T cells by the drug may reactivate the viral genome in the cell. Thus, the drug in turn can activate a specific cellular and humoral immune response to herpes virus.

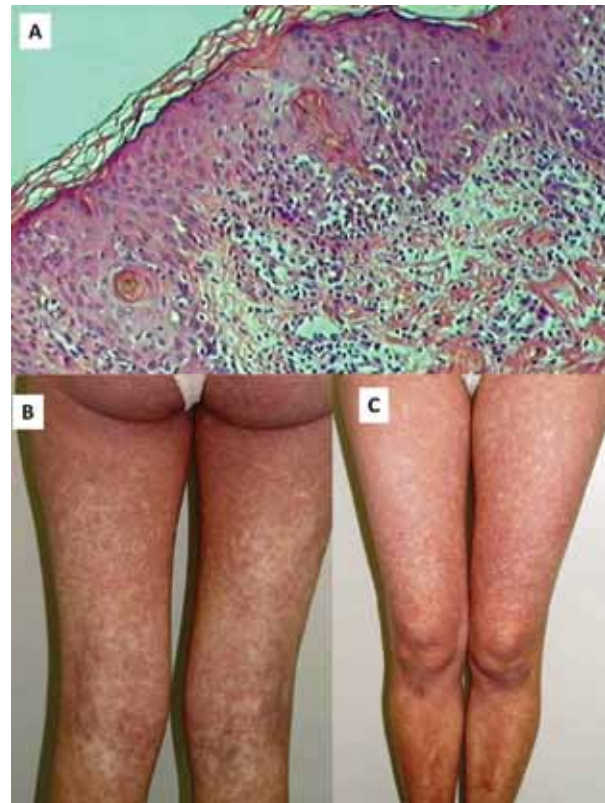
The viral reactivation can occur but is initially not clinically apparent. However, T cells stimulated by the virus present a significant cross-reactivity with certain drugs, and exposure to these drugs leads to an expansion of T cells specific to the drug (and viruses), which persists even after drug withdrawal due to persistence of viral antigens.

### IMMUNE ASPECTS INVOLVED IN DRESS/DIHS

Patients with DRESS/DIHS have decreased total serum IgG, IgA and IgM, and B lymphocyte count at onset [15,16], while there is an increase of memory T cells that cross-react with both drug and virus. Several cytokines are increased during DRESS/DIHS. In particular, levels of tumor necrosis factor-alpha and interleukin-6, which are typical pro-inflammatory cytokines, are elevated in this syndrome before the reactivation of HHV-6 [17]. Interestingly, IL-6 becomes undetectable during viral replication and increases again after the infection in most patients [17].

IL = interleukin

**Figure 3.** Clinical and histopathological findings in a patient with DRESS due to dapsone during leprosy treatment. [A] Epidermis showing spongiosis, apoptotic keratinocytes, exocytosis of lymphocytes and inflammatory infiltrate in the superficial dermis (hematoxylin & eosin, x 200 original magnification). [B and C] Exanthema in DRESS in a 26 year old Caucasian woman



- DRESS/DIHS is an entity distinct from other serious adverse drug reactions due to the dynamic changes in the immune response observed during the course of the disease. The phenotype of circulating CD4+ T cells is changed to CD8+ phenotype at the time of viral reactivation. Regulatory T cells are initially increased in number in the circulation and skin, but decrease, in parallel, in functional deterioration of the different organs or systems.
- Although the terms DRESS and DIHS are often and mistakenly used interchangeably, it is currently believed that DIHS represents the most severe cases of DRESS, with reactivation of HHV-6 detected in a large majority of patients and only in a limited number of patients with DRESS [18,19].

### HISTOPATHOLOGY

Histopathology of the skin shows a diffuse dense or superficial and perivascular lymphocytic infiltrate. Eosinophils in the dermis or swelling may or not be present [Figure 3A]. Sometimes

there is a band-like infiltrate with atypical lymphocytes simulating epidermotropism mycosis fungoides [20].

Fernando et al. [21] described a patient with DRESS/DIHS triggered by carbamazepine; a biopsy of the rash revealed an unusual form of superficial perivascular inflammatory infiltrate, in which tiny granulomas along with a moderate number of lymphocytes were observed.

Thus, biopsies of organs involved in DRESS/DIHS, such as skin and liver, in a significant number of patients may demonstrate the true frequency of granulomatous infiltration in the disease and help us understand the pathogenesis of the reaction [21].

### SYMPTOMS AND SIGNS

The syndrome usually develops within 2 months after drug introduction, more often 3 weeks to 3 months after the introduction of the drug, or less if the drug is readministered [8]. Fever, often high (38–40°C), which is the most common symptom (seen in 90–100% of cases), and rash (87% of cases) are the first signs, especially when related to antiepileptic drugs [22,23-27]. The cutaneous eruption consists of a morbilliform rash, which is indistinguishable from the rash of other less severe reactions [Figure 3 B and C]. The face, upper trunk and upper extremities are affected initially, occurring in about 90% of cases, with subsequent progression to the lower extremities, and an erythrodermic rash may develop [5].

The maculopapular eruption later becomes infiltrated with edematous follicular accentuation. Swelling of the face, with marked periorbital involvement, is a clue to the diagnosis, occurring in about 25% of patients, and can be so intense that the patient becomes disfigured. Over time the rash becomes purplish on the lower limbs and the result is scaling [5,25]. Another form of presentation is exfoliative dermatitis, which may be associated with mucosal involvement, such as cheilitis, erosions, pharyngitis and enanthematous enlarged tonsils [20,28]. Bilateral edema and infiltration of the salivary glands with xerostomia has been reported frequently [22].

Lymphadenopathy is common (70–75% of cases), limited to the lymph nodes or generalized and painful, gradually resolving with withdrawal of the drug [22].

Various hematologic abnormalities are present, including marked leukocytosis, eosinophilia (30% of cases) and atypical lymphocytes similar to mononucleosis [20,22]. These

findings guide the diagnosis toward DRESS; however, it may sometimes be difficult to distinguish it from viral infections such as Epstein-Barr virus or hematologic diseases.

Leukocytosis may be high, up to 50,000 leukocytes/mm<sup>3</sup>, and eosinophilia reaches higher than 20,000/mm<sup>3</sup> [20]. The eosinophilia may determine the involvement of internal organs with pulmonary infiltrates. In general, eosinophilia may be observed about 1 to 2 weeks after the onset of the syndrome or may even occur after the increase in liver enzymes has normalized [29]. Hemophagocytic syndrome is rarely observed in the course of DRESS/DIHS and is associated with and triggered by various conditions, including viral infections, particularly EBV, malignant tumors, or autoimmune diseases.

Multiorgan involvement may include a wide variety of organs and systems with myocarditis/myositis, pericarditis, interstitial nephritis (11% of cases), necrotizing granulomatous vasculitis in kidney, brain involvement (encephalitis or meningitis), colitis and thyroiditis [20,29].

Liver involvement is the most common visceral manifestation (50–60% of patients), the second being lymphadenopathy. Hepatomegaly may constitute a finding on physical examination. Hepatitis with isolated elevation of liver transaminases is common (51% of cases), usually anicteric, but liver failure is the leading cause of death [20].

Although pulmonary involvement is rarely reported in DRESS/DIHS, interstitial pneumonia with eosinophilia is often observed among patients in whom the syndrome was triggered by minocycline [22]. Myocarditis may develop at the start of the syndrome or up to 40

days after emergence of the drug reaction. Neurological complications include meningitis and encephalitis. Meningoencephalitis occurs about 2 to 4 weeks after onset of the drug reaction, and may lead to coma, seizures,

headaches and disorders of speech, and paresis and paralysis of the cranial nerve [29].

Gastrointestinal bleeding may be an acute complication caused by ulcers due to CMV. Endoscopic examination reveals arterial bleeding from gastric ulcerations [29].

Kennebeck [30] documented the frequency of clinical manifestations and laboratory data of the anticonvulsant hypersensitivity syndrome: fever (90–100%), cutaneous eruption (87–90%), lymphadenopathy (70%), hepatitis (50–60%), hematologic abnormalities (23–50%), periorbital

**DRESS/DIHS is an adverse drug reaction caused by a group of drugs, mainly anticonvulsants, which, in addition to sulfonamides and allopurinol, can cause 10–20% mortality**

**The syndrome is characterized by a latency period ranging from 3 weeks to 3 months after introduction of the offending drug, and its course is marked by apparent sequential reactivation of human herpes virus and subsequent development of autoimmune diseases**

and orofacial edema (25%), myalgia and arthritis (20%), nephritis (11%), pharyngitis (10%) and pulmonary manifestations (9%).

The exclusion of other serious infections – particularly bacteremia, neoplastic diseases (lymphoma, leukemia, hypereosinophilic syndrome, paraneoplastic), autoimmune or connective tissue conditions (adult-onset Still’s disease, lupus erythematosus, vasculitis) – is necessary for an accurate diagnosis of DRESS/DIHS [22,31,32].

The mortality rate can reach 20%, especially in cases with advanced age, renal impairment, jaundice and hepatitis with reactivation of CMV.

### DIAGNOSTIC CRITERIA

The diagnosis is difficult since the clinical features may be incomplete or less characteristic, for example, hepatitis without rash, or merely a pulmonary infiltrate with eosinophilia. Bocquet, Bagot and Roujeau [20] were the first to propose criteria for the diagnosis of DRESS. According to these authors the diagnosis can be established if there are at least three criteria present:

- drug rash
- hematologic abnormalities (eosinophilia > 1500/mm<sup>3</sup> and presence of atypical lymphocytes)
- systemic involvement:
  - adenopathy (> 2 cm in diameter)
  - hepatitis (transaminase elevation at least twice the normal values)
  - interstitial nephritis
  - pneumonitis
  - carditis.

A Japanese group that investigated severe cutaneous adverse reactions to drugs (SCAR-J) adopted other criteria [8], as presented in Table 1. However, universal adoption of the Japanese criteria may be limited, since one of the criteria is the viral replication during the course of infection, and some tests, such as measurement of IgG titer anti-HHV-6, are not yet routinely available in all hospitals or laboratories.

Differential diagnoses include other skin eruptions induced by drugs, e.g., Stevens-Johnson syndrome and toxic epidermal necrolysis, which are characterized by diffuse small vesicles and purpuric rash.

### TREATMENT

The early recognition of adverse drug reaction and withdrawal of the offending drug is an essential step toward clinical improvement. Empirical treatment with antibiotics or anti-inflammatory

**Table 1.** Diagnostic criteria for DRESS/DIHS

1.	Maculopapular rash develops 3 weeks after start of therapy with a limited number of drugs
2.	Persistent clinical findings after drug withdrawal
3.	Fever (> 38°C)
4.	Hepatic abnormalities (alanine aminotransferase > 100 U/L)
5.	Leukocyte abnormalities (at least one of the following) <ul style="list-style-type: none"> <li>• Leukocytosis (&gt; 11,000/mm<sup>3</sup>)</li> <li>• Atypical lymphocytosis (&gt; 5%)</li> <li>• Eosinophilia (&gt; 1500/mm<sup>3</sup>)</li> </ul>
6.	HHV-6 reactivation The diagnosis is confirmed by the presence of all seven (typical DIHS) or the first five criteria (atypical DIHS)
7.	Lymphadenopathy

\* This can be replaced by other organ involvement such as renal involvement

† Reactivation is detected from the second to third week after symptom onset, through IgG anti-HHV-6 titer elevation

drugs should not be administered during the acute disease as they may confuse or worsen the clinical picture of patients due to an unexplained cross-reactivity between drugs [8].

For many years, the treatment of DRESS was based on systemic glucocorticoids (dose ≥ 1 to 1.5 mg/kg/day of prednisone or equivalent) which lead to a marked amelioration of symptoms and laboratory parameters several days after the start of treatment [8,20,22]. If symptoms get worse despite the use of oral corticosteroids, other options reported in case series are pulsed methylprednisolone (30 mg/kg/day intravenously for 3 days), intravenous immunoglobulin [33], and plasmapheresis, or a combination of these [8]. It should be remembered that the immunosuppressive therapies may increase the risk of infectious complications and sepsis.

Cases of mild disease can be resolved simply by withdrawal of the drug and supportive treatment after a few weeks, even without the use of corticosteroids.

The French Society of Dermatology published the results of a consensus of experts on the therapeutic management of DRESS/DIHS [34]:

- absence of signs of severity: topical glucocorticoids (potent or

very potent), emollients, H1-antihistamines

- presence of signs of severity (transaminases > 5 times normal renal organic, pneumonia, hemophagocytosis, cardiac, etc.): glucocorticoids equivalent to 1 mg/kg per day of prednisone, and multidisciplinary evaluation

- life-threatening signs (hemophagocytosis with bone marrow failure, encephalitis, severe hepatitis, renal failure, respiratory failure): steroids generally associated with IVIG at a dose of 2 g/kg over 5 days. IVIG should not be proposed

IVIG = intravenous immunoglobulin

without associated steroids. These treatments must be conducted through multidisciplinary evaluation

- presence of signs of severity with confirmation of a major viral reactivation: combination of steroids and antiviral agents (ganciclovir) and/or IVIG.

## CONCLUSION

DRESS/DIHS is a challenging drug adverse reaction where the drug, the immune system and reactivation of previous viral infections may interact causing a life-threatening condition. Clinicians must be alert to this possibility in order to reach the correct diagnosis and institute the appropriate management.

### Corresponding author:

**Dr. P.R. Criado**

Rua Carneiro Leão 33, Vila Scarpelli - Santo André, São Paulo – Brazil 09050-430

**email:** prcriado@uol.com.br

### Acknowledgment

J.F. Carvalho received grants from Federico Foundation and CNPq (300665/2009-1)

### References

- Piñana E, Lei SH, Merino R, et al. DRESS-syndrome on sulfasalazine and naproxen treatment for juvenile idiopathic arthritis and reactivation of human herpesvirus 6 in an 11-year-old Caucasian boy. *J Clin Pharm Ther* 2010; 35 (3): 365-70.
- Shear NH, Spielberg SP. Anticonvulsant hypersensitivity syndrome. In vitro assesment of risk. *J Clin Invest* 1988; 82: 1826-32.
- Fiszenson-Albala F, Auzevie V, Mahe E, et al. A 6-month prospective survey of cutaneous drug reactions in a hospital setting. *Br J Dermatol* 2003; 149: 1018-22.
- Bohan KH, Mansuri TF, Wilson NM. Anticonvulsant hypersensitivity syndrome: implications for pharmaceutical care. *Pharmacotherapy* 2007; 27(10): 1425-39.
- Ganeva M, Gancheva T, Lazarova R, et al. Carbamazepine-induced drug reaction with eosinophilia and systemic symptoms (DRESS) syndrome: report of four cases and brief review. *Int J Dermatol* 2008; 47(8): 853-60.
- Sullivan JR, Shear NH. The drug hypersensitivity syndrome: what is the pathogenesis? *Arch Dermatol* 2001; 137: 357-64.
- Shiohara T, Kano Y. A complex interaction between drug allergy and viral infection. *Clin Rev Allerg Immunol* 2007; 33: 124-33.
- Shiohara T, Inaoka M, Kano Y. Drug-induced hypersensitivity syndrome (DIHS): a reaction induced by a complex interplay among herpesviruses and anti-drug immune responses. *Allergol Int* 2006; 55: 1-8.
- Picard D, Janela B, Descamps V, et al. Drug reaction with eosinophilia and systemic symptoms (DRESS): a multiorgan antiviral T cell response. *Sci Transl Med* 2010; 2(46): 46-62.
- Oskay T, Karademir A, Ertürk OI. Association of anticonvulsant hypersensitivity syndrome with Herpesvirus 6. *Epilepsy Res* 2006; 70(1): 27-40.
- Seishima M, Yamanaka S, Fujisawa T, Tohyama M, Hashimoto K. Reactivation of human herpesvirus (HHV) family members other than HHV-6 in drug-induced hypersensitivity syndrome. *Br J Dermatol* 2006; 155(2): 344-9.
- Kano Y, Hirahara K, Sakuma K, Shiohara T. Several herpesviruses can reactivate in a severe drug-induced multiorgan reaction in the same sequential order as in graft-versus-host disease. *Br J Dermatol* 2006; 155(2): 301-6.
- Naisbitt DJ, Farrell J, Wong G, et al. Characterization of drug-specific T-cells in lamotrigine hypersensitivity. *J Allergy Clin Immunol* 2003; 111: 1393-403.
- Wu Y, Sanderson JR, Farrel J, et al. Activation of T cells by carbamazepine and carbamazepine metabolites. *J Allergy Clin Immunol* 2006; 118: 233-41.
- Kano Y, Inaoka M, Shiohara T. Association between anticonvulsant hypersensitivity syndrome and human herpesvirus 6 reactivation and hypogammaglobulinemia. *Arch Dermatol* 2004; 140: 183-8.
- Aihara Y, Ito SI, Kobayashi Y, Yamakawa Y, Aihara M, Yokota S. Carbamazepine-induced hypersensitivity syndrome associated with transient hypogammaglobulinaemia and reactivation of human herpesvirus 6 infection demonstrated by real-time quantitative polymerase chain reaction. *Br J Dermatol* 2003; 149(1): 165-9.
- Yoshikawa T, Fujita A, Yagami A, et al. Human herpesvirus 6 reactivation and inflammatory cytokine production in patients with drug-induced hypersensitivity syndrome. *J Clin Virol* 2006; 37( Suppl 1): S92-6.
- Tohyama M, Hashimoto K. New aspects of drug-induced hypersensitivity syndrome. *J Dermatol* 2011; 38(3): 228-8.
- Shiohara T, Iijima M, Ikezawa Z, Hashimoto K. The diagnosis of a DRESS syndrome has been sufficiently established on the basis of typical clinical features and viral reactivations. *Br J Dermatol* 2007; 156: 1083-4.
- Bocquet H, Bagot M, Roujeau JC. Drug-induced pseudolymphoma and drug hypersensitivity syndrome (Drug Rash With Eosinophilia and Systemic Symptoms: DRESS). *Semin Cutan Med Surg* 1996; 1: 250-7.
- Fernando SL, Henderson CJ, O'Connor KS. Drug-induced hypersensitivity syndrome with superficial granulomatous dermatitis – a novel finding. *Am J Dermatopathol* 2009; 31: 611-13.
- Gentile I, Talamo M, Borgia G. Is the drug-induced hypersensitivity syndrome (DIHS) due to herpesvirus 6 infection or to allergy-mediated viral reactivation? Report of a case and literature review. *BMC Infect Dis* 2010; 10: 49. Available on <http://www.biomedcentral.com/1471-2334/10/49>.
- Criado PR, Lucena SK, Crivellaro APGS, et al. Drug hypersensitivity syndrome to anticonvulsants: report of two cases. *Rev Bras Clin Terap* 2002; 28: 59-63.
- Aires NB, Criado PR, Vilela MAC, et al. Drug hypersensitivity syndrome to anticonvulsants: report of three cases. *Diagn Tratamento* 2006; 11(2): 86-90.
- Criado PR, Criado RF, Vasconcellos C, Pegas JR, Cera PC. Drug-induced hypersensitivity syndrome due to anticonvulsants in a two-year-old boy. *J Dermatol* 2004; 31(12): 1009-13.
- Vittorio CC, Muglia JJ. Anticonvulsant hypersensitivity syndrome. *Arch Intern Med* 1995; 155: 2285-90.
- Chang DKM, Shear NH. Cutaneous reactions to anticonvulsants. *Semin Neurol* 1992; 12: 329-37.
- Eshki M, Allamore L, Musette P, et al. Twelve year analysis of severe cases of drug reaction with eosinophilia and systemic symptoms. *Arch Dermatol* 2009; 145: 67-72.
- Kano Y, Ishida T, Hirahara K, Shiohara T. Visceral involvements and long-term sequelae in drug-induced hypersensitivity syndrome. *Med Clin North Am* 2010; 94: 743-59.
- Kennebeck GA. Anticonvulsant hypersensitivity syndrome. *J Am Board Fam Pract* 2000; 13: 364-70.
- Fittje M. Anticonvulsant hypersensitivity syndrome. *Internet J Neurol* 2001; 1 (1). Doi: 10.5580/2458
- Kossefi SG, Guha B, Nassour DN, Chi DS, Krishnaswamy G. The dapsone hypersensitivity syndrome revisited: a potentially fatal multisystem disorder with prominent hepatopulmonary manifestations. *J Occup Med Toxicol* 2006; 1: 9.
- Kito Y, Ito T, Tokura Y, Hashizume H. High-dose intravenous immunoglobulin monotherapy for drug-induced hypersensitivity syndrome. *Acta Derm Venereol* 2012; 92 (1): 100-1.
- Descamps V, Ben-Said B, Sassolas B, et al. Management of drug reaction with eosinophilia and systemic symptoms (DRESS). *Ann Dermatol Venereol* 2010; 137(11): 703-8.