Metastatic Solitary Fibrous Tumor to the Pancreas Causing Non-islet Cell Tumor Hypoglycemia

Gal Aviel MD[1], Victoria Doviner MD[4], Rivka Pollak-Dresner MD[2], Avraham Rivkind MD[3] and Shmuel Chen MD PhD[5]

Departments of [1]Cardiothoracic Surgery, [2]Endocrinology and Metabolism and [3]General Surgery, Hadassah–Hebrew University Medical Center, Ein Kerem Campus, Jerusalem, Israel
[4]Department of Pathology, Shaare Zedek Medical Center, Jerusalem, Israel
[5]Cardiovascular Research Foundation, Columbia University Medical Center, New York, NY, USA

KEY WORDS: hypoglycemia, meningioma, non-islet cell tumor hypoglycemia (NICTH), solitary fibrous tumor (SFT), IGF-2

IMAJ 2020; 22: 119–121

We present a case of Doege-Potter syndrome caused by a metastatic solitary fibrous tumor (SFT) of the pancreas. This case had an unusual chain of events and several confounders. After a careful review of the patient's history we found that he first presented with a smoldering intracranial neoplastic disease. Over two decades, the intracranial tumor sent distant metastases, including to the pancreas, and that when they increased in size, caused paraneoplastic hypoglycemic events.

PATIENT DESCRIPTION

A 64-year-old patient with a history of meningiomas was admitted to our hospital due to severe hypoglycemia (serum blood glucose < 50 mg/dl). His medical history consisted of recurrent angioblastic meningiomas, first diagnosed two decades prior to the current presentation. These tumors had been treated by repeated surgical resections and adjuvant radiation. Ten years prior to presentation, the patient underwent kidney transplantation due to cryptogenic end-stage renal disease. Five years later a routine ultrasonographic scan of the abdomen revealed multiple retroperitoneal masses that required distal pancreatectomy and a splenectomy for resection. Complete resection was not possible due to tumor encasement of the superior mesenteric artery, so the head of the pancreas was left intact. The pathological diagnosis was consistent with a SFT.

The patient was diagnosed with non-insulin-dependent diabetes over a decade earlier, but had stopped oral hypoglycemic therapy one year prior to current presentation, having attained complete normalization of glucose without medical therapy. Once the patient was asymptomatic and normoglycemic, he started a fast. Six hours later, the patient became agitated and began sweating. Laboratory tests showed plasma glucose 20 mg/dl and reduced levels of insulin (< 14.4 pmol/L, normal range 36–180) and C-peptide (54 pmol/L, normal range 165–993). Dextrose was administered providing immediate relief of the patient's symptoms.

Low levels of both insulin and C-peptide indicated a hypoglycemic episode that was not mediated by endogenous insulin. This combination narrowed the differential diagnosis to surreptitious hypoglycemia, non-islet cell tumor-induced hypoglycemia (NICTH) or to other medical causes of hypoglycemia (e.g., renal failure or Addison's disease). We therefore extended the endocrine profile to include also insulin-like growth factor (IGF)-1, growth hormone (GH), and IGF-binding protein 3 (IGF-BP3), which are all suppressed in NICTH. The level of IGF-1 was < 3.25 nmol/L (normal 10–26 nmol/L), the level of IGFBP-3 was 1.74 nmol/L (normal 2–5.5 nmol/L), and the GH level was 0.93 ng/ml (normal 0.5–17 ng/ml).

Contrast-enhanced computed tomography scan revealed a large heterogenous retroperitoneal mass, measuring approximately 16.6 cm × 12 cm, occupying the head of the pancreas and pushing the abdominal viscera ventrally. Multiple right lung nodules were also apparent [Figure 1].

Since the patient had a history of meningiomas, a rare diagnosis of SFT, and endocrine abnormalities that could not be attributed to any known clinical syndrome, we were either facing an as-yet-unreported syndrome of a tendency for malignancy or that both tumors were essentially of the same origin. Therefore, all pathological specimens obtained from previous surgeries dating back to the patient's first neurosurgical operation were reviewed by expert pathologists. The meningeal, pancreatic, and retroperitoneal tumors were found to be identical and consistent with an SFT [Figure 1]. Surprisingly, the tumor did not change its pathological characterization over the years. Moreover, all the pathological specimens were strongly positive for IGF-2, further supporting the diagnosis of NICTH.

The patient was evaluated for surgery but was deemed inoperable due to a high operative risk. During a follow-up of 1 year, he remained euglycemic and symptom-free as long as he adhered to the 20 mg daily prednisone treatment.

COMMENT

SFT is a rare mesenchymal neoplasm that was first described in 1870. Histologically, it is known to exhibit a patternless growth pattern with bland short spindle-cell cytology, alternating hypercellular and hypocellular areas separated by thin bands of collagen, and many thin-walled staghorn branching vessels. The diagnosis of SFT is

Figure 1. Histological and immunohistochemical features of meningeal and intra-abdominal tumors. **[A–C]** Meningeal tumors. **[D]** Intra-abdominal tumor (2007). Note the similar histology (Hematoxylin and Eosin), the comparable proliferative index (MIB-1) and the identical IGF2 expression (original magnification ×200). **[E]** An axial abdominal computed tomography with intravenous contrast enhancement, demonstrating a large heterogenous retroperitoneal mass, measuring approximately 16.6 × 12 cm, pushing the peritoneal contents ventrally

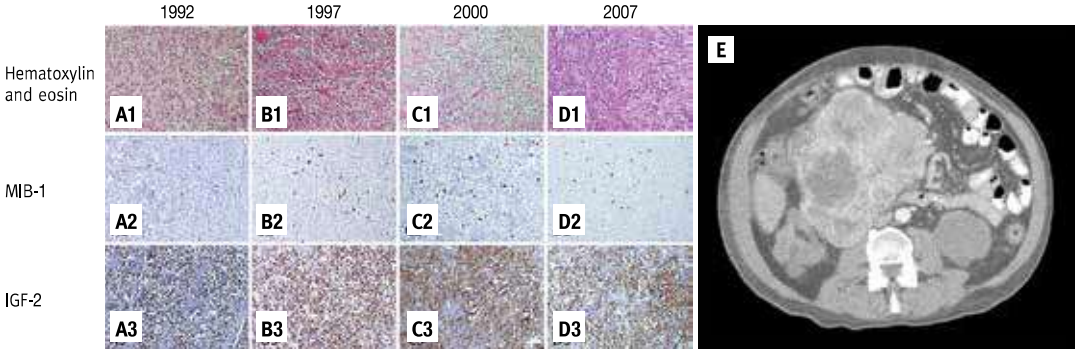

supported by immunohistochemical analysis for CD34, vimentin, CD99, and B-cell lymphoma protein 2 and by negative staining for desmin, cytokeratins, and S-100 [1,2]. SFTs usually follow a benign clinical course, but 10–15% exhibit malignant behavior and may recur and metastasize after surgical resection.

NICTH is a rare paraneoplastic syndrome that is associated with tumors of mesenchymal origin and leads to the release of IGF-2. SFT-induced paraneoplastic hypoglycemia, known as Doege-Potter syndrome, occurs in fewer than 5% of patients and resolves after surgical resection [2]. As with other NICTH, SFT-induced hypoglycemia is thought to be mediated through an aberrant form of IGF-2 called "big" IGF-2, that is overproduced by the tumor cells.

IGF-1 and IGF-2 are structurally similar to insulin and bind to the IGF-1 receptor, through which they recapitulate many of insulin's activities, but with only 1–2% of its potency [3]. Normally, 70–80% of circulating IGF-2 is bound to IGFBP-3 and the acid-labile subunit (ALS), forming a biologically inactive 150-kD complex. A partially processed big IGF-2 is incapable of forming the inactive complex, thus becoming biologically potent. Ligand binding to IGF-1 receptor causes increased glucose uptake and metabolism by fat and muscle tissues leading to hypoglycemia and decreased gluconeogenesis. Big IGF-2 is also responsible for the suppression of the hepatic secretion of IGF-1, IGFBP-3, ALS and pituitary GH.

Although the initial differential diagnosis of hypoglycemia is broad, the gradual normalization of glucose levels in a known diabetic patient together with symptoms suggesting a mass effect, such as abdominal discomfort and early satiety, made the diagnosis of tumor-induced hypoglycemia very probable.

While our patient was hypoglycemic, low levels of insulin and C-peptide suggested NICTH. This likely diagnosis was further supported by the co-existence of low levels of IGFBP-3 and IGF-1 and low-normal GH levels, all of which are direct consequences of the effects of big IGF-2.

The patient was discharged with a medicine regimen of 20 mg/day oral prednisone and remained euglycemic and symptom-free. Glucocorticoids have been shown to be effective in attaining a normoglycemic state in patients with NICTH [4]. They have demonstrated beneficial effects on the biochemical abnormalities caused by tumor-derived big IGF-2 through several mechanisms, as reported by Teale and Marks [4]. These mechanisms include a reduction in both the total and aberrant IGF-2 and restoration of the ternary inactive complex by increased levels of ALS.

The patient underwent two trials of tapering the steroid dosage that culminated in his developing two severe symptomatic hypoglycemic events, which necessitated hospitalization. When it was adjusted to the previous dosage of 20 mg/day prednisone, he remained euglycemic and symptom free.

In addition to NICTH caused by a pancreatic SFT, the patient's medical history also consisted of recurrent meningiomas and hyperparathyroidism. A number of case reports have shown that SFT might be mistaken for meningiomas [5]. We therefore had all of the patient's pathological specimens reviewed to confirm the diagnosis of SFT based on histological and immunohistochemical evaluation. Interestingly, it was apparent that all the pathological specimens dating back to his first neurosurgical operation 20 years earlier were actually identical. These results were further supported by staining for the relevant immunohistochemical markers as well as for IGF-2. All pathological slides displayed the same moderate to high cellularity, lacking atypical features (such as nuclear atypia, high mitotic activity, or necrosis) and thus were consistent with a diagnosis of SFT. Moreover, both the mitotic and the proliferative indexes showed only minimal variations. The original inaccurate diagnosis of an intracranial neoplasm was corrected from an angioblastic meningioma to an SFT.

For a patient who presents with hypoglycemia, a plausible etiology can be deduced from the history, physical exami-

nation, and laboratory data. If a patient is medicated, the diagnoses of drug-induced hypoglycemia or critical illness should be ruled out. Levels of insulin, C-peptide, and proinsulin should be measured during a hypoglycemic episode (either spontaneous or provoked). If these are suppressed and surreptitious insulin use is excluded, a diagnosis of NICTH has to be ruled out. Low measurements of plasma concentration of GH, IGF-1, and IGF-BP3 should be used as indirect markers of aberrant IGF-2. If these are low, the diagnosis of NICTH is highly likely and further work-up should be performed.

CONCLUSIONS

Metastatic SFT is a rare entity and its paraneoplastic syndromes are even more uncommon. Because SFTs remain a diagnostic challenge and are often misconstrued as other common neoplasms, clinicians and radiologists encountering NICTH should investigate the following if encountering a similar patient.

Hypoglycemia in the context of decreased levels of insulin, proinsulin, C-peptide, IGF-1, and IGFBP-3 suggest a diagnosis of NICTH. Serum glucose, IGF-2. and GH levels should also be investigated. Unexplained hypoglycemia is a potential paraneoplastic phenomenon. Surgical resection of the tumor can solve the clinical manifestations. SFTs should be considered when heterogeneous hyper vascular tumors present in the head and neck region. SFTs present with few symptoms in the early stage of the disease, and their diagnosis must rely on careful and thorough histopathological analysis to distinguish them from other intracranial disease entities. Patients who have received a diagnosis of SFT should be under strict and long-term surveillance given the potential for malignant transformation.

Correspondence
Dr. G. Aviel
Dept. of Cardiothoracic Surgery,
Hadassah–Hebrew University Medical Center,
Ein Kerem Campus, Jerusalem 91120, Israel
Fax: (972-2) 643-1021
email: galav@hadassah.org.il

References

1. Gengler C, Guillou L. Solitary fibrous tumour and haemangiopericytoma: evolution of a concept. *Histopathology* 2006; 48: 63-74.
2. Park MS, Araujo DM. New insights into the hemangiopericytoma/solitary fibrous tumor spectrum of tumors. *Curr Opin Oncol* 2009; 21: 327-31.
3. Maki RG. Small is beautiful: insulin-like growth factors and their role in growth, development, and cancer. *J Clin Oncol* 2010; 28: 4985-95.
4. Teale JD, Marks V. Glucocorticoid therapy suppresses abnormal secretion of big IGF-II by non-islet cell tumours inducing hypoglycaemia (NICTH). *Clin Endocrinol (Oxf)* 1998; 49: 491-8.
5. Ng HK, Choi PC, Wong CW, To KF, Poon WS. Metastatic solitary fibrous tumor of the meninges. Case report. *J Neurosurg* 2000; 93: 490-3.

Capsule

Autism risk in offspring can be accessed through quantification of male sperm mosaicism

De novo mutations arising on the paternal chromosome make the largest known contribution to autism risk, and correlate with paternal age at the time of conception. The recurrence risk for autism spectrum disorders is substantial, leading many families to decline future pregnancies, but the potential impact of assessing parental gonadal mosaicism has not been considered. **Breuss** and co-authors measured sperm mosaicism using deep-whole-genome sequencing, for variants both present in an offspring and evident only in father's sperm, and identified single-nucleotide, structural and short tandem-repeat variants. The authors found that mosaicism quantification can stratify autism spectrum disorders recurrence risk due to de novo mutations into a vast majority with near 0% recurrence and a small fraction with a substantially higher and quantifiable risk, and they identify novel mosaic variants at risk for transmission to a future offspring. This suggests, therefore, that genetic counseling would benefit from the addition of sperm mosaicism assessment.

Nature Medicine 2020; 26: 143

Eitan Israeli

Capsule

Embryonal precursors of Wilms tumor

Adult cancers often arise from premalignant clonal expansions. Whether the same is true of childhood tumors has been unclear. To investigate whether Wilms tumor (nephroblastoma; a childhood kidney cancer) develops from a premalignant background, **Coornes** et al. examined the phylogenetic relationship between tumors and corresponding normal tissues. In 14 of 23 cases studied (61%), the authors found premalignant clonal expansions in morphologically normal kidney tissues that preceded tumor development. These clonal expansions were defined by somatic mutations shared between tumor and normal tissues but absent from blood cells. They also found hypermethylation of the *H19* locus, a known driver of Wilms tumor development, in 58% of the expansions. Phylogenetic analyses of bilateral tumors indicated that clonal expansions can evolve before the divergence of left and right kidney primordia. These findings reveal embryonal precursors from which unilateral and multifocal cancers develop.

Science 2019; 366: 1247

Eitan Israeli