

Transvaginal Natural Orifice Transluminal Endoscopic (vNOTES) Hysterectomy Learning Curve: Feasibility in the Hands of Skilled Gynecologists

Roy Lauterbach MD, Emad Matanes MD, Amnon Amit MD, Zeev Wiener MD MHA and Lior Lowenstein MD MS MHA MBA

Department of Obstetrics and Gynecology, Rambam Health Care Campus, affiliated with Rappaport Faculty of Medicine, Technion, Haifa, Israel

ABSTRACT: **Background:** During Transvaginal Natural Orifice Transluminal Endoscopic Surgery (vNOTES) the surgeon operates exclusively through a single vaginal entry point, leaving no external scarring.

Objectives: To evaluate the learning curve of vNOTES hysterectomy by experienced gynecologists based on surgical times and short-term outcomes.

Methods: A retrospective study was conducted of the first 25 vNOTES hysterectomy surgeries performed from July to December 2018 at Rambam Health Care Campus by a single surgeon. The primary outcome was hysterectomy time. Secondary outcomes included intra-operative bleeding, length of hospitalization, postoperative pain, and need for analgesia. Socio-demographic and clinical data were retrieved from patient electronic medical charts.

Results: Median age was 64.5 years (range 40–79). Median hysterectomy time was 38 minutes (range 30–49) from the first cut until completion. Comparisons between median hysterectomy time in the first 10 hysterectomies and in the 15 subsequent procedures demonstrated a significant decrease in median total time: 45 minutes (range 41–49) vs. 32 minutes (range 30–38), respectively ($P = 0.024$). The median estimated intraoperative blood loss decreased from 100 ml (range 70–200) in the first 10 hysterectomies to 40 ml (range 20–100) in the subsequent procedures ($P = 0.011$).

Conclusions: vNOTES hysterectomy is feasible by an experienced gynecologist, with an exponential improvement in surgical performance in a short period as expressed by the improvement in hysterectomy time, low complication rates, negligible blood loss, minimal post-surgical pain, fast recovery, and short hospitalization. vNOTES allows easier and safer access to adnexal removal compared to conventional vaginal surgery.

IMAJ 2020; 22: 13–16

KEY WORDS: hysterectomy, transvaginal, Transvaginal Natural Orifice Transluminal Endoscopic Surgery (vNOTES)

tomy (AH), vaginal hysterectomy (VH), total laparoscopic hysterectomy (TLH), laparoscopy-assisted VH (LAVH), multiport robotic assisted laparoscopic, and robotic laparo-endoscopic single-site hysterectomy.

A summary of 47 randomized controlled trials in over 5000 female patients in the Cochrane database recommended VH as the preferred technique in female patients undergoing hysterectomy for benign indications in whom VH is feasible. In cases in which VH is of low preference, TLH is recommended as an alternative approach with the cost of increased risk of urinary tract injury [1].

According to the database of the Israeli Ministry of Health, the age-adjusted hysterectomy rate per 100,000 women aged 25 years and older in 2016 was 236, with a 48% rate of AH, 25% rate of VH, and the rest either laparoscopy-assisted or robotic-assisted hysterectomies.

Transvaginal Natural Orifice Transluminal Endoscopic Surgery (vNOTES) uses the natural female orifice as the surgical access route. vNOTES was performed first in 2012 in Yorkshire pigs to evaluate post-surgical restoration of gastrointestinal motility [2] but was implemented in humans by the Belgian group led by Jan Baekelandt from the Imelda Hospital in Bonheiden, Belgium, in 2015 and has since evolved to include not just hysterectomy but also several other gynecological surgeries including adnexectomy, myomectomy, and ovarian cystectomy, and treatment of ectopic pregnancy [3–8].

During the past 3 years both Turkish and Chinese groups have presented their experience with vNOTES, the latter describing sacrocolpopexy via vNOTES approach [9–10].

The aim of the current article was to evaluate the learning curve of vNOTES hysterectomy by experienced gynecologists, based on surgical times and short-term outcomes from the first 25 cases of vNOTES hysterectomy in Israel.

PATIENTS AND METHODS

STUDY PROTOCOL

The study was approved by the institutional Helsinki ethics committee. We reviewed the medical charts of the first 25 female patients who had undergone vNOTES hysterectomy due

Hysterectomy is the most common major surgical procedure performed in the field of gynecology. Currently, there are six surgical approaches to hysterectomy: abdominal hysterectomy

to menorrhagia and endometrial hyperplasia, at the Rambam Healthcare Campus, between July and December 2018. The procedures were performed by a single gynecologist (LL) assisted by two residents.

The information retrieved from the patient electronic files included socio-demographic data, parity, previous pelvic/abdominal surgery, concomitant surgical procedures including adnexectomy, anterior/posterior colporrhaphy, and transvaginal obturator suburethral tape, hysterectomy time, estimated blood loss, postoperative pain, need of analgesia, and length of hospitalization.

SURGICAL TECHNIQUE

The first step for vNOTES is entering the peritoneal space anteriorly through the vesicovaginal space and posteriorly to the cul de sac. While retracting the lateral vaginal wall and countertraction on the cervix, the uterosacral ligaments are exposed, clamped, incised, and sutured.

vNOTES

The next steps are the placement of the Alexis (Alexis® O™ Retractor by Applied Medical Resources Corporation, Rancho Santa Margarita, CA, USA) and the GELpoint (GELpoint® by Applied Medical Resources Corporation, Rancho Santa Margarita, CA, USA) port into the vagina. Three trocars are inserted into the port as demonstrated in Figure 1. Instruments

include a LigaSure (LigaSure™ by Metronic, Minneapolis, MN, USA) and a clinch grasper.

GRASPER

Using the grasper, contralateral traction is placed on the cervix in an effort to identify the anterior and posterior leaves of the broad ligament, after which the uterine vessels are identified, sealed, and cut by the LigaSure dissector.

Next, the fallopian tubes are removed with or without ovaries. The decision is based on patient preference and medical indication. The procedure is performed by infundibulopelvic ligament or ovarian ligament cauterization and cutting, respectively.

STATISTICAL ANALYSIS

Statistical analyses were performed using IBM Statistical Package for the Social Sciences statistics software, version 19 (SPSS, IBM Corp, Armonk, NY, USA). Since histograms indicated that the variables of interest were normally distributed, we used parametric statistical methods to analyze the data. Independent *t*-test was used for comparison of continuous variables. Tests were considered statistically significant at a $P < 0.05$.

RESULTS

OVERALL VIEW

The median age of our participants was 64.5 years (range 35–74). Patient demographics and baseline data are presented in Table 1. In addition to vNOTES hysterectomy, 23 of the 25 patients underwent bilateral salpingo-oophorectomy and 2 underwent bilateral salpingectomy alone. Eleven patients underwent concomitant prolapse repair procedures and 3 underwent stress urinary incontinence (SUI) repair procedures

Figure 1. vNOTES GELpoint and instrument insertion through trocars

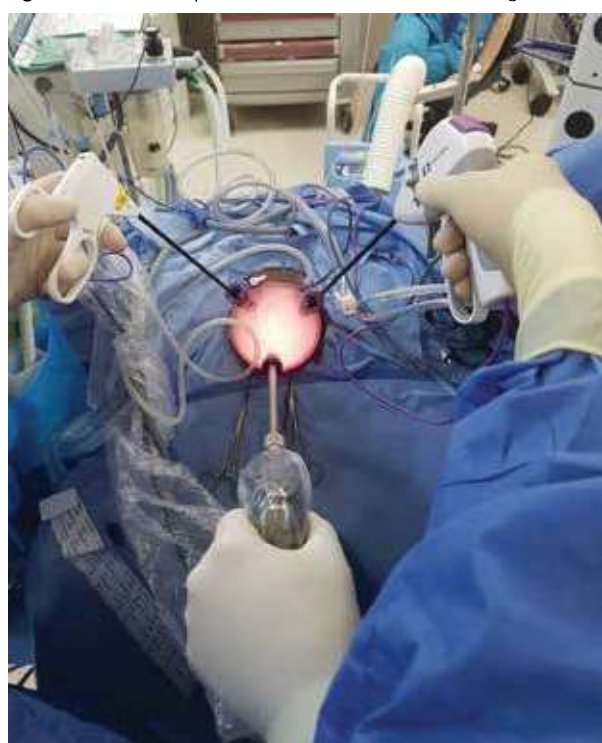

Table 1. Socio-demographic data, medical history, and concomitant surgeries

Characteristic	Value
Age in years, median (range)	64.5 (35–74)
Parity, median (range)	4 (1–6)
BMI, kg/m ² , median (range)	27.5 (21–38.5)
Hypertension, number (%)	11 (44%)
Hyperlipidemia, number (%)	8 (32%)
Cardiac disease, number (%)	4 (16%)
Diabetes, number (%)	6 (24%)
Previous pelvic/abdominal surgery, number (%)	5 (20%)
Concomitant surgeries	
Bilateral salpingo-oophorectomy, number (%)	23 (92%)
Bilateral salpingectomy, number (%)	2 (8%)
Anterior colporrhaphy, number (%)	3 (12%)
Posterior colporrhaphy, number (%)	4 (16%)
SUI repair surgery-TVT-O, number (%)	3 (12%)

BMI = body mass index, SUI = stress urinary incontinence, TVT-O = transvaginal obturator suburethral tape

Table 2. Intra- and postoperative data

Characteristics	Values
Hysterectomy time, minutes, median (range)	38 (30–49)
Bleeding, ml, median (range)	55 (20–200)
Pain assessment (VAS: 0–10), median (range)	3 (0–5)
Demand for analgesics	
P.O Paracetamol, number (%)	11 (44%)
P.O Dipyrone, number (%)	14 (56%)
Opioids, number (%)	0 (0)
Intravenous analgesics, number (%)	0 (0)
Number of times analgesics were used, median (range)	2 (0–4)
Length of hospital stay, median (days)	2

IV = intravenous, P.O = per os, VAS = visual analog scale

[Table 2]. All hysterectomies and adnexectomies were carried out to completion laparoscopically with no conversions to conventional vaginally or laparotomy. Mean uterine size was 7 cm (range 6.5–12 cm). The Median hysterectomy time was 38 minutes (range 30–49) from first cut to completion of hysterectomy including GELpoint port insertion. The median estimated intraoperative blood loss was 55 ml (range 20–200). There were no intraoperative adverse events.

One patient was re-admitted due to abdominal pain. The patient was diagnosed with ileus and treated with analgesics for 2 days after which the patient had a bowel movement and was discharged. Hospital stay for all patients was 2 days with no differences among patients. The median postoperative visual analog scale (VAS) pain score was 3 (range 0–5), on a 10-point scale (0–10). None of the patients required postoperative analgesic treatment with opioids or intravenous analgesics. Median analgesic treatment use was 2 (range 0–4) [Figure 2].

LEARNING CURVE

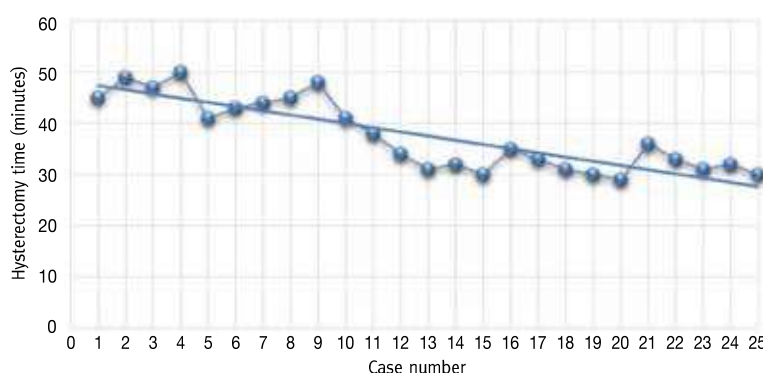
In a comparison of the first 10 procedures and the sequential 15 procedures, we found median total hysterectomy time decreased from 45 minutes (range 41–50) in the first 10 hysterectomies to 32 minutes (range 30–38) in the 15 sequential procedures ($P = 0.024$) [Figure 2]. In addition, estimated blood loss decreased from 100 ml (range 70–200) in the first 10 hysterectomies to 40 ml (range 20–100) in the 15 sequential procedures ($P = 0.011$) [Figure 2]. No differences were noted in pain parameters, including VAS pain assessment, and the number of times analgesics were used and in hospitalization length.

DISCUSSION

Previous studies regarding vNOTES surgery have described the experiences of single centers. To the best of our knowledge, this is the first article describing the learning curve of vNOTES surgery by a surgical team with previously laparoscopic experience. In addition, this is the first paper to publish surgical experience with vNOTES hysterectomies in Israel.

Figure 2. vNOTES learning curve

	Procedures 1–10	Procedures 11–25	P value
Hysterectomy time, minutes, median (range)	45 (41–50)	32 (30–38)	0.024
Bleeding, ml, median (range)	100 (70–200)	40 (20–100)	0.011
Pain assessment (VAS: 0–10), median (range)	3.5 (1–5)	4 (0–5)	0.47
Number of times analgesics were used, median (range)	2 (1–3)	2 (1–3)	0.85
Length of hospital stay, median (days)	2	2	1.00



Indicent Student's *t*-test, $P < 0.05$ for significance

The trend-line demonstrates a decrease in median total hysterectomy time between the first 10 procedures and the sequential 15 procedures, 45 minutes (range 41–50) vs. 32 minutes (range 30–38), respectively ($P = 0.024$)

VAS = visual analog scale

The results of the current study portray the feasibility and extremely low complication rate of vNOTES hysterectomy. The experience in our surgical center with the first 25 vNOTES hysterectomies showed significant improvement in the learning curve between the first 10 surgeries and the subsequent 15 surgeries. This manifested in a reduction of one-third of the time required for vNOTES hysterectomy in addition to a reduction of one-half in estimated blood loss. Of importance is the fact that all surgeries were performed by an experienced laparoscopic surgeon.

In a comparison between vNOTES and VH/LAVH, surgical times in the latter two surgical approaches are comparable with a median surgical time of 29 minutes [11]. There were no intraoperative adverse events. One case of post-surgical ileus was documented and treated conservatively without further complications. The median estimated intraoperative blood loss was 55 ml. This amount is comparable to that of previously published robotic-assisted gynecological procedures [12–14]. In our opinion, one of the main advantages of vNOTES is the access, visualization, and feasibility of adnexal removal, a long-known challenge for gynecological surgeons performing vaginal hysterectomies.

Another remarkable advantage of vNOTES surgery is precise visualization of the ureters, enabling surgeons to perform salpingo-oophorectomy to a higher degree of confidence and the ability to avoid intraoperative urinary tract injury.

Furthermore, the aesthetic advantage and prevention of surgical scar complications is an advantage that is emphasized by most female patients. In addition, the natural access through the vagina adds to laparoscopic procedure safety by preventing possible trocar insertion accidents.

In terms of hospitalization length, randomized control trials have shown that vNOTES allows a larger group of women to be treated in a day-care setting in addition to less patient discomfort and short time until recovery to day-to-day activities [3-4].

DISADVANTAGES OF VNOTES SURGERY

Disadvantages of the vNOTES procedure include technical difficulties in performing the desired procedure in the setting of pelvic peritoneal adhesions. Furthermore, uterine size may limit the feasibility of the procedure, which is similar to limitations in LAVH, although uterine size varies among the studies, up to 15 cm in some studies [3,6,9,14-16].

LIMITATIONS

Study limitations include the limited sample size that does not reflect the true incidence of surgical complications, the cohort design with no comparative arm, and the short follow-up time. In addition, the study explored both benign and pre-malignant indications (menorrhagia and endometrial hyperplasia) for hysterectomy and did not include prolapse repair techniques via vNOTES approach such as sacrospinous/uterosacral ligament suspension or malignant indications. Although not described in the current study, vNOTES has been shown to be feasible for both of these indications [14-16].

CONCLUSIONS

vNOTES hysterectomy is a feasible technique for the treatment of benign gynecological indications with an expeditious learning curve for surgeons who have previous experience in both VH and LAVH. The complication rate is minimal.

Further studies are needed to appraise the long-term outcomes, evaluate the feasibility of the surgical technique in the hands of less experienced surgeons, and demonstrate the ultimate utility of this modality.

Correspondence

Dr. R. Lauterbach

Dept. of Obstetrics and Gynecology, Rambam Health Care Campus, Haifa 31096, Israel

email: r_lauterbach@rambam.health.gov.il

References

1. Aarts JWM, Nieboer TE, Johnson N, et al. Surgical approach to hysterectomy for benign gynecological disease. *Cochrane Database Syst Rev* 2015; (8): CD003677.
2. Córdova H, Guarner-Argente C, Martínez-Pallí G, et al. Gastric emptying is delayed in transgastric NOTES: a randomized study in swine. *J Surg Res* 2012; 174: 61-7.
3. JF Baekelandt, PA De Mulder, I Le Roy, et al. Hysterectomy by transvaginal natural orifice transluminal endoscopic surgery versus laparoscopy as a day-care procedure: a randomized controlled trial. *BJOG* 2019; 126: 105-13.
4. Baekelandt J. Total Vaginal NOTES Hysterectomy: a new approach to hysterectomy. *J Minim Invasive Gynecol* 2015; 22: 1088-94.
5. Baekelandt J, Vercammen J. IMELDA transvaginal approach to ectopic pregnancy: diagnosis by transvaginal hydrolaparoscopy and treatment by transvaginal natural orifice transluminal endoscopic surgery. *Fertil Steril* 2017; 107: e1-e2.
6. Baekelandt J. Transvaginal natural-orifice transluminal endoscopic surgery: a new approach to myomectomy. *Fertil Steril* 2018; 109: 179.
7. Baekelandt J. Transvaginal natural orifice transluminal endoscopic surgery: a new approach to ovarian cystectomy. *Fertil Steril* 2018; 109: 366.
8. Baekelandt JF, De Mulder PA, Le Roy I, et al. Transvaginal natural orifice transluminal endoscopic surgery (vNOTES) adnexectomy for benign pathology compared with laparoscopic excision (NOTABLE): a protocol for a randomized controlled trial. *BMJ Open* 2018; 8: e018059.
9. Kale A, Sariibrahim B, Başol G. Hysterectomy and salpingoophorectomy by Transvaginal Natural Orifice Transluminal Endoscopic Surgery (NOTES): Turkish surgeons' initial experience. *Int J Surg* 2017; 47: 62-8.
10. Liu J, Kohn J, Fu H, Guan Z, Guan X. Transvaginal natural orifice transluminal endoscopic surgery for sacrocolpopexy: a pilot study of 26 cases. *J Minim Invasive Gynecol* 2019; 26 (4): 748-53.
11. Sandberg EM, Twijnstra ARH, Driessen SRC, Jansen FW. Total laparoscopic hysterectomy versus vaginal hysterectomy: a systematic review and meta-analysis. *J Minim Invasive Gynecol* 2017; 24 (2): 206-17.e22.
12. Anger JT, Mueller ER, Tarnay C, et al. Robotic compared with laparoscopic sacrocolpopexy: a randomized controlled trial. *Obstet Gynecol* 2014; 123: 5-12.
13. Fanfani F, Fagotti A, Gagliardi ML, et al. Minilaparoscopic versus single-port total hysterectomy: a randomized trial. *J Minim Invasive Gynecol* 2013; 20 (2): 192-7.
14. Matanes E, Lauterbach R, Mustafa-Mikhail S, Amit A, Wiener Z, Lowenstein L. Single port robotic assisted sacrocolpopexy: our experience with the first 25 cases. *Female Pelvic Med Reconstr Surg* 2017; 23: e14-e18.
15. Oh SH, Park SJ, Lee EJ, Yim GW, Kim HS. Pelvic lymphadenectomy by vaginal natural orifice transluminal endoscopic surgery (vNOTES) for early-stage endometrial cancer. *Gynecol Oncol* 2019; 153 (1): 211-12.
16. Baekelandt JF. New retroperitoneal transvaginal natural orifice transluminal endoscopic surgery approach to sentinel node for endometrial cancer: a demonstration video. *J Minim Invasive Gynecol* 2019. pii: S1553-4650(19)30215-8.

Capsule

p53 makes a comeback

One reason that cancer cells are so difficult to kill is that they often lack p53, a key tumor suppressor that promotes apoptosis. To address this problem, Kong et al. devised a way to restore p53 gene expression in tumors by delivering p53 messenger RNA (mRNA) in nanoparticles. To minimize damage to healthy tissues, the authors used redox-responsive nanoparticles, taking advantage of the relative hypoxia

of tumors. The use of mRNA rather than DNA provided an additional safeguard because mRNA acts directly in the cytoplasm, without integrating into host cell DNA and introducing mutations. The researchers tested their approach in multiple models in vitro and in vivo, with promising results.

Sci Transl Med 2019; 11: eaaw1565

Eitan Israeli