# Correlation between Radiological and Pathological Findings for a Sudden Death Incident in the Emergency Department

Gal Yaniv MD PhD[1], Larisa Guranda MD[1], Jacob Or MD[2], Konstantin Zaitsev MD[3], Eli Konen MD[1] and Jehuda Hiss MD[3]

[1]Department of Diagnostic Imaging and [2]Emergency Department, Sheba Medical Center, Tel Hashomer, Israel
[3]National Center of Forensic Medicine, Assaf Harofeh Medical Center, Zerifin, Israel

**KEY WORDS:** autopsy, postmortem computed tomography (PMCT), aortic atherosclerotic aneurysmatic dissection, pericardial tamponade, virtopsy

*IMAJ* 2011; 13: 707–708

For centuries postmortem dissection of bodies has been the gold standard examination for establishing the cause and manner of death. Recently, new emergent modalities are finding their way to augment, supplement and reduce the invasiveness of conventional autopsy. We report a patient who died unexpectedly in a university-affiliated hospital emergency room after complaining of diarrhea, vomiting, weakness and low back pain. Before submitting the body for autopsy at the nearby forensic institute, total body computed tomography was performed. The correlation between a postmortem CT and postmortem conventional autopsy is discussed, and the availability of non-invasive autopsy techniques for various religious communities in Israel is emphasized.

## PATIENT DESCRIPTION

A 58 year old man with no previous medical history was referred to the emergency department because of diarrhea, vomiting, weakness and low back pain after eating in a restaurant. The patient did not complain of fever, chest or abdominal pain. Vital signs, such as blood pressure, heart rate, body temperature and saturation, were within normal limits. Physical examination was without pathological findings. Chest X-ray showed cardiac silhouette in the upper range while abdominal X-ray was unremarkable. Laboratory examination disclosed microscopic hematuria, leukocytosis of 16,140 (88% neutrophils) and serum creatinine of 1.7 (upper normal limit 1.2 mg/dl).

With the provisional diagnosis of gastroenteritis and mild acute prerenal failure, the patient was admitted to the Observation Unit and was treated with intravenous fluids and oral ciprofloxacin. A few hours later the patient suddenly collapsed and after prolonged cardiopulmonary resuscitation death was determined.

### RADIOLOGY

Full-body CT was performed at the hospital 2 hours after the death. The skull and neck showed no specific findings. Chest CT demonstrated pericardial effusion, 2.7 cm thick, along with a blood clot attached to the epicardial surface [Figure A]. The ascending aorta was collapsed with the lateral wall of the aortic arch and proximal descending aorta thickened and hyperdense. A small calcification was noted within the aortic arch lumen, separated from the aortic wall [Figure B]. These findings were suggestive of dissection of the thoracic aorta with pericardial tamponade. In addition, the presence of gas seen within the heart chambers, the pulmonary trunk and the brachio-cephalic veins was consistent with postmortem artifact.

### AUTOPSY FINDINGS

External examination of the body was unremarkable. Internal examination of the cranial vault and abdominal cavity did not show any acute or chronic pathological findings. Exposure of the pericardial cavity revealed 350 ml of bloody fluid and blood clots. The heart weighed 430 g, and the major branches of coronary arteries showed moderate atherosclerotic changes. The ascending thoracic aorta, 2 cm above the aortic valve, had a 9 cm long and 5 cm wide aneurysmatic dilatation, with two irregular full-thickness lacerations, 1.5 cm long, leading into the pericardial sac [Figure C]. The peri-adventitial aortic soft tissues were suffused with blood.

The remaining thoracic and abdominal aorta was affected by calcified and ulcerated atheromata, without significant narrowing or dilatation of the lumen. Microscopic examination of the aortic aneurysm revealed dissection of the media, infiltrated by blood. The myocardium showed tiny scars and intercellular fibrosis, with slight hypertrophy of myocytes. Toxicological examination was negative.

## COMMENT

Adaptation of advances in radiology to the postmortem examination may help to gradually complement the conventional autopsy technique. These technologies include CT scans, magnetic resonance

**[A]** Axial section of PMCT demonstrates thick pericardial effusion, compatible with clotted blood (arrow)

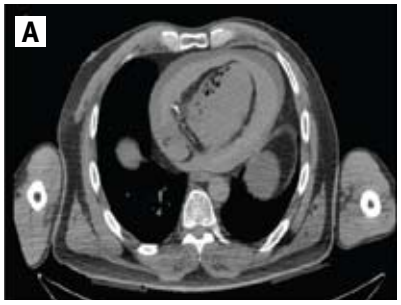


**[B]** Axial section of PMCT demonstrates hyperdense and thickened aortic wall, with a small separated calcification indicating aortic dissection

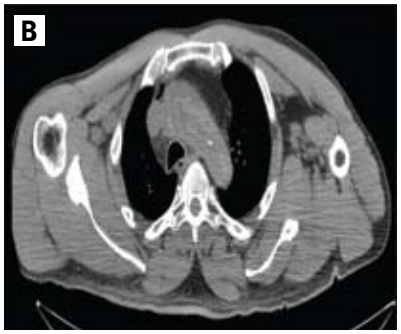


**[C]** Mediastium in situ: anterior aspect of the heart with ascending aorta. Note ruptured aneurysmatic dilatation of the aortic wall


imaging and postmortem angiography [1].

The CT examination has proven to be a valuable tool in forensic pathology. While in conventional autopsy the body cannot be reassembled, postmortem imaging allows for the examination of the corpse in its natural state, with no need for dissection of the different organs. The data of the postmortem imaging can be stored digitally, which makes it easier to be retrieved, analyzed and reconstructed according to the examiner's request [2]. PMCT has been shown to be superior to conventional autopsy mainly in the detection of fractures and foreign bodies, as well as visualization of free gas in the cadaveric tissues and blood vessels [3]. Thus, a total body scan prior to autopsy is an important complement in diagnosing and saves time for the forensic pathologist. Providing a precise guide for invasive examination of the region of interest at complicated anatomic sites, such as parts of the skeleton for retrieval of foreign bodies, allows for a less extensive dissection.

PMCT, however, does have several disadvantages, such as poor soft tissue discrimination, poor visualization of the circulation, and lack of information on histology, microbiology or toxicology. However, PMCT-guided biopsies, MR-spectroscopy and new and promising results in postmortem angiography [4] may well minimize these disadvantages.

Conventional autopsies have been facing increased opposition in recent years, mainly on religious grounds since preservation of the intact body is a fundamental principle of many faiths. However, the need for delineating the cause of death in criminal investigations or cases of sudden and unexpected deaths remains constant.

In the present case, PMCT analysis was accurate in diagnosing the cause of death (acute aortic dissection followed by pericardial tamponade), confirmed later by conventional autopsy. Intracardiac and intravascular free air, which in clinical radiology would be considered pathological, are known postmortem phenomena, and cautious interpretation is required.

The radiologists at Sheba Medical Center have gained considerable experience in the field of PMCT by conducting 27 examinations over the last 4 years. However, it is important to clarify that the virtual autopsy does not replace the traditional postmortem examination, but rather supplements it. The use of different imaging modalities postmortem can potentially help to improve our medical practice. It is imperative to continue collaborating with the forensic sciences for further improvement of these important and necessary postmortem techniques.

PMCT = postmortem computed tomography

**Corresponding author:**
**Dr. L. Guranda**
Dept. of Diagnostic Imaging, Sheba Medical Center, Tel Hashomer 52621, Israel
**Phone:** (972-3) 530-2530
**Fax:** (972-3) 535-7315
**email:** larisa.guranda@sheba.health.gov.il

## References

1. Bolliger SA, Thali MJ, Ross S, Buck U, Naether S, Vock P. Virtual autopsy using imaging: bridging radiologic and forensic sciences. A review of the virtopsy and similar projects. *Eur Radiol* 2008; 18 (2): 273-82.
2. Pomara C, Fineschi V, Scalzo G, Guglielmi G. Virtopsy versus digital autopsy: virtual autopsy. *Radiol Med* 2009; 114 (8): 1367-82.
3. Scholing M, Saltzherr TP, Fung Kon Jin PH, et al. The value of postmortem computed tomography as an alternative for autopsy in trauma victims: a systematic review. *Eur Radiol* 2009; 19 (10): 2333-41.
4. Ross S, Spendlove D, Bolliger S, et al. Postmortem whole-body CT angiography: evaluation of two contrast media solutions. *AJR Am J Roentgenol* 2008, 190 (5): 1380-9.

**"We are usually convinced more easily by reasons we have found ourselves than by those which have occurred to others"**

Blaise Pascal (1623-1662), French philosopher and mathematician

**"Don't mistake pleasure for happiness. They're a different breed of dog"**

Josh Billings (1818-1885), American columnist and humorist