Stent-Assisted Thrombolysis in Acute Tandem Carotid and Middle Cerebral Arteries Occlusion

Jose E. Cohen MD[1,3], Ronen R. Leker MD[2], Shai Rosenberg MD PhD[2], David Arkadir MD PhD[2] and Eyal Itshayek MD[1]

Departments of [1]Neurosurgery, [2]Neurology and [3]Radiology, Hadassah-Hebrew University Medical Center, Jerusalem, Israel

KEY WORDS: carotid dissection, stroke, stent, thrombolysis

IMAJ 2010; 12: 767–769

For Editorial see page 762

Intravenous thrombolysis was reported as an alternative treatment, safe and effective, within 3 hours after onset of stroke due to dissection [1]. However, tandem occlusion independently predicts poor outcome after IVT [2]. Recently, stent-assisted endovascular thrombolysis has been performed with some success in patients with acute tandem occlusion and internal carotid artery dissection [3,4]. We report a case of ICA dissection and occlusion combined with middle cerebral artery embolic occlusion, causing a major stroke, which was successfully treated with multiple self-expandable cervical and intracranial stents and intraarterial thrombolysis.

IVT = intravenous thrombolysis
ICA = internal carotid artery

PATIENT DESCRIPTION

A 45 year old right-handed man was admitted to our hospital 2.25 hours after an acute episode of aphasia, right-sided hemiplegia, hypoesthesia, and hemianopsia followed by deterioration in consciousness. The National Institutes of Health Stroke Scale (NIHSS) score was 22. His medical history was unremarkable. Head computed tomography demonstrated subtle hypodensity of the left insular ribbon, lentiform nucleus, corona radiata, and body of caudate nucleus, with hemispheric cortico-subcortical sparing. Cervical and cerebral CT angiography revealed complete occlusion of the left ICA and occlusion of the left MCA. The left anterior cerebral artery was visible, with the left ICA supplying both ACAs.

The patient was intubated and angiography was started 4 hours after symptom onset. Endovascular treatment was performed under general anesthesia with an 8F access sheath placed in the right femoral artery. Selective angiography of the left common carotid artery showed a flame-like ICA occlusion and confirmed the diagnosis of ICA dissection [Figure A]. Left hemispheric circulation as analyzed on the right carotid angiogram showed that the A1 segment of the left ACA and the T segment of the left ICA were filled via the anterior communicating artery [Figure B]. The left MCA was occluded at the origin of the lateral lenticulostriate arteries [Figure B].

MCA = middle cerebral artery
ACA = anterior cerebral artery

At the beginning of the procedure the patient received a 2500 IU heparin bolus intravenously. After passing the occluded left ICA dissection with a Vasco microcatheter (Balt, Montmorency, France) and a 0.014 inch guide wire (Transend, Boston Scientific, USA), urokinase (1,600,000 units total dose) was infused at the MCA occlusion [Figure C]. After 40 minutes, angiography showed a complete proximal recanalization of the MCA with residual filling defects in MCA branches. Embolic occlusions of MCA branches were mechanically removed with the aid of a thromboaspiration device (Penumbra

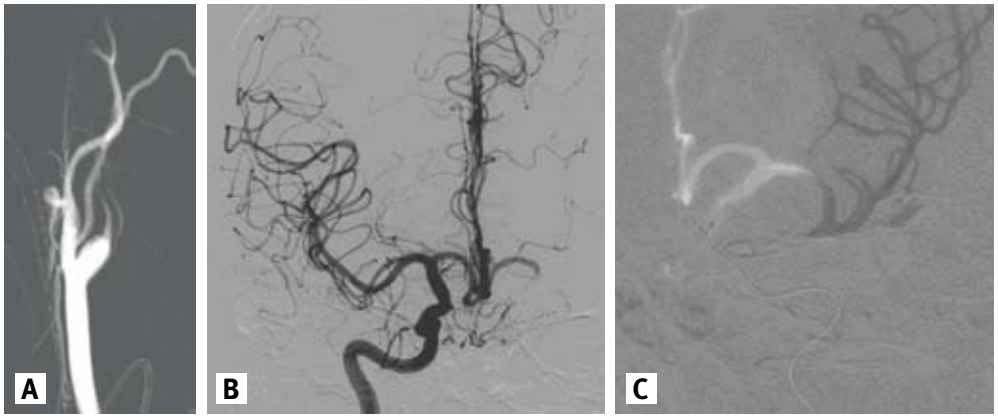

[A] Left carotid angiogram, lateral view. Left ICA presents a complete occlusion in a flame-like pattern, usually associated with arterial dissection
[B] Right ICA angiogram, anteroposterior view, shows limited contrast crossover to the left hemisphere due to MCA tandem occlusion
[C] Under road mapping, a microcatheter is navigated through the dissected L-ICA and reaches the MCA occlusion. Dark-contrasted image shows the MCA branches distal to the occlusion

System, Alameda, CA, USA). ICA recanalization was achieved after implantation of two self-expandable microstents (Leo stent, Balt, Montmorency, France) and a nitinol carotid stent, in a telescoped fashion, to fully cover the petrous and cervical portions of the ICA [Figures D & E]. There was no periprocedural complication. Head CT scan did not show any hemorrhagic transformation, and the patient received clopidogrel (300 mg loading dose followed by 75 mg daily) and aspirin (100 mg daily). He was transferred to the intensive care unit and was extubated the day after interventional therapy. At the end of day 1, he was alert and oriented, presented moderate pure motor dysphasia and moved his four limbs without paresis. CT scan follow-up showed petechial hemorrhages in the frontotemporal area as a sign of reperfusion of the MCA [Figure F]. On day 6, the patient presented isolated motor dysphasia and was discharged on clopidogrel for 3 months and aspirin indefinitely. He had a favorable outcome at 30 days follow-up (NIHSS 2, modified Rankin scale 1).

COMMENT

Our patient, presenting with tandem occlusion and ICA dissection within 3 hours after ischemic symptom onset, was eligible for IVT. However, in the presence of tandem occlusion, ICA occlusion reduces the delivery of recombinant tissue plasminogen activator into the thrombus in the MCA. Furthermore, hemodynamic mechanisms are significant after a major vessel occlusion and may be at least as crucial as thrombotic ones. For all these reasons, and because of the poor chance of revascularization with IVT, we decided on an endovascular approach combining endovascular revascularization and intraarterial thrombolysis. It must be stressed that most cases of ICA dissection do not need endovascular treatment. Most ischemic events secondary to ICA dissection are embolic and thus anticoagulation is usually indicated in the early stages of the disease.

Recently, endovascular treatment with stent deployment for ICA dissection has been proposed in selected cases with hemodynamic stenosis or when anticoagulation failed to prevent embolic stroke [5]. Additionally, stent-assisted endovascular thrombolysis was recently used with some success in a group of patients who had acute tandem occlusion following dissection [3,4].

Lavallée et al. [3] compared the clinical outcomes of 10 consecutive patients presenting with tandem occlusion and ICA dissection within 3 hours after symptom onset, treated by either endovascular stent-assisted thrombolysis (6 patients) or intravenous rt-PA when an endovascular therapist was unavailable (4 patients). Before treatment, mean NIHSS scores were high and comparable in the two groups, but the 3 month outcome was worse in the IVT group. In the endovascular group, four patients (66.6%) had a favorable outcome (mRS = 0), while three patients (75%) in the intravenous rt-PA group had a poor outcome (mRS ≥ 3).

There are three major benefits of endovascular stent-assisted thrombolysis [5]. First, immediate recanalization of ICA blood flow allows direct access to the MCA thrombus with thrombolytic therapy. Second, the deployment of the stent along the length of dissection, covering the intimal tear, reduces the risk of early reocclusion, potential cerebral emboli, and new stroke by hemodynamic mechanisms. Third, no routine anticoagulation is required after the procedure. However, due to the stent implantation, antiplatelet therapy was necessary in this patient.

The main difficulty of treatment with stent-assisted endovascular thrombolysis is navigating the microcatheter through the true arterial lumen of the occluded segment [5]. The theoretical risks include distal embolism, vascular perforation, and enlargement of the dissection. The microcatheter placed above the level of the occlusion allowed us to inject contrast in order to be sure of its position in the true arterial lumen. Then, after achieving MCA recanalization, the same microcatheter was used for placement of

NIHSS = National Institutes of Health Stroke Scale

rt-PA = recombinant tissue plasminogen activator

mRS = modified Rankin Scale

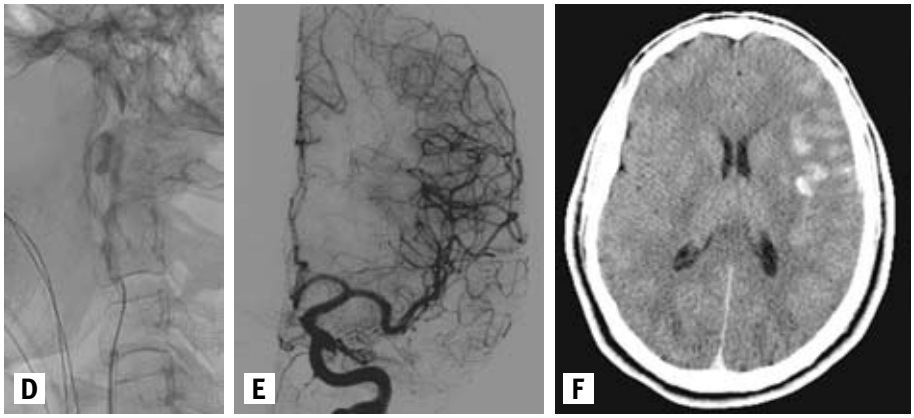

[D] Radioscopic image of the telescoped stents implanted at the petro-cervical dissection
[E] Left ICA angiogram shows complete recanalization of the MCA artery and its branches (TIMI 3)
[F] Head CT on day 2 shows petechial hemorrhages as a sign of reperfusion

the telescoped self-expandable stents at petro-cervical locations.

These stents were originally designed for stent-assisted coil embolization and are more flexible than those usually used for cervical atherosclerotic stenosis. This characteristic, associated with good vessel adaptability, adequate radial strength, and a low-profile, make the stents a good option for petro-cervical dissections.

Endovascular stent placement associated with intraarterial thrombolysis may be an immediately effective, safe and attractive alternative treatment for symptomatic tandem occlusion with ICA dissection. Further large randomized studies are required to confirm the data and determine the indication and the optimal endovascular approach.

Corresponding author:
Dr. J.E. Cohen
Dept. of Neurosurgery, Hadassah University Medical Center, P.O. Box 12,000, Jerusalem 91120, Israel
Phone: (972-2) 677-7092
Fax: (972-2) 641-6281
email: jcohenns@yahoo.com

References

1. Derex L, Nighoghossian N, Turjman F, et al. Intravenous tPA in acute ischemic stroke related to internal carotid artery dissection. *Neurology* 2000; 54: 2159-61.
2. Rubiera M, Ribo M, Delgado-Mederos R, et al. Tandem internal carotid artery/middle cerebral artery occlusion: an independant predictor of poor outcome after systemic thrombolysis. *Stroke* 2006; 37: 2301-5.
3. Lavallée PC, Mazighi M, Saint-Maurice JP, et al. Stent-assisted endovascular thrombolysis versus intravenous thrombolysis in internal carotid artery dissection with tandem internal carotid and middle cerebral artery occlusion. *Stroke* 2007; 38: 2270-4.
4. Baumgartner RW, Georgiadis D, Nedeltchev K, Schroth G. Stent-assisted endovascular thrombolysis versus intravenous thrombolysis in internal carotid artery dissection with tandem internal carotid and middle cerebral artery occlusion. *Stroke* 2008; 39: 1-5.
5. Cohen JE, Leker RR, Gotkine M, Gomori M, Ben-Hur T. Emergent stenting to treat patients with carotid artery dissection: clinically and radiologically directed therapeutic decision making. *Stroke* 2003; 34: e254-7.