IMAJ • VOL 12 • DECEMBER 2010

The Role of Diagnostic Laparoscopy in the Management of Patients with Gastric Cancer

Andronik Kapiev MD, Igor Rabin MD PhD, Ron Lavy MD, Bar Chikman MD PhD, Zahar Shapira MD, Hasan Kais MD, Natan Poluksht MD, Yaron Amsalam RN BA, Zvi Halpern MD, Ilia Markon MD, Ilan Wassermann MD and Ariel Halevy MD

Division of Surgery, Assaf Harofeh Medical Center, Zerifin, affiliated with Sackler Faculty of Medicine, Tel Aviv University, Ramat Aviv, Israel

ABSTRACT: **Background:** Gastric cancer continues to be a leading cause of cancer death. The treatment approach varies, and preoperative staging is therefore crucial since an exploratory laparotomy for unresectable gastric cancer will be followed by an unacceptably high morbidity and mortality rate.

Objectives: To assess the added value of diagnostic laparoscopy to conventional methods of diagnosis such as computed tomography in avoiding unnecessary laparotomies.

Methods: We conducted a retrospective study on 78 patients scheduled for curative gastrectomy based on CT staging. DL was performed prior to exploratory laparotomy.

Results: In 23 of 78 patients (29.5%) unexpected peritoneal spread not detected on preoperative CT was found. Fifty-five patients underwent radical gastrectomy, 15 patients were referred for downstaging and 8 patients underwent a palliative procedure.

Conclusions: Based on our results, DL should be considered in all gastric cancer patients scheduled for curative gastrectomy.

IMAJ 2010; 12: 726–728

KEY WORDS: gastric cancer, diagnostic laparoscopy, staging, curative gastrectomy preoperative staging

Although a decrease in the incidence of gastric cancer has been documented in recent decades, it is still a leading cause of cancer death [1-6]. The incidence of GC in Israel has not changed significantly during the last decade, ranging from around 600 to 650 new cases per year [7].

The treatment approach to patients with GC varies from resection for cure, resection for palliation, and palliative procedures such as a bypass or installation of a feeding jejunostomy, to referring patients in advanced stages for neoadjuvant therapy (downstaging) prior to surgery [2,3,5,6]. Thus, preoperative staging is of the utmost importance because an exploratory laparotomy not followed by radical surgery due to unresectability or metastatic spread will be followed by considerable morbidity and mortality (13–23% and 10–36% respectively) [2,3,5,6,8].

Diagnostic laparoscopy for staging and evaluation of resectability in patients with GC has been used in some series with similar conclusions [1,5,8-10], supporting DL prior to surgery. The aim of the present study was to assess the added value of DL to conventional methods of diagnosis such as computed tomography in avoiding unnecessary laparotomies.

PATIENTS AND METHODS

This was a retrospective study based on 361 GC patients operated on at Assaf Harofeh Medical Center. Data were retrieved from patient charts and a computerized database was built. The study was approved by the Institutional Review Board. All patients underwent a CT prior to surgery. Patients diagnosed with stage IV disease or unresectable tumors were excluded from the study. Hence, only patients scheduled for curative surgery were included. DL was performed on the day of surgery and/or a few days prior to surgery in patients suspected of having borderline unresectable tumors.

OPERATIVE TECHNIQUE

The peritoneal cavity was insufflated to 15 mmHg and two trocars (10 and 5 mm) were introduced. Any suspicious lesion was biopsied and sent for frozen section, and if ascites was present the fluid was collected and sent for cytology. In cases found to be positive, surgery was deferred.

RESULTS

DL was performed in 78 GC patients. The 39 men and 39 women ranged in age from 39 to 89 years. The tumor was located in the upper third of the stomach including the gastroesophageal junction (Siewert Type II, III) in 12 patients, in the middle third of the stomach in 13, and in the lower third in 27. In three patients, the diagnosis was linitis plastica.

In 55 patients (70.5%) the DL was judged negative and all 55 underwent curative resections: proximal gastrectomy in 7 patients, total gastrectomy in 17, and subtotal gastrectomy in 31.

In 23 patients (29.5%), unexpected peritoneal spread

DL = diagnostic laparoscopy
GC = cancer death

Figure 1. Clinical data

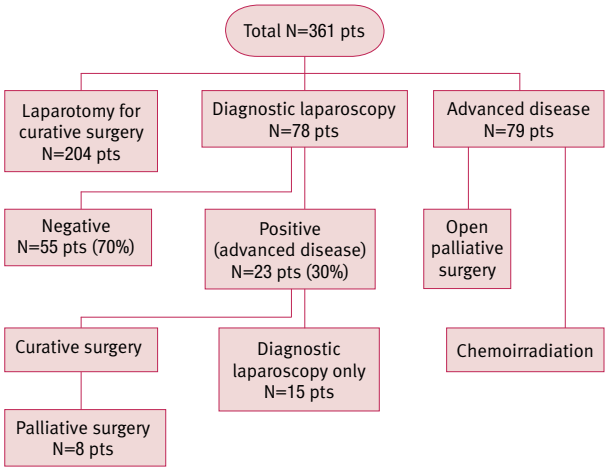

not detected on preoperative CT was found. In this group of patients the tumor was located in the upper third of the stomach in nine patients, in the middle third in five patients and in the lower third in six. Linitis plastica was diagnosed in three patients. In 15 patients, the operation stopped at the level of DL and all 15 patients were referred for further treatment, while the other 8 patients underwent a palliative procedure [Figure 1]. There were no complications directly related to the DL.

DISCUSSION

One of the reasons for performing a diagnostic laparoscopy before surgery for gastric cancer patients is to prevent unnecessary laparotomies, which are followed by unacceptable morbidity and mortality rates [2,3,5,6,8].

In our study, 23 of 78 patients (29.5%) who underwent a DL as the first stage of a planned curative resection were found to have metastatic spread. In the other 55 patients in whom the DL was negative, we proceeded to radical surgery. Our data regarding the added value of DL in gastric cancer patients is similar to other reported series [4,8-10].

Although the radiological investigation performed for the group of patients with small peritoneal metastases yields a high rate of accuracy, a considerable percentage of patients are under-diagnosed or under-staged by CT and it is precisely this group of patients that would benefit from a DL, thereby avoiding a futile laparotomy. Furthermore, with the current approach of neoadjuvant treatment for advanced stage disease, the introduction of DL would lead to a quicker referral of patients to oncology treatment [1,4,6,10-12].

Of the 78 patients judged by CT to be operable, 23 (29.5%) were actually understaged by CT and metastatic peritoneal spread was found on DL. Eight patients in this group underwent a palliative procedure either for bleeding or obstructing symptoms, while the other 15 were referred for oncology treatment with the intent of downstaging and possible future surgery based on the laparoscopic findings. In the other 55 patients, the DL findings correlated with the laparotomy findings and all these patients underwent curative surgery.

It is important to stress that no complications could be directly related to the DL procedure as most of the patients who did not have surgery were released from hospital the next day.

Although DL in patients with GC has been practiced for many years, the overall number of patients in each reported series is small. Nevertheless, the results support this approach [1,5,8-10]. Since the accuracy rate of positron emission tomography CT in GC patients has not yet been proven [13,14], and taking into account the low but inevitable understaging by CT, we believe that DL has a place in the management of patients with GC by preventing unnecessary laparotomies on the one hand and better selecting patients for neoadjuvant treatment on the other.

In conclusion, DL can reduce the rate of unnecessary laparotomies in advanced-stage GC patients, despite its drawbacks. DL is superior to CT for patients with GC who have peritoneal metastases. In addition, it is a simple procedure with a low complication rate. We believe that DL should be performed as a first-stage procedure in patients scheduled for gastrectomy with curative intent, especially in Israel, since two-thirds of our patients present at an advanced stage of the disease (stage III and IV, 75%) [15].

Corresponding author:
Dr. A. Halevy
Division of Surgery, Assaf Harofeh Medical Center, Zerifin 70300, Israel
Phone: (972-8) 977-9560
Fax: (972-8) 977-9225
email: fredricag@asaf.health.gov.il

References

1. Blackshaw GR, Barry JD, Edwards P, Allison MC, Thomas GV, Lewis WG. Laparoscopy significantly improves the perceived preoperative stage of gastric cancer. *Gastric Cancer* 2003; 6: 225-9.
2. Yano M, Tsujinaka T, Shiozaki H, et al. Appraisal of treatment strategy by staging laparoscopy for locally advanced gastric cancer. *World J Surg* 2000; 24: 1130-5, discussion 1135-6.
3. D'Ugo DM, Persiani R, Caracciolo G, Ronconi P, Coco C, Picciocchi A. Selection of locally advanced gastric carcinoma by preoperative staging laparoscopy. *Surg Endosc* 1997; 11: 1159-62.
4. Ascencio F, Aguiló J, Salvador JL, et al. Video-laparoscopic staging of gastric cancer. A prospective multicenter comparison with noninvasive techniques. *Surg Endosc* 1997; 11: 1153-8.
5. Bruke EC, Karpeh MS, Conlon KC, Brennan MF. Laparoscopy in the management of gastric adenocarcinoma. *Ann Surg* 1997; 225: 262-7.
6. Lowy AM, Mansfield PF, Leach SD, Ajani J. Laparoscopic staging for gastric cancer. *Surgery* 1996; 119: 611-14.
7. Gastric Cancer Trends in Israel, 1996-2000. Israel Ministry of Health.
8. Lehnert T, Rudek B, Kienle P, Buhl K, Herfarth C. Impact of diagnostic laparoscopy on the management of gastric cancer: prospective study of 120

consecutive patients with primary gastric adenocarcinoma. *Br J Surg* 2002; 89: 471-5.

9. Osorio J, Rodríguez-Santiago J, Muñoz E, Camps J, Veloso E, Marco C. Outcome of unresected gastric cancer after laparoscopic diagnosis of peritoneal carcinomatosis. *Clin Transl Oncol* 2008; 10: 294-7.
10. Sarela AI, Miner TJ, Karpeh MS, Coit DG, Jaques DP, Brennan MF. Clinical outcomes with laparoscopic stage M1, unresected gastric adenocarcinoma. *Ann Surg* 2006; 243: 189-95.
11. Smith A, Finch MD, John TG, Garden OJ, Brown SP. Role of laparoscopic ultrasonography in the management of patients with oesophagogastric cancer. *Br J Surg* 1999; 86: 1083-7.
12. Feussner J, Omote K, Fink U, Walker SK, Siewert JR. Pretherapeutic laparoscopic staging in advanced gastric carcinoma. *Endoscopy* 1999; 31: 342-7.
13. Dassen AE, Lips DJ, Hoekstra CJ, Pruijt JF, Bosscha K. FDG-PET has no definite role in preoperative imaging in gastric cancer. *Eur J Surg Oncol* 2009; 35: 449-55.
14. Kwee RM, Kwee TC. Imaging in assessing lymph node status in gastric cancer. *Gastric Cancer* 2009; 12: 6-22.
15. Rabin I, Chikman B, Halpern Z, et al. Sentinel node mapping for gastric cancer. *IMAJ Isr Med Assoc J* 2006; 8: 40-3.