Comparative Efficacy Analysis of an Aspiration Device Before Primary Angioplasty in Patients with Acute Myocardial Infarction: A Single-Center Experience

Ariel Finkelstein MD[1]*, Shmuel Schwartzenberg MD[2]*, Limor Bar MD[1], Yehuda Levy MD[1], Amir Halkin MD[1], Itzhak Herz MD[1], Samuel Bazan MD[1], Rafael Massachi BSc, Shmuel Banai MD[1], Gad Keren MD[1] and Jacob George MD[2]

[1]Department of Cardiology, Tel Aviv Sourasky Medical Center, Tel Aviv, affiliated with Sackler Faculty of Medicine, Tel Aviv University, Ramat Aviv, Israel
[2]Department of Cardiology, Kaplan Medical Center, Rehovot, affiliated with Hebrew University-Hadassah Medical School, Jerusalem, Israel

ABSTRACT: **Background:** ST-elevation myocardial infarction is caused by occlusive coronary thrombosis where antecedent plaque disruption occurs. When treating STEMI the main goal is to achieve prompt reperfusion of the infarction area. Several studies have demonstrated the efficacy of an aspiration device before percutaneous coronary intervention in patients with acute myocardial infarction.

Objectives: To determine the added value of thrombus aspiration prior to primary PCI by comparing AMI patients with totally occluded infarct-related artery treated with routine primary PCI to those treated with extraction device prior to primary PCI.

Methods: The study group comprised 122 consecutive patients with AMI and a totally occluded infarct artery (TIMI flow 0) who underwent primary PCI. The patients were divided into two groups: 68 who underwent primary PCI only (control group) and 54 who underwent primary thrombus extraction with an extraction device before PCI (extraction group). Baseline clinical and lesion characteristics were similar in both groups. Final TIMI grade flow and myocardial blush as well as 1 year mortality, target lesion revascularization, recurrent myocardial infarction, unstable angina and stroke were compared between the two groups.

Results: Primary angiographic results were better for the extraction group versus the control group: final grade 3 TIMI flow was 100% vs. 95.6% ($P = 0.03$) and final grade 3 myocardial blush grade 50% vs. 41.18% (although P was not significant). Long-term follow-up total MACE showed a non-significant positive trend in the extraction group (12.96% vs. 24.71%, $P = 0.26$).

Conclusions: The use of extraction devices for intracoronary thrombectomy during primary PCI in patients with totally occluded infarct artery significantly improved epicardial reperfusion in the infarct-related vessel and showed a trend for more favorable long-term outcome.

IMAJ 2010; 12: 692–696

KEY WORDS: primary percutaneous intervention, thrombus aspiration, acute myocardial infqrction

Acute myocardial infarction is usually caused by rupture of a vulnerable plaque with a superimposed mural thrombus formation. This process, if not treated promptly, can lead to myocardial necrosis and heart failure. Percutaneous coronary intervention is the treatment of choice for AMI [1,2]. However, despite successful revascularization of the occluded epicardial coronary artery, PCI fails to achieve optimal TIMI-3 flow in 12% to 26% of cases, mainly because of the no-reflow phenomenon [3-5]. No reflow can be defined as inadequate myocardial perfusion through a given segment of the coronary circulation without angiographic evidence of mechanical vessel obstruction [6].

During PCI, mechanical debulking, through fragmentation, squeezing and pulverization, causes dislodgement and embolization of atherothrombotic debris composed of plaque and vessel wall constituents, including lipid, matrix, endothelial cells and platelet-rich thrombus. This process is thought to be responsible for the no-reflow phenomenon through microvascular obstruction caused by plugging by leukocytes, inflammation, edema and vasoconstriction [7]. Distal embolization and no-reflow are especially common in the setting of AMI; several recent studies have demonstrated retrieval of atheroembolic particles in up to 73% of the patients who underwent thrombo-aspiration [5,8] and no-reflow was evident in up to 26% of these patients [3-5].

The purpose of pre-PCI thrombus aspiration, performed with extraction devices, is to reduce the intraluminal thrombus burden before balloon inflation and stent implantation, as well as reduce the risk of myocardial damage due to distal embolization of blood clot fragments and other microparticles in order to improve reperfusion.

Several studies have compared PCI with and without pre-PCI thrombus aspiration to evaluate whether there is

***The first two authors contributed equally to the paper**

STEMI = ST-elevation myocardial infarction
PCI = percutaneous coronary intervention
AMI = acute myocardial infarction
MACE = major adverse cardiac event

an added value in using extraction devices [5, 8-17]. Most of these studies found improved myocardial perfusion and reduced no-reflow incidence with thrombus aspiration. The latest published meta-analysis demonstrated that among patients with AMI treated with PCI, the use of adjunctive manual thrombectomy devices is associated with better epicardial and myocardial perfusion, less distal embolization, and significant reduction in 30 day mortality [18].

These recent studies were performed on non-selected patients with AMI. As expected, initial total coronary obstruction was present in many but not all patients, such as 55% in the TAPAS study [5], 54.3% in the EXPIRA study [15] and 64% in the REMEDIA study [9]. The aim of the present study was to evaluate the impact of an extraction device in selected patients with AMI who present with complete occlusion (TIMI flow=0) of the infarct-related artery on diagnostic angiography, thus presumably bearing maximal thrombus burden and therefore subject to a more adverse prognosis.

PATIENTS AND METHODS

A prospective registry was compiled of 122 consecutive patients with ST-elevated MI and totally occluded infarct-related artery who were treated with primary PCI in our institution between January 2006 and December 2008. Sixty-eight of them underwent primary PCI only (control group) and 54 patients underwent thrombus extraction with an aspiration device before primary PCI (extraction group) at the discretion of the treating interventional cardiologist. Indications for primary PCI included chest pain lasting > 20 minutes, admission within < 12 hours of onset of pain, ST-segment elevation > 2 mV in at least two contiguous leads, and total occlusion of the infarct-related artery (TIMI flow 0). Baseline clinical characteristics of both groups were well matched [Table 1].

Table 1. Baseline clinical and myocardial infarction characteristics

Parameter	Subgroup	Extraction device (n=54)	Control group (n=68)	*P* value
Gender (% ± SD)	Female	n=12 (22.22%) ± 0.42	n=13 (19.12%) ± 0.40	0.67
	Male	n=42 (77.78%)	n=55 (80.88%)	0.67
Age (mean ± SD)		60.69 ± 13.57	60.79 ± 12.52	0.96
Diabetes (% ± SD)		n=10 (18.52%) ± 0.39	n=9 (13.24%) ± 0.34	0.42
Hypertension (% ± SD)		n=11 (20.37%) ± 0.41	n=16 (23.53%) ± 0.43	0.67
Hyperlipidemia (% ± SD)		n=28 (51.85%) ± 0.50	n=24 (35.29%) ± 0.48	0.06
Smoking (% ± SD)	Active smokers	n=19 (35.19%) ± 0.90	n=31 (45.59%) ± 0.94	0.4
	Formerly smoking	n=10 (18.52%)	n=8 (11.76%)	0.4
MI type (% ± SD)	Anterior	n=18 (33.33%) ± 1.45	n=22 (32.35%) ± 1.47	0.44
	Inferior	n=22 (40.72%)	n=28 (41.18%)	0.44
	Posterior	n=2 (3.70%)	n=0 (0%)	0.44
	Lateral	n=2 (3.70%)	n=6 (8.82%)	0.44
	Infero-posterior	n=10 (18.52%)	n=12 (17.65%)	0.44

PROCEDURE AND DEVICE DESCRIPTION

Thrombus aspiration in the "extraction group" was performed when obstructive thrombus was identified angiographically using one of two different extraction syringe devices: Pronto V3 extraction catheter (Vascular Solutions Inc., Minneapolis, MN, USA) and Export XT aspiration catheter (Medtronic Vascular Inc., Santa Rosa, CA). About two-thirds of the patients in both control and extraction groups received the glycoprotein IIb/IIIa inhibitor eptifibatide. Balloon pre-dilatation before stent deployment and intraaortic balloon insertion were performed at the discretion of the interventional cardiologist.

ANGIOGRAPHIC EVALUATION

Reperfusion (primary endpoint) assessment was based on the TIMI flow scoring system and on myocardial blush grade [19,20]. These reperfusion indices were visually estimated by three interventional cardiologists off-line. TIMI flow and MBG were measured before and after the procedure.

MEDICAL TREATMENT

All patients received aspirin (300 mg followed by 100 mg/day), heparin (5000 IU), and clopidogrel (loading dose of 300 or 600 mg followed by 75 mg/day). Unless contraindicated, patients received weight-adjusted glycoprotein IIb/IIIa-inhibitor (eptifibatide) during the procedure and additional heparin guided by activated clotting time. Standard therapies after PCI included beta-blockers, statins, and angiotensin-converting enzyme inhibitors. After hospital discharge, dual antiplatelet therapy was recommended for at least one month in patients who received a bare metal stent and for at least 6 months in patients who received a drug-eluting stent.

PROCEDURAL EVALUATION AND FOLLOW-UP

Short-term success was assessed by the following parameters: the need for pre-dilatation with balloon, the need for intraaortic balloon, final TIMI flow, and final myocardial blush grade.

Information on vital status, reinfarction, recurrent PCI, and cardiovascular accident was collected using hospital records, written questionnaires, and telephone interviews 1 year after the initial registry selection. One year MACE (secondary endpoint) included mortality, target lesion revascularization, recurrent MI, unstable angina and CVA. Recurrent MI was defined according to the European Society

MBG = myocardial blush grade
CVA = cardiovascular accident

of Cardiology/American College of Cardiology "Universal Definition of Myocardial Infarction" [21]. We did not distinguish between reinfarction in the index culprit artery territory and reinfarction in a different myocardial territory.

STATISTICAL ANALYSIS

Comparisons of variables between extraction and primary PCI were performed using chi-square for categorical variables, *t*-test for continuous variables and Mann-Whitney test for variables measured by ordinal scale. Kaplan-Meier survival analysis was performed to evaluate the survival function for each patient group separately for the following events: mortality, target lesion revascularization, repeated MI and repeated hospitalization. Comparison of survival function between both groups was performed by the Log Rank test. Statistical analysis was performed using SAS for Windows, version 9.1 software. Cumulative results as survival and adverse events were presented as Kaplan-Meier graphs. Quantitative data are expressed as mean ± SD, and a P value < 0.05 was considered significant.

RESULTS

A total of 122 patients with AMI and a totally occluded infarct-related artery (TIMI flow 0) who underwent primary PCI were enrolled in our registry. Fifty-four of them underwent thrombus extraction before PCI (extraction group) and 68 underwent conventional primary PCI (control group). As can be seen in Table 1, there were no significant differences in baseline clinical and angiographic characteristics between the two treatment groups.

Table 2. Short-term procedural characteristics and results

Parameter	Subgroup	Extraction device (n=54)	Control group (n=68)	*P* value
No. of vessel disease (% ± SD)	Single	n=24 (44.44%) ± 0.81	n=29 (42.65%) ± 0.73	0.41
	Double	n=17 (31.48%)	n=28 (41.18%)	
	Triple	n=13 (24.07%)	n=11 (16.18%)	
Treated vessels (% ± SD)	AMI in RCA	n=30 (55.50%) ± 1.52	n=37 (54.41%) ± 1.28	0.13
	LAD	n=17 (31.48%)	n=22 (32.35%)	
	LCx	n=2 (3.70%)	n=4 (5.88%)	
	Left main	n=1 (1.85%)	n=1 (1.47%)	
	PL/PDA	n=4 (7.41%)	n=4 (5.88%)	
GPIIbIIIa (% ± SD)		n=35 (64.81%) ± 0.48	n=47 (69.12%) ± 0.47	0.61
Thrombectomy device (% ± SD)	Pronto	n=37 (68.52%) ± 0.47		
	Export	n=17 (31.48%)		
Mean EF (Mean ± SD)		0.45 ± 0.1	0.44 ± 0.16	0.56
Peak CPK (Mean ± SD)		1623.7 ± 1533.88	1298.2 ± 947.3	0.17
Pre-dilatation (% ± SD)		n=29 (53.70%) ± 0.50	n=61 (89.71%) ± 0.30	
IABP insertion		n=2 (3.70%)	n=5 (7.35%)	

GP = glycoprotein, EF = ejection fraction, CPK = creatine phosphokinase, IABP = intraaortic balloon pump

SHORT-TERM ANGIOGRAPHIC RESULTS

There were no significant differences in the extent of coronary artery disease, the culprit artery treated and ejection fraction between the two treatment groups [Table 2]. The final TIMI flow grade 3 achieved [Figure 1A] was significantly better in the extraction group than in the control group, 100% vs. 95.6% ($P = 0.03$).

Myocardial blush was measured at the infarction zone [Figure 2B]. Final myocardial blush grade tended to be better in the extraction group, but this trend did not achieve statistical significance: final MBG was 2.39 ± 0.68 vs. 2.25 ± 0.74 (NS) and final MBG 3 score 50% vs. 41.2% (NS) in the extraction group and the control group, respectively.

Due to less favorable angiographic characteristics, balloon pre-dilatation and intraaortic balloon pump was used more

Figure 1. [A] Distribution of patients (in percentages) according to final TIMI flow score in the two patient groups. **[B]** Distribution of patients (in percentages) according to final myocardial blush grade (MBG) in the two patient groups.

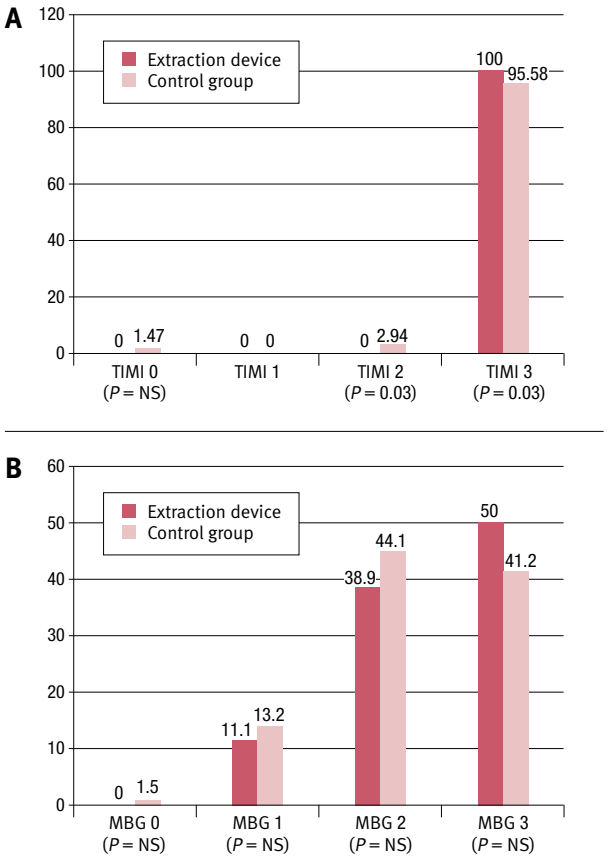

Figure 2. Distribution of patients (in percentages) according to total MACE and individual secondary endpoints- CVA, unstable angina pectoris, recurrent MI, target lesion revascularization (TLR) or death - in the two patient groups.

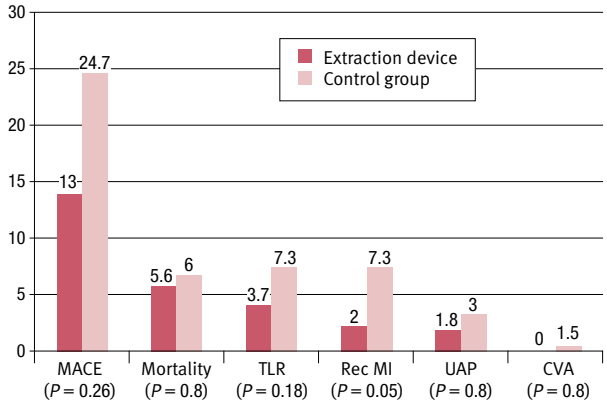

frequently after wire passage in the control group than in the extraction group (balloon pre-dilatation was used in 89.7% of cases in the control group vs. 53.7% of cases in the extraction group, $P < 0.0001$ and intraaortic balloon pump was used in 7.3% of cases in the control group vs. 3.7% of cases in the extraction group, $P < 0.0001$).

LONG-TERM RESULTS

A 12 month follow-up showed a trend for better outcome in the extraction compared to the control group in total MACE occurrence (24.71% vs. 12.96%, $P = 0.26$) [Figure 2]. The most prominent differences were in recurrent MI reoccurrence (1.85% vs. 7.35% respectively, $P < 0.05$) and in target lesion revascularization (3.70% vs.7.35%, P = NS). Mortality was similar in both groups (5.6% and 5.9%). CVA and acute coronary syndrome were relatively similar in both groups as well.

DISCUSSION

Primary PCI reduces cardiac mortality in acute MI and is currently the preferred treatment. Recent studies have shown that manual aspiration of the thrombus during primary PCI can prevent distal embolization, improve myocardial reperfusion and improve clinical outcome [8-17]. The purpose of our study was to determine the efficacy of thrombus extraction as adjunctive treatment before angioplasty for STEMI patients. Specifically, we pre-selected from our catheterization registry patients who had a totally occluded infarct-related coronary artery on the initial angiogram. Primary angioplasty was performed with or without preliminary thrombus extraction and we compared the short-term angiographic results and the long-term MACE.

We found significantly better angiographic results for patients with thrombus aspiration evidenced by an improved final TIMI flow count, a trend for better MBG, and reduced need for further mechanical interventions (balloon pre-dilatation and intraaortic balloon usage). Thus, it appears that effective removal of thrombotic material at the lesion site improves myocardial reperfusion by reducing distal embolization occurring during plaque manipulation with balloon and stent. Presumably, due to the relatively small number of patients and small number of secondary events, these better shorter term results did not translate into a statistically significant reduction in MACE, although a positive trend was evident. Other studies have also found significantly improved short-term angiographic results in STEMI patients treated with thrombus aspiration devices without resulting in improved long-term clinical outcomes [5,13,14].

The principal limitations of our study were the relatively small number of patients and the fact that it was based on retrospective analysis in a single center. Procedural success was not correlated with several accepted adjunctive modalities such as procedural intravascular ultrasound or ST-segment resolution and echocardiography, and magnetic resonance imaging at follow-up, which could have enhanced the strength of our findings. Also, this study was not powered and designed to test differences in clinical outcome. Although the population of MI patients in our study was limited to patients with a totally occluded infarct-related artery, others found similar results in non-selected patients undergoing thrombus extraction in primary PCI. It is likely that in our study thrombus load was larger than reported in previous studies as totally occluded infarct artery was a requirement for enrollment. Although one might suspect that a larger thrombus load would enhance the potential efficacy of thrombus aspiration, this could also be detrimental due to the distal embolization of larger plaque material by the forward advancement of the aspiration catheter that could reduce angiographic success. Indeed, in the AIMI study, use of the AngioJet™ device increased infarct size, possibly via distal embolization [22]. Our results clearly suggest that the benefit of thrombus removal is maintained also in acute MI patients with a totally occluded infarction vessel.

In conclusion, our study supports the validity of findings by other groups showing a beneficial effect of thrombus aspiration in primary PCI in patients with acute MI before stent deployment.

Corresponding author:
Dr. J. George
Dept. of Cardiology, Kaplan Medical Center, Rehovot 73100, Israel
email: jgeorge@bezeqint.net

References

1. Keeley EC, Boura JA, Grines CL. Primary angioplasty versus intravenous thrombolytic therapy for acute myocardial infarction: a quantitative review of 23 randomised trials. *Lancet* 2003; 361: 13-20.

2. Boersma E. Does time matter? A pooled analysis of randomized clinical trials comparing primary percutaneous coronary intervention and in-hospital fibrinolysis in acute myocardial infarction patients. *Eur Heart J* 2006; 27: 779-88.

3. Piana RN, Paik GY, Moscucci M, et al. Incidence and treatment of 'no-reflow' after percutaneous coronary intervention. *Circulation* 1994; 89(6): 2514-18.

4. Morishima I, Sone T, Mokuno S, et al. Clinical significance of no-reflow phenomenon observed on angiography after successful treatment of acute myocardial infarction with percutaneous transluminal coronary angioplasty. *Am Heart J* 1995; 130(2): 239-43.

5. Svilaas T, Vlaar PJ, van der Horst IC, et al. Thrombus aspiration during primary percutaneous coronary intervention. *N Engl J Med* 2008; 358(6): 557-67.

6. Eeckhout E, Kern MJ. The coronary no-reflow phenomenon: a review of mechanisms and therapies. *Eur Heart J* 2001; 22(9): 729-39.

7. Jaffe R, Charron T, Puley G, et al. Microvascular obstruction and the no-reflow phenomenon after percutaneous coronary intervention. *Circulation* 2008; 117: 3152-6.

8. Gick M, Jander N, Bestehorn HP, et al. Randomized evaluation of the effects of filter-based distal protection on myocardial perfusion and infarct size after primary percutaneous catheter intervention in myocardial infarction with and without ST-segment elevation. *Circulation* 2005; 112: 1462-9.

9. Burzotta F, Trani C, Romagnoli E, et al. Manual thrombus-aspiration improves myocardial reperfusion: the randomized evaluation of the effect of mechanical reduction of distal embolization by thrombus-aspiration in primary and rescue angioplasty (REMEDIA) trial. *J Am Coll Cardiol* 2005; 46: 371-6.

10. Beaudoin J, Dery JP, Lachance P, et al. Impact of thrombus aspiration on angiographic and clinical outcomes in patients with ST-elevation myocardial infarction. *Cardiovasc Revasc Med* 2010; 11(4): 218-22.

11. Silva-Orrego P, Colombo P, Bigi R, et al. Thrombus aspiration before primary angioplasty improves myocardial reperfusion in acute myocardial infarction: the DEAR-MI (Dethrombosis to Enhance Acute Reperfusion in Myocardial Infarction) study. *J Am Coll Cardiol* 2006; 48: 1552-9.

12. Ikari Y, Kawano S, Sakurada M, et al. Upfront thrombus aspiration in primary coronary intervention for patients with ST-segment elevation acute myocardial infarction: report of the VAMPIRE (VAcuuM asPIration thrombus REmoval) trial. *JACC Cardiovasc Interv* 2008; 1(4): 424-31.

13. De Luca L, Sardella G, Davidson CJ, et al. Impact of intracoronary aspiration thrombectomy during primary angioplasty on left ventricular remodeling in patients with anterior ST-elevation myocardial infarction. *Heart* 2006; 92: 951-7.

14. Chevalier B, Gilard M, Lang I, et al. Systematic primary aspiration in acute myocardial percutaneous intervention: a multicenter randomised controlled trial of the export aspiration catheter. *EuroInterv* 2008; 4: 1-7.

15. Sardella G, Mancone M, Bucciarelli-Ducci C, et al. Thrombus aspiration during primary percutaneous coronary intervention improves myocardial reperfusion and reduces infarct size: the EXPIRA (thrombectomy with export catheter in infarct-related artery during primary percutaneous coronary intervention) prospective, randomized trial. *J Am Coll Cardiol* 2009; 53(4): 309-15.

16. Segev A, Elian D, Marai I, et al. Thrombus aspiration during primary percutaneous coronary intervention in acute ST-elevation myocardial infarction. *Cardiovasc Revasc Med* 2008; 9(3): 140-3.

17. Vlaar PJ, Svilaas T, van der Horst IC, et al. Cardiac death and reinfarction after 1 year in the Thrombus Aspiration during Percutaneous coronary intervention in Acute myocardial infarction Study (TAPAS): a 1-year follow-up study. *Lancet* 2008; 371(9628): 1915-20.

18. De Luca G, Dudek D, Sardella G, Marino P, Chevalier B, Zijlstra F. Adjunctive manual thrombectomy improves myocardial perfusion and mortality in patients undergoing primary percutaneous coronary intervention for ST-elevation myocardial infarction: a meta-analysis of randomized trials. *Eur Heart J* 2008; 29(24): 3002-10.

19. TIMI Study Group. The Thrombolysis in Myocardial Infarction (TIMI) trial. *N Engl J Med* 1985; 31: 932-6.

20. Gibson CM, Cannon CP, Murphy SA, et al. Relationship of TIMI myocardial perfusion grade to mortality after administration of thrombolytic drugs. *Circulation* 2000; 101: 125-30.

21. Thygesen K, Alpert JS, White HD, et al. Universal definition of myocardial infarction. *Circulation* 2007; 116(22): 2634-53.

22. Alli A, Cox D, Dib N, et al; AIMI Investigators. Rheolytic thrombectomy with percutaneous coronary intervention for infarct size reduction in acute myocardial infarction: 30-day results from a multicenter randomized study. *J Am Coll Cardiol* 2006; 48(2): 244-52.